

Reimplantation of two incisors avulsed by trauma. A 10-year follow-up

Antonio Henrique **BRAITT**¹

Maria Adelaide Bastos Bacelar **COSTA**²

Ernani da Costa **ABAD**³

Evaldo Almeida **RODRIGUES**⁴

Carlos Eduardo da Silveira **BUENO**⁵

ABSTRACT

Introduction: Approximately 50% of young people younger than 15 years old are victims of some type of traumatic injury in the orofacial region. Dentoalveolar traumas are among the biggest problems described in the dental literature. The indexes of violence in modern society, traffic accidents and extreme sports contribute to this type of injury. These traumatic episodes occurring in childhood or adolescence may lead to major issues such as psychosomatic disorders in patients, parents or guardians. **Objective:** To report the clinical history of a 9-year-old patient who sought dental service due to trauma caused to teeth #21 and 22 at hhr home. **Methods:** The patient was examined and subjected to periapical radiograph, confirming the avulsions. After anesthesia, the area was cleaned with saline solution and the alveolar

clots removed. A gauze humidened in saline was used. Teeth were reimplanted and splint with polyester strips attached with light-curing resin removed after 30 days. Endodontic treatment was conducted with change of calcium hydroxide for 90 days, after which the channels were closed. **Results:** The patient was clinically and radiographically monitored for 10 years with follow-up radiographs showing the teeth in the alveoli without root resorption. **Conclusion:** Dental reimplantation is an alternative treatment that should be done whenever possible, even if the prognosis is bad due to the time between the accident and treatment onset.

Keywords: Tooth avulsion. Endodontics. Traumatology.

How to cite this article: Braitt AH, Costa MABB, Abad EC, Rodrigues EA, Bueno CES. Reimplantation of two incisors avulsed by trauma. A 10-year follow-up. *Dental Press Endod.* 2014 Jan-Apr;4(1):67-70. doi: <http://dx.doi.org/10.14436/2178-3713.V4.N1.067-070.oar>.

¹MSc in Endodontics, School of Dentistry — São Leopoldo Mandic. Professor, Specialization program in Endodontics, FUNORTE.

²Degree in Dentistry, State University of Feira de Santana.

³PhD in Endodontics, Federal University of Rio de Janeiro (UFRJ). Adjunct professor, Estácio de Sá University.

⁴MSc in Endodontics, Federal University of Bahia (UFBA). Professor, Specialization program in Endodontics, FUNORTE.

⁵Postdoc in Endodontics, State University of Campinas (UNICAMP). Full Professor, School of Dentistry — São Leopoldo Mandic.

» Patients displayed in this article previously approved the use of their facial and intraoral photographs.

» The authors report no commercial, proprietary or financial interest in the products or companies described in this article.

Submitted: December 15, 2013. Revised and accepted: December 19, 2013.

Contact address: Antonio Henrique Braitt
Av. Aziz Aron, 1117, Sala 703 – Jardim União – Itabuna/BA — Brazil
CEP: 45.605-415 – E-mail: henrique_braitt@hotmail.com

Introduction

Approximately 50% of young people younger than 15 years old are victims of some kind of traumatic injury in the orofacial region. Dentoalveolar trauma, as well as tooth decay and oral cancer, are among the major problems described in the dental literature worldwide. The levels of violence in modern society, traffic accidents and sports contribute to this kind of injury.¹¹ These traumatic episodes occurring in childhood or adolescence can lead to major issues and psychosomatic disorders in patients, parents or guardians.²

In studies conducted by Raphael and Gregory,⁹ the degree of awareness of a lay person regarding tooth avulsion was analyzed. The authors found that 33% of parents were unaware of how to behave in a case of avulsion. A total of 90% said they had never received any instruction on how to store an avulsed tooth. Their study concluded that a higher number of better educational campaigns are necessary to inform the population about prevention means and procedures in case of injury. Successful reimplantation depends not only on appropriate first aid procedures, but also on correct treatment in the dental clinics afterwards.

Among the various types of traumatic injuries, tooth avulsion figures as one of the most prevalent. It corresponds to the forcible separation or detachment of a tooth from its socket due to an accidental or surgical procedure.^{3,13} Prognosis depends on the stage of root development; tooth storage time, whether wet or dry; and proper storage, handling and retention of the avulsed tooth. The tooth should be rinsed in clean water and reimplanted. Subsequently, a semi-rigid retention should be kept for 7 to 10 days. If reimplantation is not immediately possible, the tooth should be stored in Hank's solution, milk or saline solution.⁷ Successful prognosis is related to the time the tooth was left out of the alveolus and the environment where it was stored. Prognosis worsens after the first hour, for this reason, it is always best that reimplantation occur between 15 and 30 minutes after avulsion due to failure of periodontal fibers attached to the cement and of those in the alveolar wall.^{6,12}

The protocol for diagnosis and treatment of avulsed teeth recommends the following:^{1,6,7} The affected area should be examined for potential sequelae in soft tissues; CT scan and X-ray should be carried out to check potential bone fractures or damage to adjacent teeth. The area should be anesthetized, cleaned with water,

saline solution or chlorhexidine. All necessary sutures should be made in soft tissues. The socket should be slightly and carefully cleaned with gauze and saline solution so as to remove the clot. The tooth should be held by the crown, washed in saline solution and repositioned in the socket in its original position and splinted with a semi-rigid material that should be kept for about two weeks.⁸ Painkillers, antibiotics and tetanus vaccine should be prescribed to the patient, together with daily mouthwash with 1% chlorhexidine. After removing the splints, pulp vitality test should be conducted with cold (Endo Ice) and hot (gutta-percha) material. Should this test yield negative results, which may occur in most cases, endodontic treatment is indicated. It should be performed within two to three sessions using calcium hydroxide as intra-canal dressing at intervals of 30 days before endodontic filling. Treatment should be monitored every six months for a minimum period of two years, by radiography and tomography.¹⁰

The consequences of dental trauma with tooth avulsed from its socket comprise crown darkening, mobility, pulp necrosis and root resorption.⁵ Being the latter the most probable.

Case report

A 9-year-old female patient attended the clinic at around 21:00 pm on 16th of October, 2000 accompanied by her parents. They sought dental service due to trauma caused to patient's teeth #21 and 22 at her home. The patient was examined and a periapical radiography was performed, thereby confirming teeth avulsion (Fig 1). As the avulsed teeth had not been brought with them, it was necessary to go back to their house to pick them up. Teeth were placed in a container with saline solution and brought to the clinic. Meanwhile, the patient was anesthetized, the area was cleaned with saline solution and clots were removed from the alveoli which were kept humid with a gauze humidened in saline. Teeth were reimplanted and Splinter strips were bonded with self-curing polyester resin nearly two hours after the accident. The Splinter strips were removed after 30 days. Painkillers, amoxicillin and tetanus vaccine were prescribed.

On the 28th of October, 2000 endodontic treatment began. Cleaning and shaping of root canals were performed with 0.04 ProFile rotary system to their working length with #70 files and irrigated with sodium hypochlorite 2.5% (Fig 2). Calcium hydroxide was placed in

association with polyethylene glycol vehicle for 30 days. After this period, calcium hydroxide was removed with 17% EDTA in passive ultrasonic irrigation, final irrigation with 2.5% sodium hypochlorite, drying and replacement of calcium hydroxide. Two other sessions were performed, one after 30 days and another on the 21st of February, 2001 during which canals were filled with thermoplasticized gutta-percha and cement (Fig 3). The patient was clinically monitored with x-rays taken every

two months for 10 years. On the 28th of September, 2010 the radiographies revealed teeth placed in the alveoli without root resorption.

Discussion

Since reimplantation of avulsed teeth is widely studied, the literature has already reached a consensus regarding the best treatment methods and the main shortcomings and difficulties. Moreover, it is common

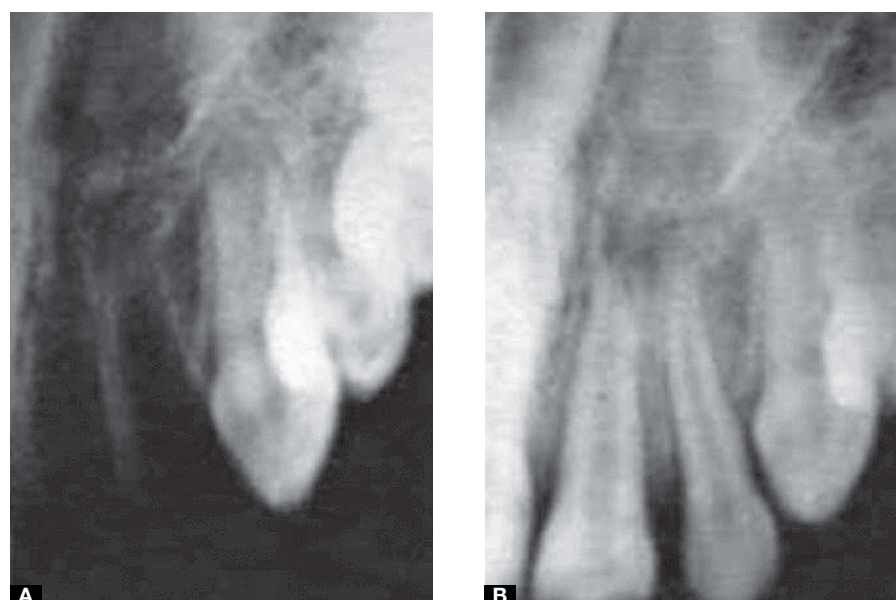


Figure 1. Alveolar socket without teeth (A) and with reimplanted teeth (B).

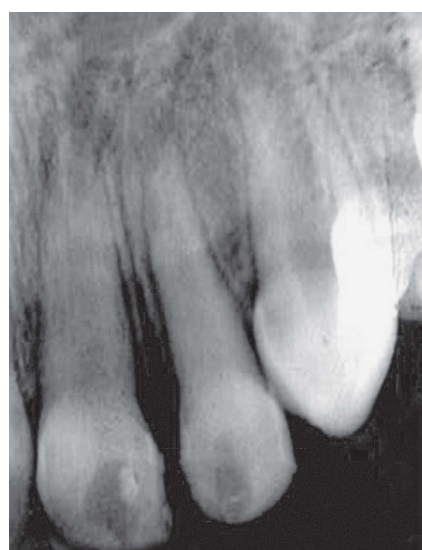

Figure 2. First endodontic treatment session. Calcium hydroxide used as intra-canal dressing.

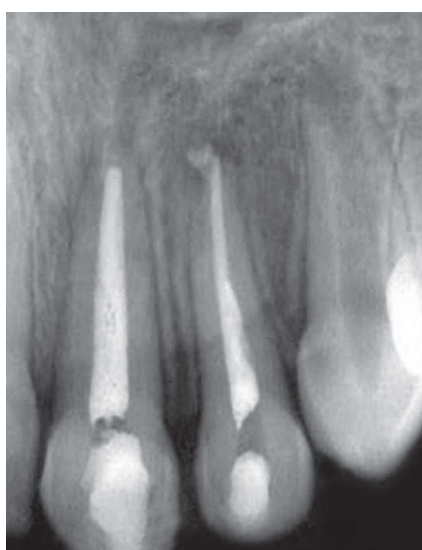

Figure 3. Filled root canal.

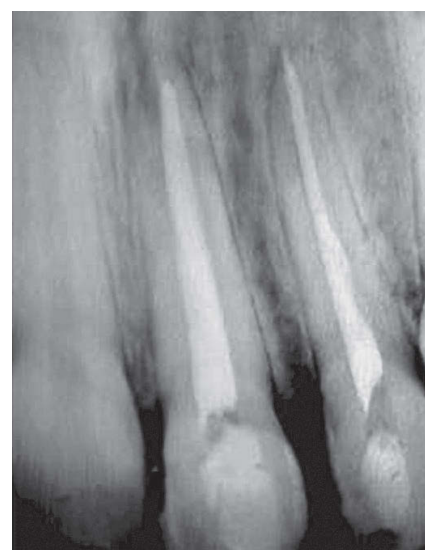

Figure 4. 10-year follow-up.

to find some differences in treatment approach, mainly throughout history and in the evolution of treatments.⁴ For this reason, additional research should be developed in order to retrieve an even greater number of case reports and elucidate this topic.

Prognosis depends on the time the tooth was left out of the alveolus as well as on proper manipulation of the avulsed tooth. With a view to yielding good results, it is essential that the tooth remains out of the alveolus the shortest possible time and that it be stored in a humid environment without contamination. When reimplantation is performed within the first 15 to 30 minutes after avulsion, the percentage of success is very high; however periods longer than 2 hours usually result in extensive root resorption due to necrosis of the periodontal ligament and the dental element, as well as contamination of trauma on the root surface.¹²

The following were of paramount importance to achieve treatment success of the case reported herein: patient's prompt availability; storage of teeth in a humid

environment; procedures that prevented alveolar cavities from drying out; and proper endodontic treatment.

Conclusion

This literature review⁴ and case report led us to conclude that:

- Dental reimplantation is an alternative treatment that should be performed whenever possible;
- Treatment will have a better prognosis when reimplantation is performed within 15 and 30 minutes after avulsion;
- Should immediate reimplantation be impossible, the avulsed tooth should be kept in a humid environment. The best storage solution is Hank's solution, followed by milk or saline solution;
- Calcium hydroxide proved to be the best intra-canal dressing used in the attempt to delay or prevent cementum and root dentin resorption of reimplanted teeth;
- Campaigns to inform and raise awareness regarding teeth avulsion prove to be effective, but are not widely spread.

References

1. Flores MT, Anderson L, Andreasen JO, Bakland LK, Malmgren B, Barnett F, et al. Guidelines for the management of traumatic dental injuries. II. Avulsion of permanent teeth. *Dent Traumatol.* 2007;23(3):130-6.
2. Mathias MF, Lobo-Piller RG, Queiroz CC, Bastos Neto F, Duarte MT, Boucault CHM, Prokopowitsch I. Multiple traumatic injury in mixed dentition: Case report. *Braz J Dent Traumatol.* 2010;2(1):1-6.
3. Menezes MM, Yui KCK, Araújo MAM, Valera MC. Prevalência de traumatismos maxilo-faciais e dentais em pacientes atendidos no Pronto-Socorro Municipal de São José dos Campos/SP. *Rev Odonto Ciênc.* 2007;22(57):210-6.
4. Miranda ACE, Habitante SM, Candelária LFA. Revisão de determinados fatores que influenciam no sucesso do reimplante dental. *Rev Biociênc.* 2000;6(1):35-9.
5. Miranda RB, Alves MFVM, Souza MR, Fidel SR, Fidel RAS. A multidisciplinary treatment of a dental trauma. *Braz J Dent Traumatol.* 2010;2(1):17-20.
6. Moule AJ, Moule CA. The endodontic management of traumatized permanent anterior teeth: a review. *Aust Dent J Suppl.* 2007;52(1):122-37.
7. Oliveira FAM, Oliveira MG, Orso VA, Oliveira VR. Traumatismo dentoalveolar: Revisão de literatura. *Rev Cir Traumatol Buco-Maxilo-Fac.* 2004;4(1):15-21.
8. Öz GY, Ataoğlu NK, Karaman AI. An alternative method for splinting of traumatized teeth: case reports. *Dent Traumatol.* 2006;22(6):345-9.
9. Raphael SL, Gregory PJ. Parental awareness of the emergency management of avulsed teeth in children. *Aust Dent J.* 1990;35:130-3.
10. Soares AJ, Gomes BPFA, Zaia AA, Ferraz CCR, Souza-Filho FJ. Relationship between clinical-radiographic evaluation and outcome of teeth replantation. *Dent Traumatol.* 2008;24(2):183-8.
11. Tannure PN, Fidalgo TKS, Antunes LAA, Maia LC. Clinical and radiographic follow-up of avulsed primary and permanent teeth. *Braz J Dent Traumatol.* 2010;2(1):7-12.
12. Uchoa AKM, Lins CCSA, Travassos RMC. Presença de reabsorção radicular externa após reimplante dental: relato de caso. *Rev Cir Traumatol Buco-Maxilo-Fac.* 2009;9(4):49-54.
13. Vasconcelos BCE, Fernandes BC, Aguiar ERB. Reimplante dental. *Rev Cir Traumatol Buco-Maxilo-Fac.* 2001;1(2):45-51.