

# Restorative perspective for endodontically treated teeth: Anatomic post

Maria Geovânia **FERREIRA**<sup>1</sup>

Myrane Cruvinel Nascimento **CAMAPUM**<sup>2</sup>

Guido Cirilo **FERREIRA**<sup>1</sup>

Marcus Vinícius **PERILLO**<sup>1</sup>

Paula de Carvalho **CARDOSO**<sup>3</sup>

Julio Almeida **SILVA**<sup>4</sup>

## ABSTRACT

**Introduction:** Individualized anatomic posts favor adaptation of prefabricated posts to root canal walls and reduce resin cement thickness. **Objective:** The aim of this study was to report a case of reconstruction of previously endodontically treated teeth by means of an individualized anatomic post. **Methods:** Replacement of endodontically treated central incisor restorations and previous deficient restorations was reported. Initially, deficient resin composites and the individual cast post of tooth #11 were removed. Root canal was endodontically retreated. The amount of residual dentine walls of the

root canal were low after removing the endodontic post. Treatment plan included the use of an anatomic post for tooth #11. Composite resin was applied after anatomic post placement. Root canal was shaped by a glass fiber post and composite resin. Subsequently, crown restoration was completed with composite resin. **Conclusion:** The technique used to manufacture direct anatomic posts seem to be a good alternative treatment for restoring wide root canals.

**Keywords:** Nonvital teeth. Posts. Cores. Dental esthetics.

**How to cite this article:** Ferreira MG, Camapum MCN, Ferreira GC, Perillo MV, Cardoso PC, Silva JA. Restorative perspective for endodontically treated teeth: Anatomic post. *Dental Press Endod.* 2014 Jan-Apr;4(1):34-45. doi: <http://dx.doi.org/10.14436/2178-3713.V4.N1.034-045.oar>.

<sup>1</sup>Professor, Postgraduate program in Cosmetic Dentistry, Brazilian Dental Association (ABO) – Goiás.

<sup>2</sup>Undergraduate student, Postgraduate program in Cosmetic Dentistry, Brazilian Dental Association (ABO) – Goiás.

<sup>3</sup>PhD in Cosmetic Dentistry, Federal University of Santa Catarina (UFSC). Professor, Postgraduate program in Cosmetic Dentistry, Brazilian Dental Association (ABO) – Goiás.

<sup>4</sup>Phd in Health Sciences, Federal University of Goiás (UFG).

» Patients displayed in this article previously approved the use of their facial and intraoral photographs.

» The authors report no commercial, proprietary or financial interest in the products or companies described in this article.

Submitted: November 02, 2013. Revised and accepted: November 07, 2013.

Contact address: Julio Almeida Silva  
Avenida Portugal, 138 – Apt. 701 – Ed. Antares – Setor Oeste  
Goiânia/GO – Brazil – CEP: 74.140-020  
E-mail: [juliojas@gmail.com](mailto:juliojas@gmail.com)

## Introduction

Endodontically treated teeth often have little coronal tissue remaining and as such require a post to retain core and restoration.<sup>1</sup> It is a common belief that the likelihood of survival of a pulpless tooth is directly related to the quantity and quality of remaining tooth structure. For many years, the idea of using a post for restoration of endodontically treated teeth was based upon the philosophy that the post would “reinforce” the tooth, and that additional retention was needed for core restoration. A post was generally placed in the attempt to strengthen the tooth. However, as dentin has to be sacrificed, especially when a metal post is used, a post does not strengthen the root, but serves solely to improve retention of the core.<sup>2-6</sup>

The amount of remaining tooth structure necessary to warrant post insertion, or a decision to use other methods is not clearly defined.<sup>1</sup> In cases of teeth with a high degree of destruction where no cavity wall remains, inserting a post proves necessary to provide core material retention.

The cavity wall must be at least 1-mm thick to ensure resistance to functional loads of the crown-root complex. Hard tissue thicknesses below 1 mm cannot be subjected to crown preparation without loss of all remaining substances. Thickness greater than 1 mm provides sufficient amount of hard tissue to stabilize the core material even after crown preparation. Therefore, cavity wall less than 1mm thick cannot be taken into consideration.<sup>4</sup>

Additionally, the ferrule effect also influences resistance to fracture, especially in decoronated teeth. The cavity wall must be at least 2 mm to provide sufficient ferrule effect.<sup>4,5,6</sup> Isidor et al<sup>6</sup> assert that selection of post length depends on many criteria. It has been proved that post length is less important for fracture resistance than the ferrule effect. Adhesive fixation is preferable, as it produces higher fracture resistance in comparison to cemented post and cores, in addition to offering higher fracture resistance.<sup>1</sup>

Duret et al<sup>7</sup> described a non-metallic material for the fabrication of posts based on the carbon-fiber reinforcement principle. Laboratory-based studies have shown that these posts have high tensile strength<sup>8</sup> and modulus of elasticity similar to dentine. Previously, rigid metal posts resisted lateral

forces without distortion and this resulted in stress transfer to the less rigid dentine, thereby causing potential root cracking and fracture. It is thought that fiber-posts flex under load and as a result distribute stresses between the post and the dentine.

Recent articles support the use of fiber posts to restore endodontically treated teeth.<sup>9,10,11</sup> Fiber-reinforced posts have demonstrated the ability to fracture at the coronal portion of a tooth restoration with the presence of catastrophic forces without fear of root fracture.<sup>12</sup> This may be the single most compelling reason for their use.

However, the mismatch between fiber post and post space diameters remains a clinical challenge.<sup>13</sup> Although the use of size-matched drills supplied by post manufacturers permits good fitting of posts to the canal walls, some canals have an elliptical shape in cross-section while posts have a circular shape.<sup>14</sup>

In some cases, if the post does not fit well, especially at the coronal level, the resin cement layer is excessively thick, and bubbles are likely to form, thus predisposing it to debonding.<sup>15</sup> The solution to overcome this problem is to reline the fiber post with composite resin.<sup>16</sup> This individual anatomic post favors the adaptation of the post to root walls and reduces resin cement thickness.<sup>15</sup>

The procedure of “individualizing” the post through resin layer, although advisable in all cases, appears to be particularly effective to improve post retention when dealing with canals of elliptic shape, or exhibiting a reduced amount of residual root structure after endodontic treatment. This latter situation obviously contraindicates further removal of dentin to make the canal shape match the post shape.<sup>17,18</sup> The creation of an anatomic post, i.e., shaping the post to root anatomy instead of vice versa, is the procedure of choice in these clinical situations of which the described case is an example.

The aim of this study was report a case of reconstruction of endodontically treated teeth by using posts and cores based on a literature review.

## Case report

In 2013, a 13-year-old patient fell down while playing at school. Trauma led to a complicated crown fracture with extensive pulp exposure on tooth #11 and enamel-dentin fracture without pulp exposure on tooth #21.

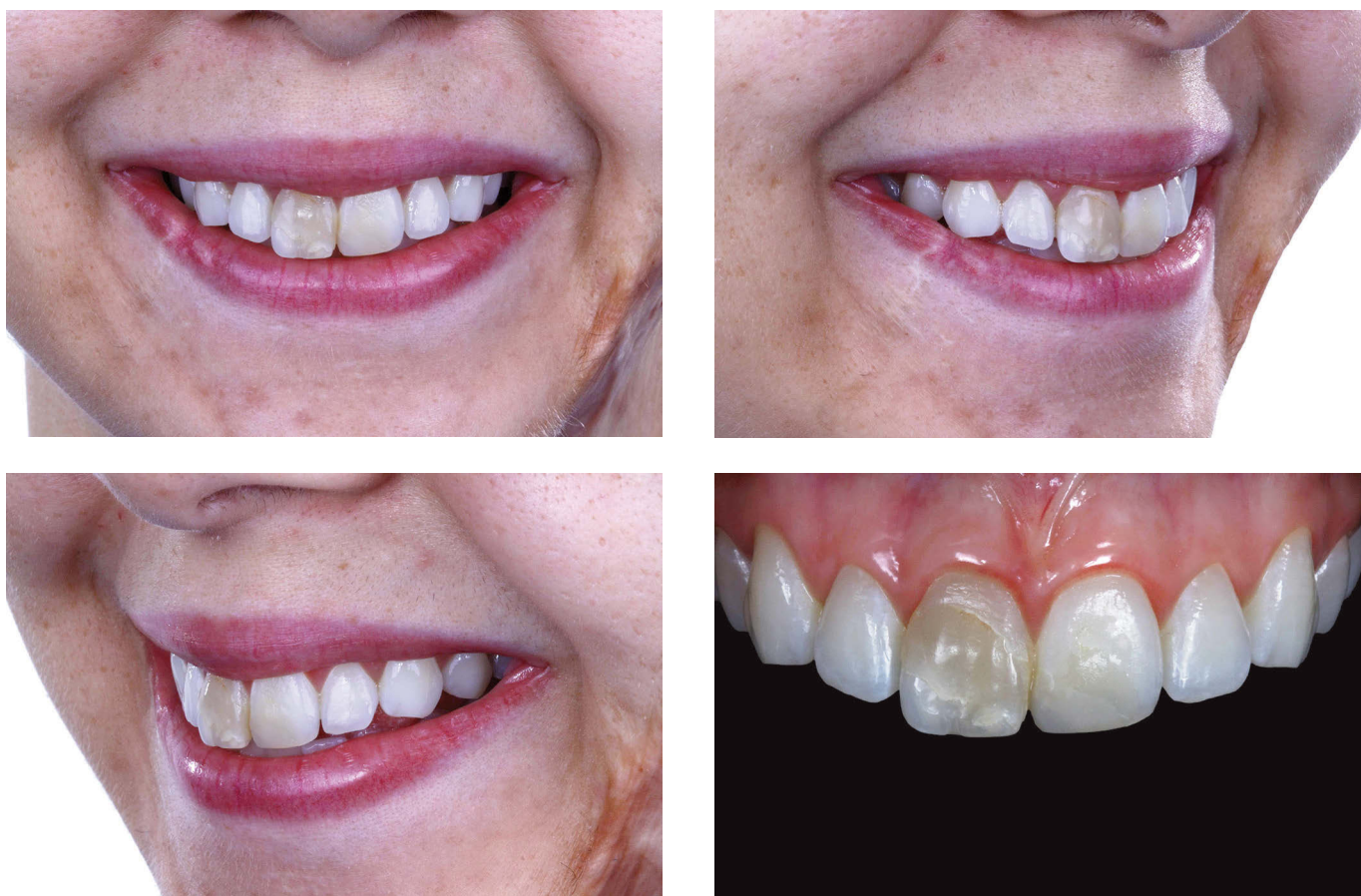On that occasion, endodontic treatment was performed followed by post placement on tooth #11. Tooth #21 was restored with composite resin (Fig 1).

Six years later, clinical and radiographic examination revealed deficient endodontic treatment. Additionally, the direct composite restorations on tooth #11 and #21 were found stained. Radiographic examination showed the presence of inadequate root canal filling and a short individual post (with the presence of a suggestive image of empty space between the post and the root canal walls, which impairs adhesion and favors coronal leakage and darkening of the tooth) (Fig 2). The clinician decided to endodontically retreat teeth #11 and to restore #11 and #21 with composite resin until prosthetic treatment could be performed.

Initially, deficient resin composites (Fig 3) and the individual cast post were removed from the root canal of tooth #11 by means of a spherical diamond tip #1011HL

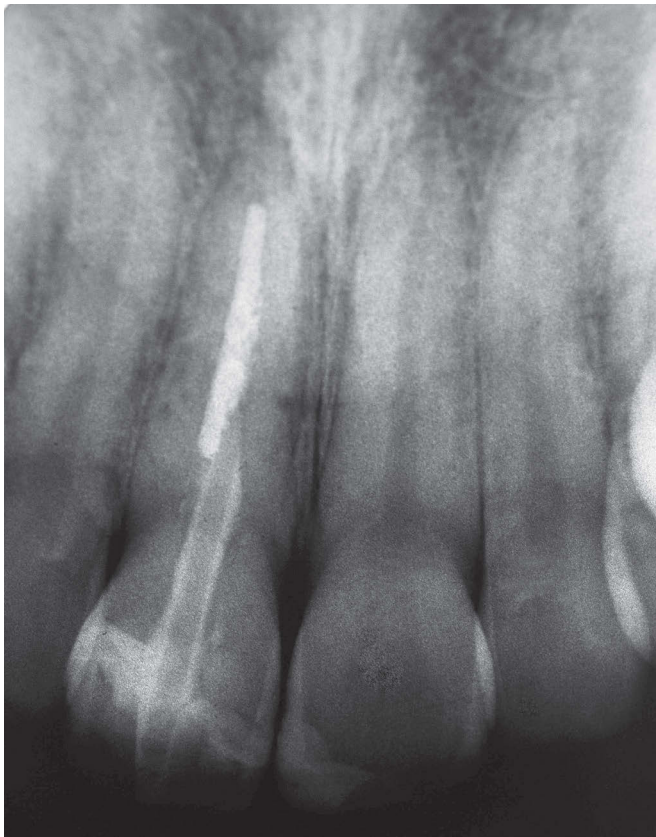(KG Sorensen, Brazil) and ultrasonic inserts (EN3, Gnatus, Brazil) (Fig 4). Figure 4 shows the cast post removed. Subsequently, the root canal was endodontically retreated. After post removal and endodontic retreatment, root canal anatomy did not allow the prefabricated post to satisfactorily adapt. The amount of residual dentin on the canal walls was so little that further tissue removal to make the canal shape adapt to that of the post was contraindicated. For this reason, the clinician decided to use an anatomic post for tooth #11 – that is, shaping a pre-fabricated fiber post with composite resin according to the dimensions of the root canal.

The first steps of retreatment were preparation of the coronal third and the middle/apical third of the root canal. Gates-Glidden drills, K-files and Hedstroen-files (Dentsply/Maillefer, Switzerland) were used to remove root canal filling (Fig 5). During operation, debris were periodically removed through constant irrigation with 1% sodium hypochlorite.

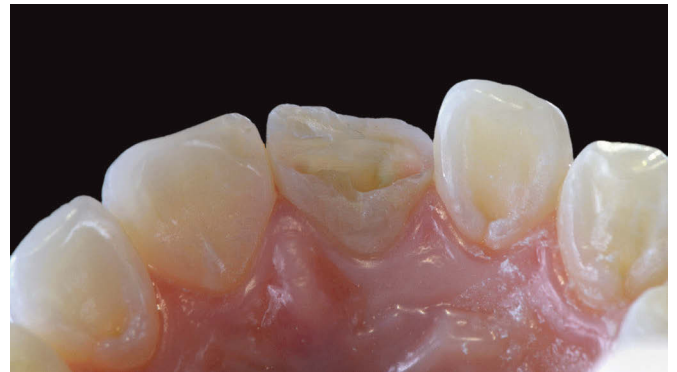
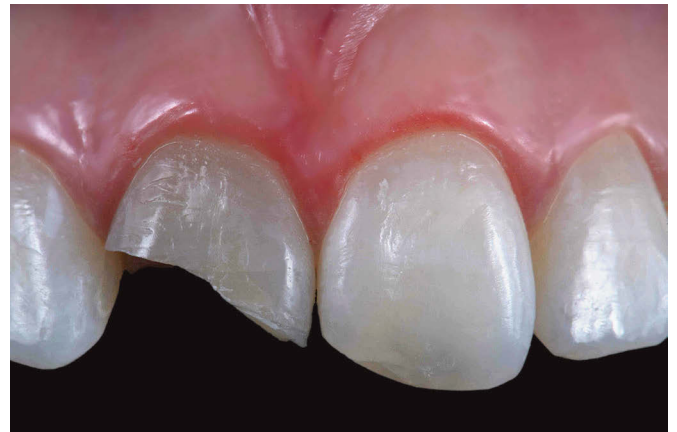
**Figure 1.** Preoperative smile photograph shows deficient and stained direct composite restoration in the maxillary left central incisor.

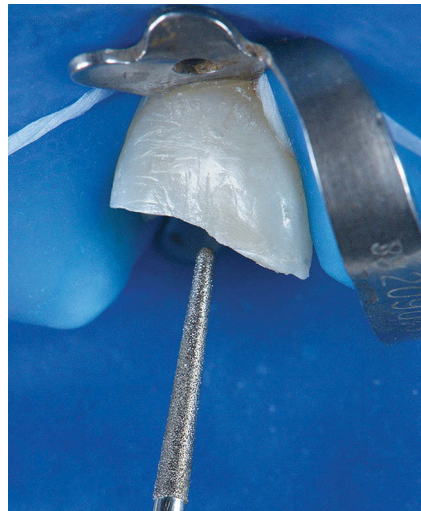
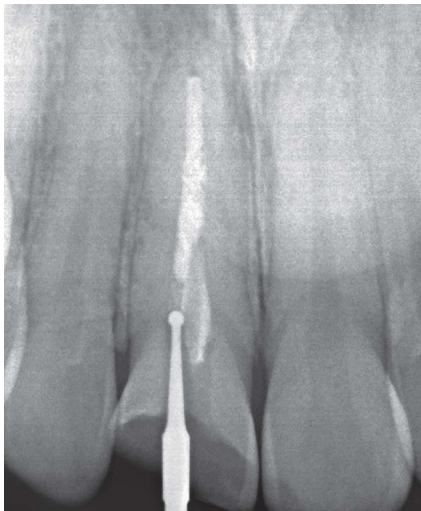




**Figure 2.** Periapical radiograph shows inadequate root canal filling and a short individual post. The core demanded further prosthetic restorations.



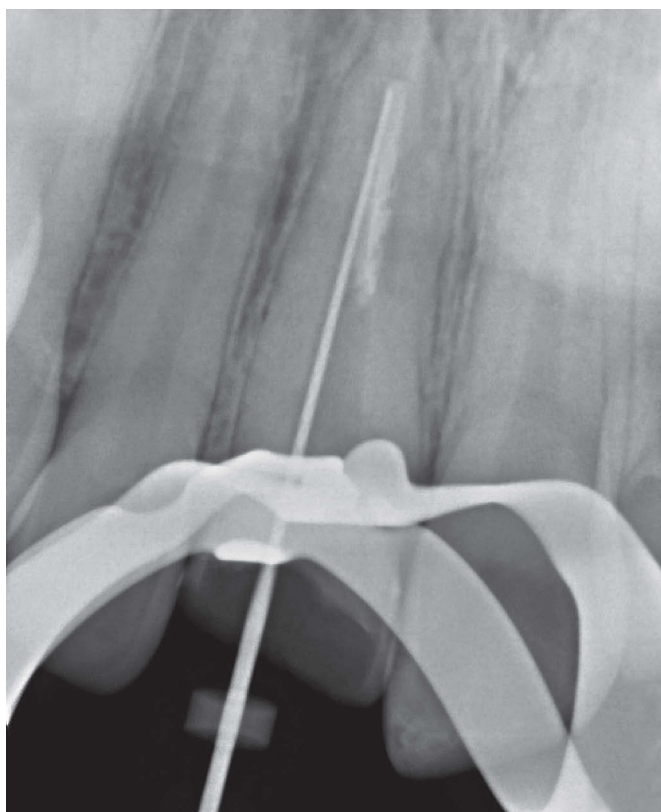
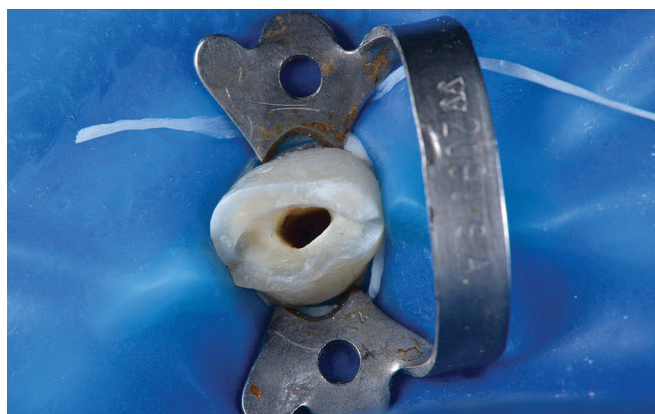
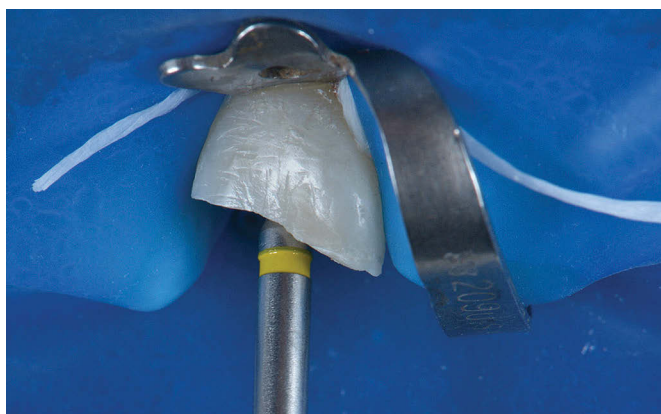
**Figure 3.** Facial and palatal view after removal of the deficient direct composite restoration on teeth #11 and 21.



**Figure 4.** Periapical radiograph and clinical procedure shows removal of the individual cast post from the root canal using a spherical diamond tip and ultrasonic inserts.


After complete removal of gutta-percha, working lengths were determined by applying an electronic apex locator (ProPex II, Dentsply/Maillefer, Switzerland). Cleaning and shaping of the root canal were performed up to K-files #80 with copious irrigation. Calcium hydroxide was kept as intracanal medication for 21 days. Then, root canal filling was performed by means of cold lateral compaction technique (Fig 6).

Control radiography was performed immediately after endodontic retreatment, revealing homogeneity with apical filling levels corresponding to the electronically determined working lengths. Space for installation of a new post was prepared immediately after root canal filling. Gates-Glidden and Largo drills were used to remove gutta-percha from the cervical and middle thirds of the root canal. Figure 7 shows absence of adaptation of the



**Figure 5.** Clinical aspect and periapical radiography showing root canal filling removal.





**Figure 6.** Facial view of endodontic retreatment.

prefabricated post in the radicular canal, indicating the use of an anatomic post.


The pre-fabricated post was immersed in 24%  $H_2O_2$  at room temperature for 1 minute and then rinsed with distilled water and air-dried. A single layer of silane coupling agent was applied to the post surface and gently air-dried after 60 seconds. The adhesive (Scotchbond Multiuse Plus, 3M ESPE, USA) was applied over the post surface and light-cured for 20 seconds. Light activation was performed using a halogen lamp (VIP Jr; Bisco Inc, Schaumburg, IL) with 600-mW/cm<sup>2</sup> irradiance (Fig 7).

The direct anatomic post was shaped using the method described by Grandini et al.<sup>17</sup> After lubrication of the canal walls with glycerin gel (Fig 8), the fiber post (Reforpost, Angelus, Brazil) was covered with

composite resin (Tetric Ceram, Ivoclar Vivadent, Liechtenstein) and inserted into the canal (Fig 8). The composite resin was initially photoactivated for 10 s. Subsequently, the post-composite set was removed from the canal and fully photoactivated for other 60 s (Fig 8).

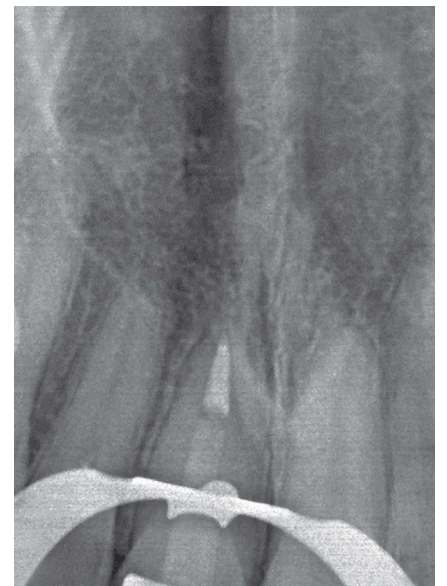

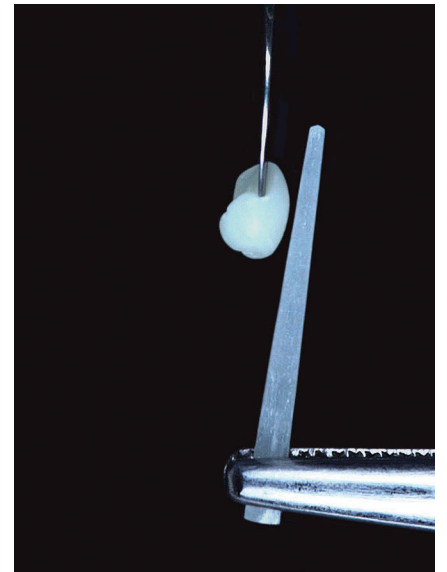

The anatomic post was rinsed with distilled water and air-dried. A single layer of silane coupling agent was applied to the post surfaces and gently air-dried after 60 s (Fig 9). Root dentin surfaces were irrigated with 10 ml of irrigant NaOCl for 60 s and with 10 ml of physiologic saline for 60 s.

RelyX U200 (3M ESPE, USA), a self-adhesive resin cement, was used for luting. The catalyst and base components of the material were mixed and applied in accordance with manufacturer's instructions. The resin cement was placed into the

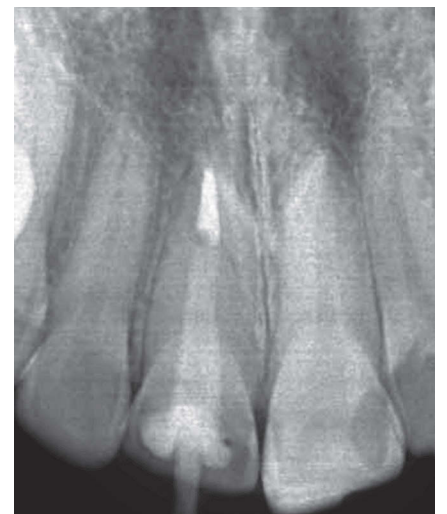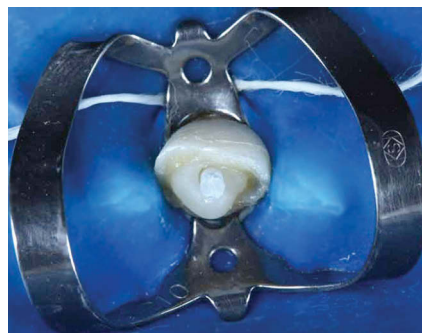
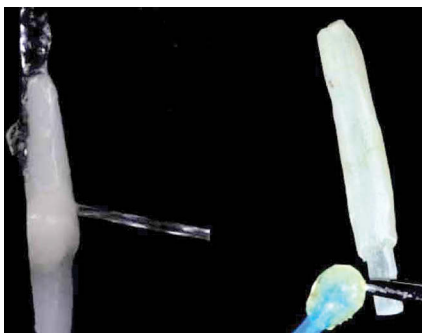


**Figure 7.** Selection and surface treatment of post.



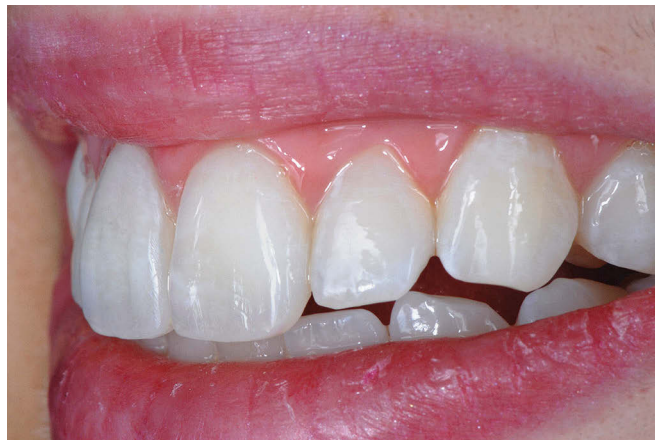
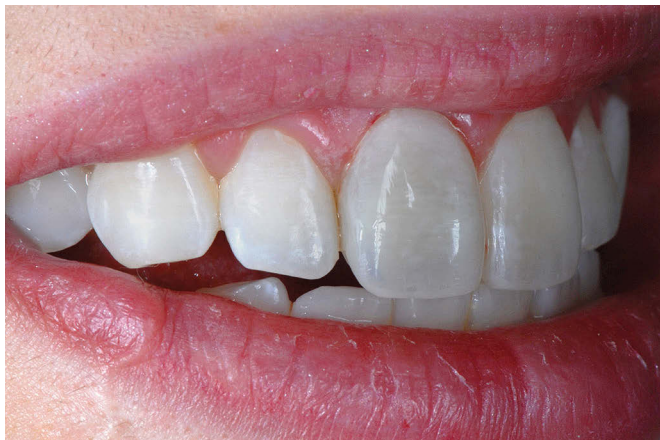
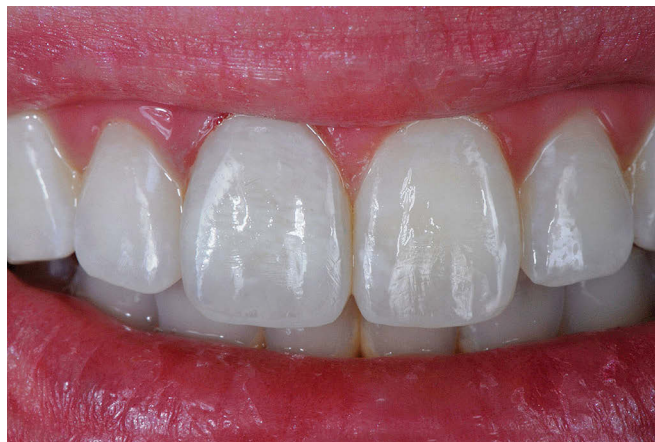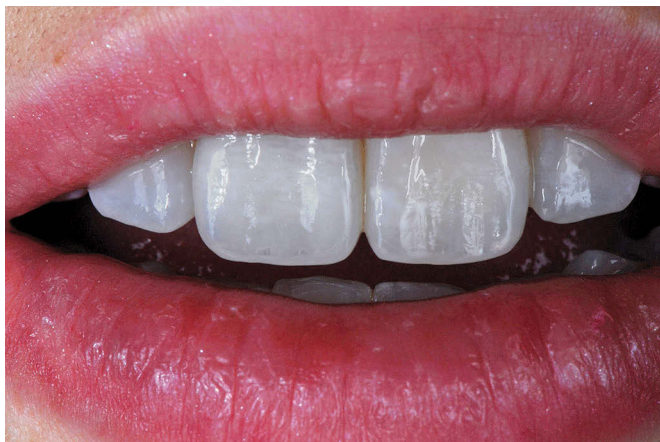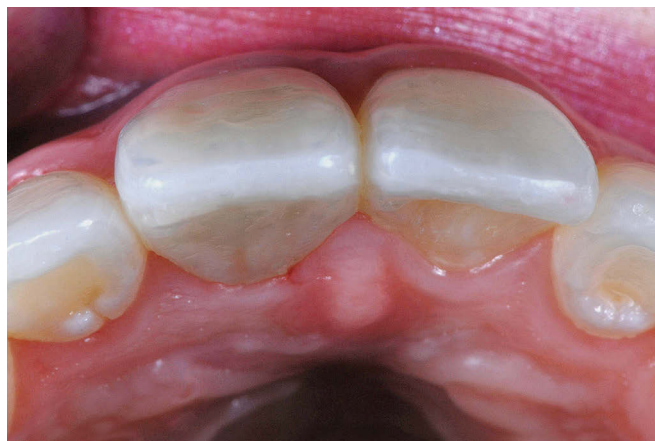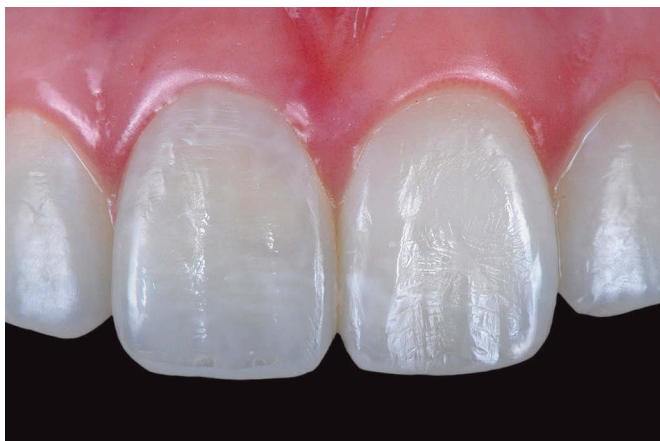**Figure 8.** Build of the anatomic post and test.



**Figure 9.** Surface treatment and cementation of anatomic post.





**Figure 10.** Postoperative photograph.

root canal space, the post was seated and excess material was removed before light-curing for 40 s. Due to patient's young age, the clinician decided to postpone preparation for a prosthetic crown. The anatomic post was therefore simply used as a base for direct composite restoration. The prepared tooth was etched with 37% phosphoric acid (Bisco, USA) applied as recommended by the manufacturer. Restoration was completed with resin composite (Empress Direct, Ivoclar Vivadent, Liechtenstein) (Fig 9). Periapical radiography shows the final outcomes (Fig 9) and postoperative photographs show beautiful and functional results (Fig 10).

## Discussion

The ferrule effect greatly influences fracture resistance, especially in decoronated teeth. A ferrule, defined as a circumferential area of axial dentin superior to the preparation bevel, should have a height of 1.5 to 2.5 mm.<sup>13,19,20</sup> Various *in vitro* studies have shown that fracture resistance can be significantly increased by the use of a ferrule; post length or design (either parallel-sided or tapered) are of secondary importance for fracture resistance if a sufficient ferrule can be provided.<sup>13,19,20</sup>

Should deep destruction of teeth render sufficient ferrule impossible, surgical crown lengthening can be performed. This procedure can provide a crown ferrule which results in reduction of static load failure.<sup>20</sup> Bolhuis et al<sup>21</sup> asserts that crown ferrule is more important than a post and core, or a core reconstruction with adhesive filling, only.

The type of fixation used for post also influences its required length. Nissan et al<sup>22</sup> showed that adhesive fixation can compensate for reduced retention due to the use of shorter parallel-sided or tapered posts. Testori et al<sup>23</sup> demonstrated that there is no significant difference in the retention of adhesive fixed posts measuring 5 mm or 8 mm. These results, however, are less reliable because they were ascertained with a very limited number of samples.

Other studies<sup>24,25</sup> assessed remaining root filling after post-space preparation, especially with respect to leakage. They showed that leakage increases with post-space preparation, and a remaining apical filling of less than 3 mm results in unpredictable seal.

Based on some results,<sup>26,27</sup> lower concentration (24%) of H<sub>2</sub>O<sub>2</sub> used for only 1 minute are preferable

in clinical use. The use of peroxide over the fiber post increased bond strengths. The deleterious effect of peroxide was probably not observed due to the absence of residual oxygen into the post structure. Another important observation was the absence of cohesive failures within the resin composite during microtensile tests. The high flow of resin used in this study probably allowed close contact between the resin and the post, reducing the presence of voids.<sup>28</sup>

Polymerization shrinkage and associated stresses (the C-factor and S-factor) are a major consideration in all bonding/restorative procedures. In this case, C-factor is not higher than it is in post cementation<sup>29</sup> because of the high number of surfaces involved. Even though composite resin core material generally have more filler and, therefore, higher strength than resin cements, polymerization shrinkage stress is higher with 70% filler than that with 10% filler.<sup>30</sup> This may seem counterintuitive to most dentists, but the objective is to employ a technique that compensates for the inherent deficiencies of some types of material and capitalizes on them without becoming clinically cumbersome, time-consuming, or with the integration of outside laboratory fees.

In an earnest attempt to address these factors, Grande et al<sup>31</sup> and Plotino et al<sup>18</sup> described chairside techniques for adapting prefabricated fiber posts to ribbon-like, oval, or ovoid canal spaces by remodeling them. Their results suggest that the volume of cement is minimized, and the retentive surfaces of the post are not compromised.

In order to reduce resin cement layer thickness and its disadvantages, Boudrias et al<sup>32</sup> described the use of an anatomic post. Clavijo et al<sup>33</sup> suggested that anatomic posts seem to be a good alternative for restoring flared root canals. In this technique, the fiber post is reshaped to fit the root canal using composite resin. The enhanced mechanical properties compared to resin cements leads to fracture strength values similar to those of cast metal post-and-core. The technique for fabrication of direct anatomic posts is relatively easy. In addition, by adding only a few more steps to those required to lute a conventional fiber post, it is possible to achieve better fitting quality. Moreover, thickness of the cement layer, in which voids and bubbles are likely to develop, can be minimized.<sup>11,12</sup>



## Conclusion

Direct anatomic post technique is relatively easy. It indicates that anatomic posts are a good alternative for restoring flared root canals. In addition, by adding only a few more steps to those required to lute a conventional fiber post, it is possible to achieve better fitting quality.

## References

1. Peroz I, Blankenstein F, Lange KP, Naumann M. Restoring endodontically treated teeth with posts and cores-a review. *Quintessence Int.* 2005;36(9):737-46.
2. McDonald AV, King PA, Setchell DJ. In vitro study to compare impact fracture resistance of intact root-treated teeth. *Int Endod J.* 1990;23(6):304-12.
3. Baratieri LN, De Andrada MA, Arcari GM, Ritter AV. Influence of post placement in the fracture resistance of endodontically treated incisors veneered with direct composite. *J Prosthet Dent.* 2000;84(2):180-4.
4. Pilo R, Tamse A. Residual dentin thickness in mandibular premolars prepared with gates glidden and ParaPost drills. *J Prosthet Dent.* 2000;83(6):617-23.
5. Assif D, Bitenski A, Pilo R, Oren E. Effect of post design on resistance to fracture of endodontically treated teeth with complete crowns. *J Prosthet Dent.* 1993;69(1):36-40.
6. Isidor F, Brøndum K, Ravnholt G. The influence of post length and crown ferrule length on the resistance to cyclic loading of bovine teeth with prefabricated titanium posts. *Int J Prosthodont.* 1999;12(1):78-82.
7. Duret B, Reynaud M, Duret F. New concept of coronoradicular reconstruction: the Composipost (1). *Chir Dent Fr.* 1990;60(540):131-41.
8. Guzy GE, Nicholls JL. In vitro comparison of intact endodontically treated teeth with and without endo-post reinforcement. *J Prosthet Dent.* 1979;42(1):39-44.
9. Asmussen E, Peutzfeldt A, Heitmann T. Stiffness, elastic limit, and strength of newer types of endodontic posts. *J Dent.* 1999;27(4):275-8.
10. Strassler HE, Cloutier PC. A new fiber post for esthetic dentistry. *Compend Contin Educ Dent.* 2003;24(10):742-8.
11. Desai S. Principles and technique of using bonded post and cores. *Compend Contin Educ Dent.* 2006;27(8):439-45.
12. Dallari A, Rovatti L, Dallari B, Mason PN, Suh BI. Translucent quartz-fiber post luted in vivo with self-curing composite cement: case report and microscopic examination at a two-year clinical follow-up. *J Adhes Dent.* 2006;8(3):189-95.
13. Mason PN. Bond studies of the composite-fiber post system. In: *Symposium on New Developments in Fiber Post Systems*, 1999. Schaumburg, IL; [s.n.]; 1999.
14. D'Arcangelo C, Cinelli M, De Angelis F, D'Amario M. The effect of resin cement film thickness on the pullout strength of a fiber-reinforced post system. *J Prosthet Dent.* 2007;98(3):193-8.
15. De-Deus G, Murad C, Paciornik S, Reis CM, Coutinho-Filho T. The effect of the canal-filled area on the bacterial leakage of oval-shaped canals. *Int Endod J.* 2008;41(3):183-90.
16. Grandini S, Goracci C, Monticelli F, Borracchini A, Ferrari M. SEM evaluation of the cement layer thickness after luting two different posts. *J Adhes Dent.* 2005;7(3):235-40.
17. Grandini S, Sapio S, Simonetti M. Use of anatomic post and core for reconstructing an endodontically treated tooth: a case report. *J Adhes Dent.* 2003;5(3):243-7.
18. Plotino G, Grande NM, Pameijer CH, Somma F. Influence of surface remodelling using burs on the macro and micro surface morphology of anatomically formed fibre posts. *Int Endod J.* 2008;41(4):345-55.
19. Sorensen JA, Engelman MJ. Ferrule design and fracture resistance of endodontically treated teeth. *J Prosthet Dent.* 1990;63(5):529-36.
20. Gegauff AG. Effect of crown lengthening and ferrule placement on static load failure of cemented cast post-cores and crowns. *J Prosthet Dent.* 2000;84(2):169-79.
21. Bolhuis HPB, De Gee AJ, Feilzer AJ, Davidson CL. Fracture strength of different core build-up designs. *Am J Dent.* 2001;14(5):286-90.
22. Nissan J, Dmitry Y, Assif D. The use of reinforced composite resin cement as compensation for reduced post length. *J Prosthet Dent.* 2001;86(3):304-8.
23. Testori T, Badino M, Castagnola M. Vertical root fractures in endodontically treated teeth: a clinical survey of 36 cases. *J Endod.* 1993;19(2):87-91.
24. Abramovitz L, Lev R, Fuss Z, Metzger Z. The unpredictability of seal after post space preparation: a fluid transport study. *J Endod.* 2001;27(4):292-5.
25. Wu MK, Pehlivan Y, Kontakiotis EG, Wesselink PR. Microleakage along apical root fillings and cemented posts. *J Prosthet Dent.* 1998;79(3):264-9.
26. Menezes M, Faria-e-Silva A, Silva F, Reis G, Soares C, Stape T, Martins L. Etching a fiber post surface with high-concentration bleaching agents. *Oper Dent.* 2013 Jul 12. [Epub ahead of print].
27. Menezes MS, Queiroz EC, Soares PV, Faria-e-Silva AL, Soares CJ, Martins LR. Fiber post etching with hydrogen peroxide: effect of concentration and application time. *J Endod.* 2011;37(3):398-402.
28. Monticelli F, Goracci C, Grandini S, Garcia-Godoy F, Ferrari M. Scanning electron microscopic evaluation of fiber post-resin core units built up with different resin composites. *Am J Dent.* 2005;18(1):61-5.
29. Breschi L, Mazzoni A, De Stefano DE, Ferrari M. Adhesion to intraradicular dentin: a review. *J Adhes Sci Technol.* 2009;23:1053-83.
30. Ferrari M, Carvalho CA, Goracci C, Antonioli F, Mazzoni A, Mazzotti G, Cadenaro M, Breschi L. Influence of luting material filler content on post cementation. *J Dent Res.* 2009;88(10):951-6.
31. Grande NM, Butti A, Plotino G, Somma F. Adapting fiber-reinforced composite root canal posts for use in noncircular-shaped canals. *Pract Proced Aesthet Dent.* 2006;18(9):593-9.
32. Boudrias P, Sakkal S, Petrova Y. Anatomical post design meets quartz fiber technology: rationale and case report. *Compend Contin Educ Dent.* 2001;22(4):337-40, 342, 344 passim; quiz 350.
33. Clavijo VG, Reis JM, Kabbach W, Silva AL, Oliveira Junior OB, Andrade MF. Fracture strength of flared bovine roots restored with different intraradicular posts. *J Appl Oral Sci.* 2009;17(6):574-8.