

# Horizontal root fracture in the middle third: Case report

Jefferson J. C. **MARION**<sup>1</sup>  
Juliana Yuri **NAGATA**<sup>2</sup>  
Ketrin Kimberly **RAMOS**<sup>3</sup>  
Frederico Campos **MANHÃES**<sup>4</sup>

## ABSTRACT

**Introduction:** Dental trauma may be considered one of the main causes of permanent teeth loss, and root fractures are relatively uncommon in these situations. **Objective:** The aim of this study was to report a clinical case of horizontal root fracture promoted by a dental trauma and discuss their clinical implications. **Methods:** The horizontal root fracture occurred at the middle third of the maxillary central incisor with separation of the fragments.

The tooth was diagnosed with pulp necrosis, and the endodontic treatment was performed. **Results:** After a follow-up period of two years with radiographic and tomographic images root complications were not observed, neither painful symptomatology, highlighting the importance of a correct diagnosis which results in a good prognosis, preserving the esthetic and psychological integrity of the patient.

**Keywords:** Endodontics. Dental trauma. Root fracture.

**How to cite this article:** Marion JJC, Nagata JY, Ramos KK, Manhães FC. Horizontal root fracture in the middle third: Case report. *Dental Press Endod.* 2013 Jan-Apr;3(1):88-93.

» The authors report no commercial, proprietary or financial interest in the products or companies described in this article.

<sup>1</sup>PhD Student in Dental Clinic – Endodontics, UNICAMP. Professor, Department of Endodontics – ABO and UNINGÁ.

<sup>2</sup>MSc and PhD in Dental Clinic – Endodontics, UNICAMP.

<sup>3</sup>Graduated in Dentistry, UNINGÁ.

<sup>4</sup>PhD in Dental Clinic – Endodontics, UNICAMP.

Received: April 08, 2013. Accepted: April 09, /2013.

Contact address: Jefferson José de Carvalho Marion  
Rua Néo Alves Martins, 3176 – 6º andar – sala 64 – Centro  
CEP: 87.013-060 – Maringá/PR – Brazil  
Email: jefferson@jmarion.com.br / atendimento@jmarion.com.br

## Introduction

One of the main causes of anterior permanent tooth loss is dental trauma, representing 24% of dental absence due to infection and mobility in traumatized teeth.<sup>1,2</sup> Upper central incisors are vulnerable to this type of injury, being affected in 80% of dental trauma, followed by upper lateral incisors and lower incisors.<sup>3,4</sup>

Considering the types of trauma, root fractures are less frequent, with prevalence of 0.5% to 7% in permanent dentition and 2 to 4% in deciduous teeth.<sup>5</sup> Similar to dental trauma in a general manner, these fractures occur mainly in central incisors (68%) and lateral incisors (27%), and only 5% in lower incisors.<sup>6</sup> It happens in consequence of an impact force at the top of the root and frontal forces in the compression zone directed to vestibular and lingual, dividing root in coronal and apical fragments. This division may cause harmful consequences to cement, dentin, pulp and periodontal tissues.<sup>2</sup>

Root stage development, displaced fragments reposition and all signals and symptoms associated, such as pain and mobility may influence repair process of root fracture.<sup>7,8,9</sup> Literature describes different positions where fracture may be located — such as those restrict to cervical third, oblique fracture involving cervical and middle third, in the middle third, and in the apical third — as well as its influence in the treatment success.<sup>10</sup> The treatment protocols related to cicatrization, reposition and contention reported in the literature are mainly determined empirically and without a relevant data base.<sup>2</sup>

The prognosis of root fractures is favorable in 60-80% cases, however complications such as pulp necrosis, root resorption and calcification of root canal may emerge.<sup>3</sup>

According to pulp lesion, and considering the possibility of bacterial invasion in the fracture line, four types of tissue repair may occur: Fusion of fragments by means of hard tissue formation, interposition of connective tissue or a “fake union” due to the presence of chronic inflammatory tissue between the fragments.<sup>11,12</sup>

The present study has the purpose to report a clinical case of dental trauma with horizontal root fracture, pulp necrosis and endodontic treatment of fragments, as well as to discuss clinical implications.

## Case report

A 16-year-old male patient attended a particular Endodontics clinic after he had suffered a dental trauma during football practice. He did not present systemic alteration. Clinically, it was observed soft tissue lacerations (lips, tongue and gingiva) as well as right central maxillary incisor commitment (tooth #11). In addition, gingival tissue at this tooth presented bleeding at the cervical region, with mobility and light extrusion. At the radiographic exam, it was observed that the right incisor presented horizontal root fracture at the medium third with separation of the fragments (Fig 1A).

The patient and his responsible were informed about the difficulties and complications of the treatment, agreeing to perform the protocol suggested by Gulinelli et al.<sup>13</sup> At first, lips lacerations were sutured, and then the fragments were repositioned through the application of a vertical force in the incisal portion of the tooth, with local anesthesia. It was performed splintage of the coronal fragment with composite resin. It was prescribed amoxicillin 500 mg for 7 days, nimesulide 100 mg for three days and sodium dypiron for three days too.

After 45 days, patient returned for clinical and radiographic follow-up, being possible to note root fragments separation and absence of pulp sensibility for thermal and cold tests (Endo-Frost, Roeko®, Germany) (Fig 1B).

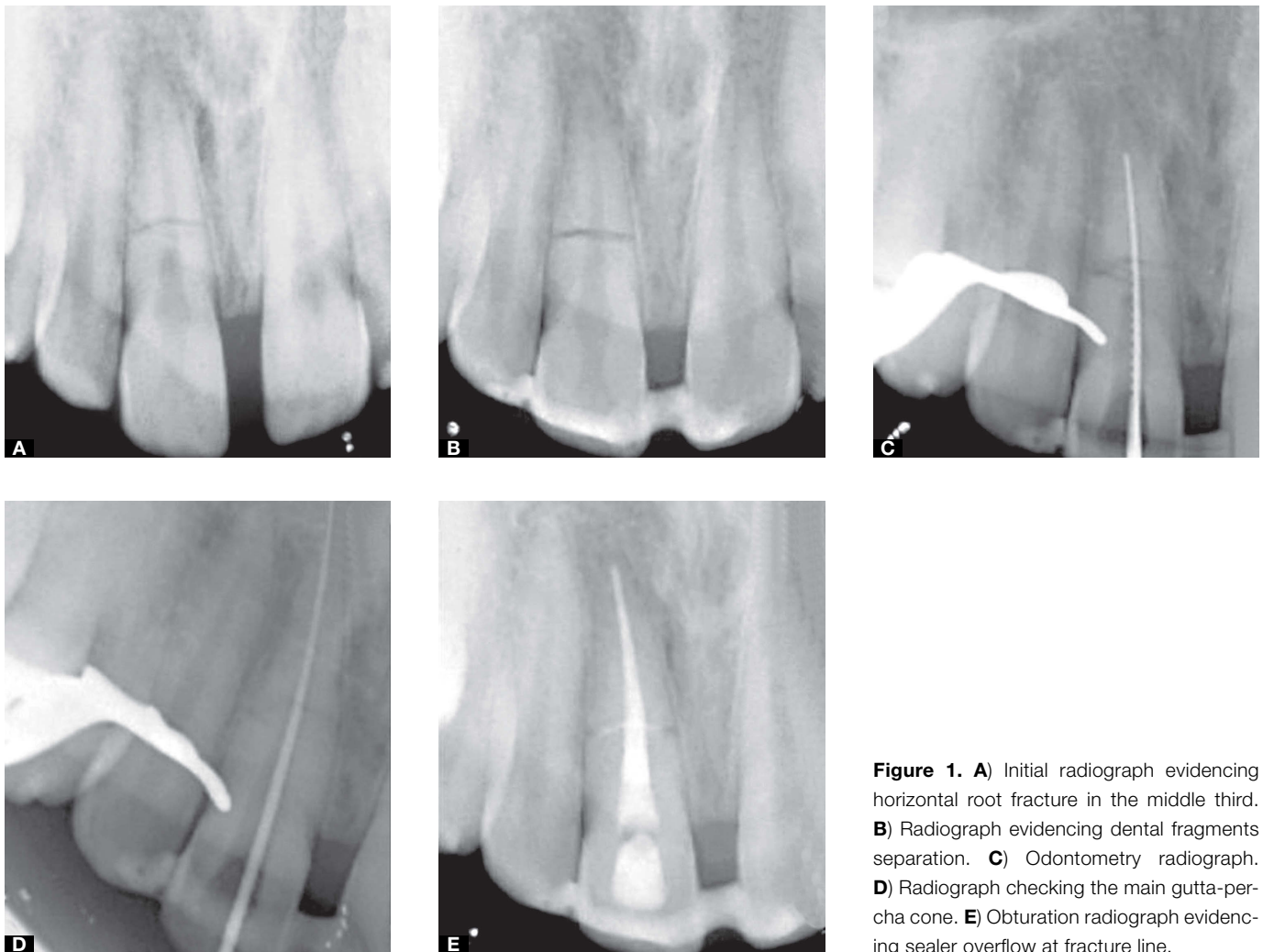
In face of pulp necrosis, it was decided for endodontic treatment. During odontometry, it was possible to observe an access to apical fragment and working length was established at 25 mm including radiographic apex (Fig 1C). Chemomechanical prepare was performed in the whole extension of root canal fragments under the presence of 2.5% sodium hypochlorite (NaOCl).

After instrumentation, root canal was dried with sterile paper points (Konne®, Belo Horizonte, Brazil) and dressed with calcium hydroxide paste (Biodinâmica®, Ibioporã, Brazil) associated to propyleneglycol vehicle for a period of 30 days. After this period, intracanal medicament was removed with a manual file (Dentsply Maillefer, Ballaigues, Switzerland) and irrigant solution (2.5% NaOCl). In the sequence, root canal was irrigated with EDTA 17% (Biodinâmica®, Ibioporã, Brazil) for 3 minutes with mechanical agitation. EDTA

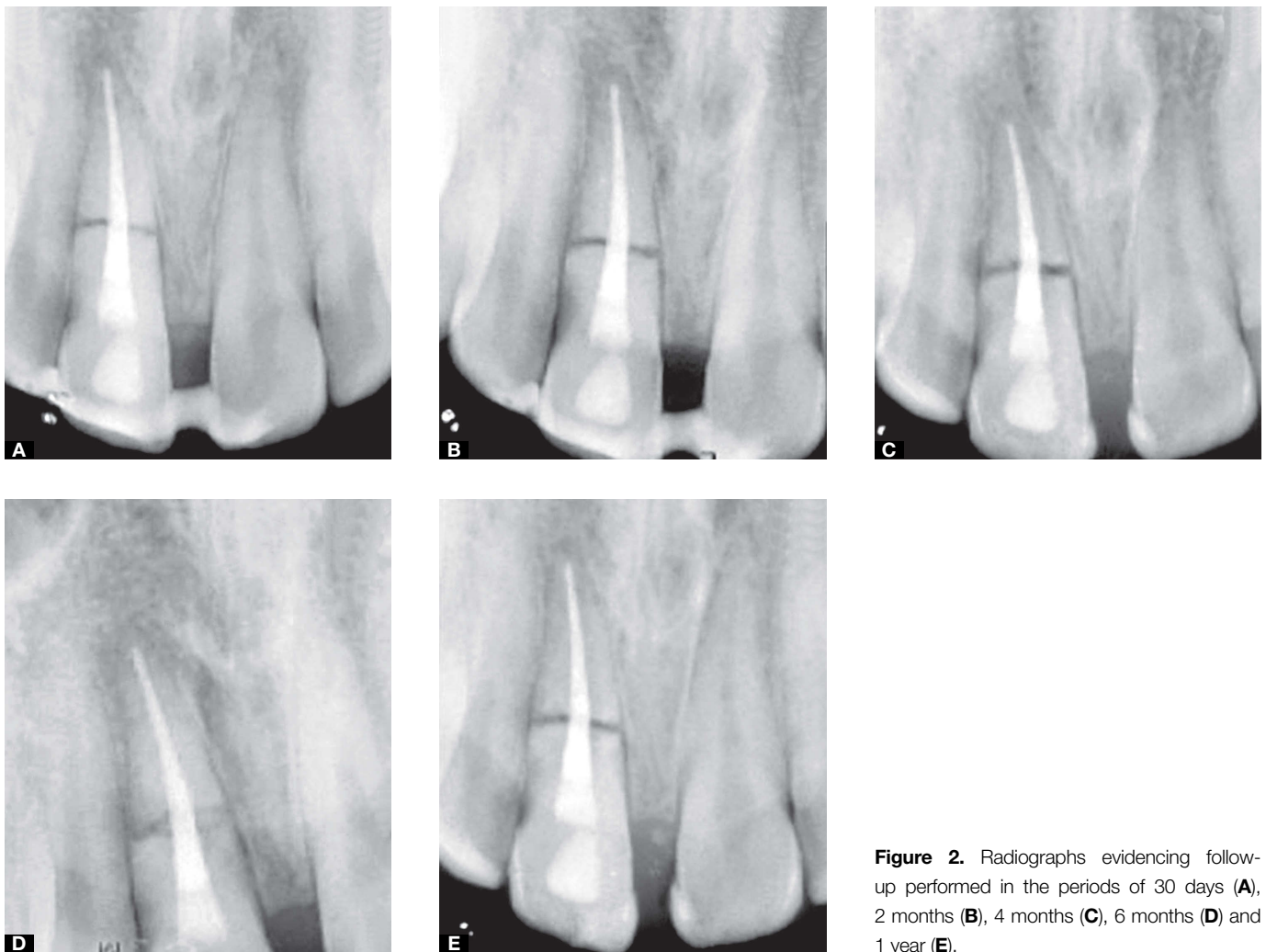
was removed by irrigating 2.5% NaOCl, with another insertion of paper points for drying the canal. Then, it was performed the main gutta-percha cone try out (Fig 1D), definitive obturation of root canal using gutta-percha cones and obturation cement with calcium hydroxide in its composition (Sealapex®- SybronEndo (SDS)/Glendora, USA). The obturation technique was the lateral condensation followed by vertical condensation. It was radiographically observed sealer overflow at the horizontal fracture region (Fig 1E).

Clinical and radiographic follow-up was performed after 30 days (Fig 2A), after 2 months (Fig 2B), 4 months (Fig 2C), 6 months (Fig 2D) and 1 year (Fig 2E). None of the follow-ups demonstrated pathological alteration such as: root resorption, radiolucency regions as well as painful symptomatology.

Two-year follow-up was performed with radiograph (Fig 3A) and tomograph (Figs 3B, C, D, E), being possible to note that the affected tooth presented characteristics compatibles with the normality.



**Figure 1.** A) Initial radiograph evidencing horizontal root fracture in the middle third. B) Radiograph evidencing dental fragments separation. C) Odontometry radiograph. D) Radiograph checking the main gutta-percha cone. E) Obturation radiograph evidencing sealer overflow at fracture line.



**Figure 2.** Radiographs evidencing follow-up performed in the periods of 30 days (A), 2 months (B), 4 months (C), 6 months (D) and 1 year (E).

## Discussion

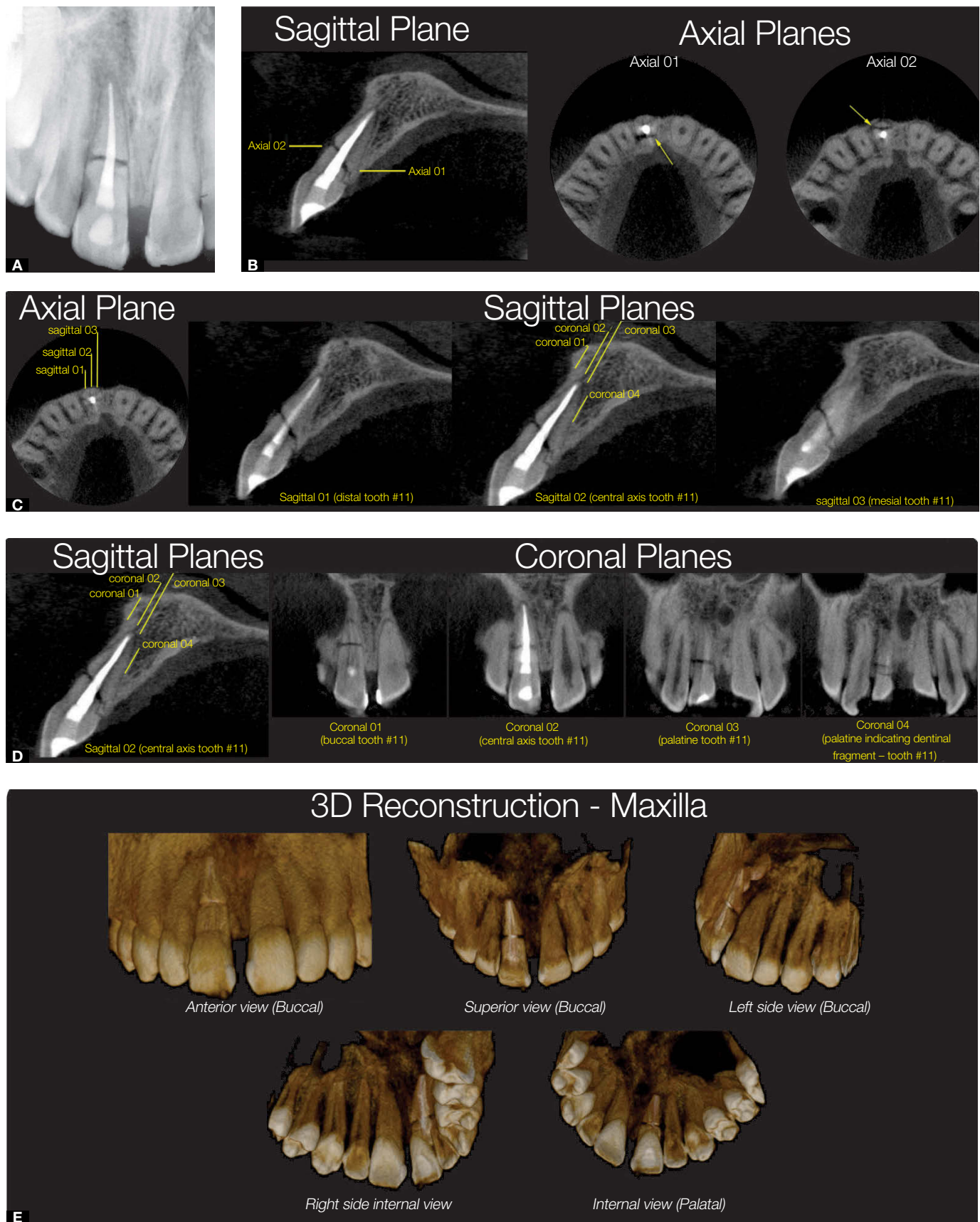
Dental trauma may be considered a multifactorial problem considering diagnosis, long-term treatment and follow-up.<sup>14</sup> These injuries may occur due to car accidents, sportive lesions, violence and malocclusion.<sup>3,15</sup> The present case report described a right central incisor trauma due to sportive activity, which is in accordance with other studies that show 80% of prevalence of dental trauma in upper central incisors.<sup>3,4</sup>

Root fractures in children and young people, and root fractures with minimum separation of the fragments should not preventively receive endodontic treatment since its prognosis is favorable.<sup>16</sup> In addition, patient age at the moment of the injury may be considered one of the main factors to pulp repair after root fracture.<sup>17</sup> In the present case report, after 45 days, it was observed pulp necrosis despite of being a young patient. This situation

also may have occurred due to the rupture of neuro-vascular bundle of the dental pulp, or even because of bacterial invasion through apical foramen promoting bacterial infection and subsequent pulp ischemia in a manner that revascularization could not happen.<sup>18</sup>

Endodontic treatment of the tooth was performed considering that literature reports repair of root fractures after endodontic treatment.<sup>19</sup> In addition, studies describe four types of endodontic treatment for these situations: 1) chemomechanical preparation only in the coronal fragment and endodontic obturation of it; 2) chemomechanical preparation of both fragments with endodontic obturation of them; 3) chemomechanical preparation only of the coronal fragment with endodontic obturation of it and surgical removal of apical fragment; 4) chemomechanical preparation of coronal and apical fragments, filling the canal with calcium hydroxide dressing and posterior





**Figure 3.** **A)** Periapical radiograph of 2-years follow-up; **B)** Sagittal tomographic slice indicating the axial tomographic slices with fracture in the middle third; **C)** Axial tomographic slice indicating the sagittal tomographic slices with fracture in the middle third. **D)** Sagittal tomographic slice indicating coronal tomographic slices with fracture in the middle third. **E)** Maxilla tomographic slice in tridimensional reconstruction.

endodontic obturation of them.<sup>20,21</sup> According to these studies, it was decided for the fourth treatment option aforementioned, considering that it was possible to access the apical fragment of the root and that calcium hydroxide antimicrobial and remineralizing actions should have positively contributed for the success.<sup>22</sup> However, there are other studies with follow-up periods ranging from 2 to 31 years,<sup>3,23</sup> that demonstrated 100% of repair in root fractures cases using only splintage.

Regarding tissue composition in the fracture line, Welbury et al<sup>2</sup> observed dentin and cementum formation, which is dependent of odontoblast and cementoblast activity. In the 2-year follow-up tomograph, it was not possible to observe root fracture repair with hard tissue deposition, which may be explained due to the extrusion and separation of coronary fragments, while connective tissue union is more observed in cases of pulp necrosis and coronary fragment separation.<sup>2</sup>

Another factor that should be considered is the importance of long-term follow-up, because there is the possibility of occurrence of pathological alterations several years after the lesion.<sup>24</sup>

## Conclusions

It is important to remember that treatment success depends on the patient-professional relation, considering the realization of therapeutic attitudes immediately after the occurrence of complications. Pulp necrosis and absence of repair at the root fracture line through hard tissue deposition may occur in permanent teeth. A permanent tooth with root fracture that was endodontically treated may present a good prognosis, preserving esthetic and psychological integrity of the patient. Clinical and radiographic follow-up is essential for treatment success of a tooth with horizontal root fracture.

## References

- Ruellas RMO, Ruellas AÇO, Ruellas CVO, Oliveira MM, Oliveira AM. Reimplante de dentes permanentes avulsionados: relato de caso. *Rev Un Alfenas*. 1998;4:179-81.
- Welbury RR, Kinirons MJ, Day P, Humphreys K, Gregg TA. Outcomes for root-fractured permanent incisors: a retrospective study. *Pediatr Dent*. 2002;24(2):98-102.
- Andrade ES, Campos Sobrinho AL, Andrade MG, Matos JL. Root healing after horizontal fracture: a case report with a 13-year follow up. *Dent Traumatol*. 2008;24(4):e1-3.
- Hovland EJ. Horizontal root fractures. Treatment and repair. *Dent Clin North Am*. 1992;36(2):509-25.
- Andreasen FM, Andreasen JO, Cvek M. Root fractures. In: Andreasen JO, Andreasen FM, Andersson L. *Textbook and color atlas of traumatic injuries to the teeth*. Copenhagen: Munksgaard; 2007. p. 337-71.
- Çalışkan MK, Pehlivan Y. Prognosis of root-fractured permanent incisors. *Endod Dent Traumatol*. 1996;12(3):129-36.
- Cvek M, Andreasen JO, Borum MK. Healing of 208 intra-alveolar root fractures in patients aged 7-17 years. *Dent Traumatol*. 2001;17(2):53-62.
- Andreasen JO, Andreasen FM, Mejåre I, Cvek M. Healing of 400 intra-alveolar root fractures. 1. Effect of pre-injury and injury factors such as sex, age, stage of root development, fracture type, location of fracture and severity of dislocation. *Dent Traumatol*. 2004;20(4):192-202.
- Artvinli LB, Dural S. Spontaneously healed root fracture: report of a case. *Dent Traumatol*. 2003;19(1):64-6.
- Cvek M, Tsilingaridis G, Andreasen JO. Survival of 534 incisors after intra-alveolar root fracture in patients aged 7-17 years. *Dent Traumatol*. 2008;24(4):379-87.
- Alvares S, Alvares S. *Tratamento do Traumatismo dentário e de suas sequelas*. São Paulo: Ed. Santos; 1993. p. 45-54.
- Tsukiboshi MO. Optimal use of photography, radiography and micro computed tomography scanning in the management of traumatized teeth. *Endodontic Topics*. 2006;14(1):4-19.
- Gulinelli JL, Kanno CM, Poi WR. Reparo de fratura radicular com tecido calcificado. Relato de caso clínico. *Rev Assoc Paul Cir Dent*. 2006;60(5):395-8.
- Andreasen JO, Vinding TR, Christensen SSA. Predictors for healing complications in the permanent dentition after dental trauma. *Endodontic Topics*. 2006;14(1):20-7.
- Legan JJ, Brown CE Jr, Andres CJ. Unusual fracture of a maxillary second premolar. *J Endod*. 1995;21(5):285-6.
- Flores MT, Andersson L, Andreasen JO, Bakland LK, Malmgren B, Barnett F, et al. Guidelines for the management of traumatic dental injuries. I. Fractures and luxations of permanent teeth. *Dent Traumatol*. 2007;23(2):66-71.
- Andreasen JO, Andreasen FM, Mejåre I, Cvek M. Healing of 400 intra-alveolar root-fractures. 1. Effect of pre-injury and injury factors such as sex, age, stage of root development, fracture type, location of fracture and severity of dislocation. *Dent Traumatol*. 2004;20(4):192-202.
- Andreasen JO, LÖvschall H. Response of oral tissues to trauma. In: Andreasen JO, Andreasen FM, Andersson L, editors. *Text Book and Color Atlas of Traumatic Injuries to the Teeth*. Oxford: Blackwell; 2007. p. 62-96.
- Lindahl B. Transverse intra-alveolar root fractures. Roentgen diagnosis and prognosis. *Odontol Revy*. 1958;9:10-24.
- Michanowicz AE. Root fractures. A report of radiographic healing after endodontic treatment. *Oral Surg Oral Med Oral Pathol*. 1963;16:1242-8.
- Cvek M. Treatment of non-vital permanent incisors with calcium hydroxide IV. Periodontal healing and closure of the root canal in the coronal fragment of teeth with intraalveolar fracture and vital apical fragment. *Odont Rev*. 1974;25:239-46.
- Cvek M, Mejåre I, Andreasen JO. Conservative endodontic treatment of teeth fractured in the middle or apical part of the root. *Dent Traumatol*. 2004;20(5):261-9.
- Poi WR, Manfrin TM, Holland R, Sonoda CK. Repair characteristics of horizontal root fracture: a case report. *Dent Traumatol*. 2002;18(2):98-102.
- Saroglu I, Sönmez H. Horizontal root fracture followed for 6 years. *Dent Traumatol*. 2008;24(1):117-9.