

Bone reaction capability and the names of inflammatory bone disorders in endodontic clinical practice

Alberto **CONSOLARO**¹
Renata Bianco **CONSOLARO**²

ABSTRACT

Reactional inflammatory bone diseases are common in the jaws and are associated with periapical lesions. A chronic dentoalveolar abscess represents a chronic purulent osteitis, just like periapical granuloma is a chronic granulomatous osteitis. Imagiologically, chronic inflammatory periapical injuries are osteitis which manifest themselves either as bone rarefactions, either as sclerotic areas. The terms “rarefying diffuse lesion” or “sclerosing at the periapex” are used in reports to identify chronic inflammatory periapical lesions that represent true reactive inflammatory bone diseases with specific names by the direct relationship with

the teeth as dentoalveolar abscess and periapical granulomas. When teeth are extracted they can leave imagiologically detected structural changes, such as bone sclerosis and rarefactions, without the possibility of establishing a cause and effect relationship, making it hard to provide a secure diagnosis. In planning, a previous diagnosis of bone status implies recognizing injuries and pathological situations. The standardization of nomenclature and concepts can facilitate communication and the establishment of uniform protocols and behaviors.

Keywords: Osteitis. Osteomyelitis. Periostitis. Osteonecrosis. Periapical diseases.

¹ Full Professor at Bauru Dental School and Post-graduating courses at Ribeirão Preto Dental School, University of São Paulo.

² Professor of Adamantinenses Integrated Schools.

How to cite this article: Consolaro A, Consolaro RB. Bone reaction capability and the names of inflammatory bone disorders in endodontic clinical practice. *Dental Press Endod.* 2012 Apr-June;2(2):12-9.

» The authors report no commercial, proprietary or financial interest in the products or companies described in this article.

A normal bone: understanding the structure and functions

The bone may be analyzed as an anatomical piece or as an organ that forms blood cells, due to the bone marrow, but it can be studied as a tissue with specific functions and structures, including cells.

To meet the functional requirements related to movement and protection, as well as the mechanisms of ionic balance of the organism, at every moment storing and repositioning many mineral components in blood plasma, human skeleton completely renews itself every period of 2 to 4 years in children, and from 4 to 10 years in adults.

Bones present soft and hard tissues. At the mineralized part of the bone, such as corticals and trabeculae, are included osteoblasts, osteocytes and osteoclasts. The periosteum, endosteum and bone marrow are not mineralized and they fill the spaces delimited by the mineralized parts.

The periosteum, a real natural membrane, is composed of a fibrous connective tissue densely collagenized in its external part, while its inner part is intersected by collagen fibers that penetrate and merge with the cortical mineralized bone matrix, fixing it firmly to the external bone surfaces. Inside it, at the interface with the cortical bone, the periosteum presents itself richly cellularized with abundant osteoblasts and clasts as well as by young cells, undifferentiated and even bone tissue stem cells or reserve cells. Every bone blood supply passes through, necessarily, the periosteum.

In turn, the endosteum, a very fragile membrane tissue, covers the surface of the trabeculae and inner parts of corticals. Also consists of tissue with few collagen fibers and rich in osteoblastic reserve cells, covering cells and/or osteoprogenitor cells, also bone tissue stem cells. The endosteum, while covering the bone trabeculae, continues naturally with the fibrous or adipose hematopoietic tissue, filling the marrow spaces.

The bone lodges in its structure the hematopoietically active bone marrow when it is red; or inactive, when replaced by fibrous or adipose tissue and then presents itself yellow or grayish white.

Osteoblasts, osteocytes and osteoclasts are mature bone cells which, in line with other components, such as macrophages, promote bone remodeling and at the same time contribute to fulfill its functions in this tissue. In the process of bone remodeling, besides the cells there are three key enzymes which serve as parameter to measure metabolic activity in the human skeleton: acid phos-

phatase, located on osteoclasts, which also release collagenase, both involved in bone resorption; on the other hand, there is the alkaline phosphatase localized in osteoblasts, related to bone formation.

Adaptive and reactive capacity of bone tissue: understanding sclerosis and rarefactions in periapical trabeculate

Bone adaptations to situations and functions represent its reactive capability and, when extrapolated, it originates a group of bone diseases named reactional or inflammatory, which are clinically very important in clinical practice, due to:

1. Their frequency.
2. The sequelae resulting from their occurrence.
3. The possibility of resulting from unnoticed important dental changes.
4. The possibility of deriving from professional interventions such as bone surgeries, inappropriate treatments and lack of precise identification of patient's organic deficiency in the medical history and systemic review.

Bone reactive capability, resistance to stimuli or aggressions depends on the following three key factors:

1) Local bone morphology

A more compact or dense cancellous bone presents small marrow spaces that provide little room for the more abundant inflammatory exudates. In a very short time, inflammation may increase the pressure within the small medullary spaces, compressing vessels, complicating venous return and leading more rapidly the medullary tissue to necrosis. A bone marrow tissue area with necrosis can be the ideal place for bacteria to lodge and build microbial biofilms.

Bone tissue with more sparse or loosely distributed trabeculae, facing aggression, provide more spaces for infiltration and inflammatory exudate, allowing a longer time, which increases its defensive ability to eliminate the aggressors from the site.

It can be said that the more compact bone tissue is much stronger physically, but biologically fragile, for it requires a very fast and extremely efficient functioning of the inflammatory process. The contrary also occurs with less compact and more cancellous bone: it gives longer time and space for the inflammation tools — the exudate and the infiltrate — to act against the aggressors.

2) Aggression intensity and duration

A mild and constant irritation, sometimes referred to as chronic, like all aggressors, promotes an initial acute inflammation, but soon it evolves into a mild or moderate chronic phase, with a restricted accumulation of mediators at the site.

Many mediators of the inflammatory exudate are inducers of bone resorption, but present bipolar effects: when in high concentration, induce predominantly clastic activity, but when at low levels in the same environment bone, induce synthesis of osteoblastic activity with new bone formation, predominating in trabecular and cortical surfaces.

The mediators that induce new bone formation on trabecular and subperiosteal surfaces gradually change the local bone morphology, that remains organized. As the irritation increases its harmful power, the neoformation reaction may also occur, but in a not so organized way.

The rapid and intense irritation, also referred to as acute, promotes an initial acute inflammation, but much more exudative and rich in mediators to induce bone resorption and it may induce necrotic areas on bone marrow and endosteal tissue, and osteocytes.

It can be said that chronic or mild irritation induces bone formation or productive reactions predominant of synthesis phenomena, whereas acute or severe aggressions cause bone resorptive, osteolytic or destructive reactions.

3) Host systemic state

The host systemic state may be determinative in bone reactions against aggressions. Overall, osteomyelitis occurs only in systemically compromised patients or with extensive sclerotic local bone diseases.

The three most common causes of osteomyelitis are:

- a) Trauma with open fractures.
- b) Bone surgery in contaminated environments.
- c) Bone surroundings with infectious foci in other tissues, such as in infected channels.

In the jaws, these three situations occur in thousands of people in daily dental practice and the number of osteomyelitis does not stand out compared to other skeletal structures.

When the patient is systemically normal, the same causes that would induce osteomyelitis will promote

osteitis, also an inflammatory process but localized and focal, with less consequences, because the osteolytic areas are restricted and small, predominating areas with bone sclerosis, and the symptomatology is very low. The prognosis of osteitis is very good.

Reactional or inflammatory bone diseases: name and concepts applied to periapical and periodontal areas

The reactional inflammatory bone diseases may represent the exhaustion of the adaptive capability of the bone against external or internal aggressors. The terminology / nomenclature used to identify reactional and inflammatory bone diseases is very important to standardize diagnostic procedures, treatment protocols and monitoring, as well as to understand imagiologic reports and studies on the subject.

Before conceptualizing each of the names applied to identify them, it is very important to distinguish the terms “disease” and “lesion,” since they have a lot in common, but different meanings.

The diseases, or clinical entities, are changes and biological processes outside the structural and functional normality of tissue and organs. Diseases, or clinical entities, represent specific and repetitive signs which allow identification or diagnosis by any qualified professional. Diseases induce transient or permanent structural changes in anatomical tissues and organs, changes called lesions. Lesion means any anatomical alteration of any kind, in tissues or organs, i.e., it represents a term with broad and daily use.

The reactional and inflammatory bone diseases may be denominated according to their diagnosis:

» **Osteomyelitis:** Characterized by bone inflammation with sudden and symptomatic onset, that may involve the three structural components — the mineralized part, tissue components of the medullary spaces and periosteum.^{2,7,8,10,15} Its origin is predominantly microbial, but may be physical and chemical, such as substances leaked to the periapex via channel during irrigation procedures. Generally, the bone area affected is broad and diffuse, with predominantly osteodestructive phenomena.

Osteomyelitis rarely occurs in systemically healthy patients. Almost all cases have an underlying disease such as diabetes mellitus, immunosuppression, anemia, among others; or even the patient presents at the site

of osteomyelitis a sclerosing advanced disease such as florid cemento-osseous dysplasia, for example. In endodontics, periapical inflammatory processes rarely evolve into osteomyelitis, for systemic conditions of patients generally are not weakened or so compromised to significantly reduce its defensive capabilities.

» **Osteitis:** Characterized by an usually asymptomatic inflammatory process that slowly may also involve up to the three structural components of bone, but, in general, is a localized and predominantly osteoproliferative phenomena.^{1,5,6,9,11,12,14,17} In general, the causes of osteitis have low intensity and long duration.

These diseases are common in periapex, especially when the root canal is infected. Acute or chronic periapical lesions, when considered only bone structures, are perfect examples of osteitis, but when involving tooth roots they receive specific names, such as dentoalveolar abscesses and periapical granulomas.

In long term occlusal trauma, it is not difficult to observe in periapex and/or in lateral alveolar bone and in the bone crest itself, imagiological findings indicating chronic and sclerosing focal osteitis. Not only microbial causes can induce osteitis, occlusal trauma represents an etiology of physical nature.

» **Periostitis:** Characterized by the inflammatory response of periosteum against aggressive agents that act directly or indirectly on its structures. When the cause is acute or intense and acts directly, it can be destructive and part of other broader processes such as abscess and dentoalveolar osteomyelitis.^{4,13,16,18,19,20} However, when the cause is chronic, with low-intensity and long duration on its structures, the periosteum involved reacts producing new bone layers on cortical surface, and it is known as periostitis ossificans or productive, once mistakenly named as Garré's osteomyelitis.

In children, adolescents and young adults with long-term chronic periapical lesions, or chronic periodontitis, the periostitis ossificans explains the hardened swellings on

the corresponding cortical surface and which promote facial asymmetries. After treatment, these "swellings" may disappear over a few weeks or months without any "drainage" or corrective surgery. Radiologically, they are evidenced only with underexposure and occlusal views due to the low degree of organization and mineralization of the reactive bone deposited on cortical surface.

» **Osteoradionecrosis and osteoradiomyelitis:** It can be considered a specific or special variant of osteomyelitis in areas of osteonecrosis by radiation, usually for therapeutic purposes in oncology.^{3,10} Based on animal studies, osteoradionecrosis can be considered an state in which the irradiated bone presents itself for some years with:

- a) Chronic hypoxia, promoted by obliterative endarteritis obstructing the passage of blood to the cells, because part of the vascular lumens is occupied by the increased thickness of the inner wall of blood vessels.
- b) Hypovascularization, since the entire cell population in this site is decreased, including endothelial cells, which form the internal lining of blood vessels.

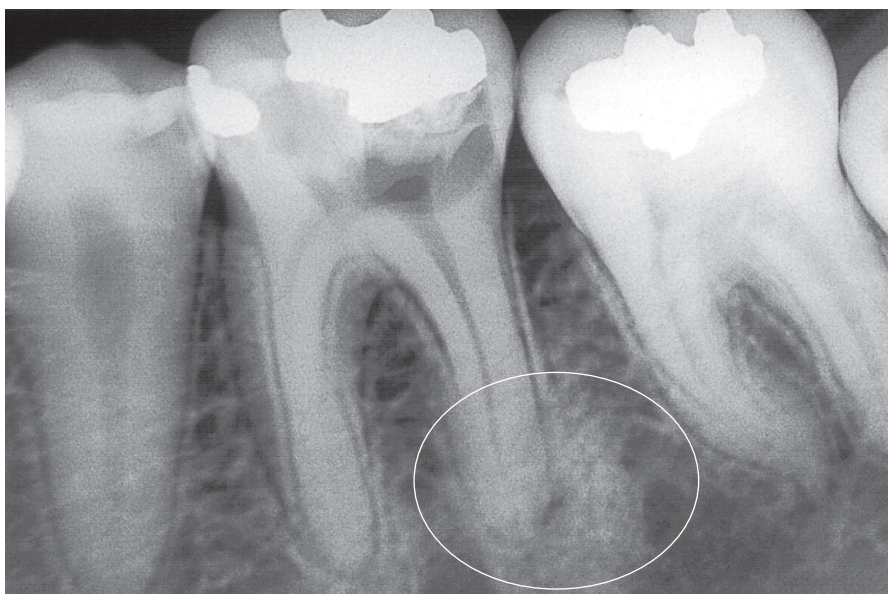


Figure 1. In periapical bone tissue, inflammation corresponds to chronic focal sclerosing osteitis related to necrotic pulp and chronic inflammatory periapical lesions. Radiopaque areas are predominant, corresponding to thickening of trabeculae and reduced marrow spaces. Smaller and irregular rarefying areas immediately around the opening of the root canal in which the low intensity and long duration aggressors come out. From a clinical and dental point of view, these signs can be diagnosed as chronic inflammatory periapical lesions compatible with periapical granuloma. There was no fistula.

- c) Local hypocellularity in the irradiated area, due to small mitotic index of the region, reducing its ability to be reactive and reparatory.
- d) Death of osteocytes, a very important cell in bone histophysiology. Each osteocyte connects with other 40-50 cells, forming an intercommunicating network with trabecular and cortical surfaces, thus controlling the bone shape, its subperiosteal responses and also strongly influencing the local and systemic ionic balance.

For a period of 5 to 10 years, the irradiated bone tissue presents a low defensive and reactional capability, and at the same time its reparatory potential decreases. After this period, the irradiated region tends to return to its previous reparatory potential. In these bone conditions, bacteria and other not as aggressive aggressors find local and conditions to

proliferate in this weakened bone structure and the inflammatory process becomes insufficient to contain them, thus establishing a secondary acute suppurative osteomyelitis and then chronic, also known as osteoradiomyelitis, although it is a term rarely used in the literature. It seems logical to distinguish that osteoradionecrosis is the state of the irradiated bone and osteoradiomyelitis corresponds to the osteomyelitis or inflammation in that modified bone.

» **Osteonecrosis:** Increased bone surgery and placement of osseointegrable dental implants widely promoted the use of some terms hitherto little used by clinicians, such as osteonecrosis.

Osteonecrosis can be conceptualized as bone death without infection and induced by many factors such as trauma, excessive heat, thrombi and emboli, radiation, grafts and chemical products.^{3,10}

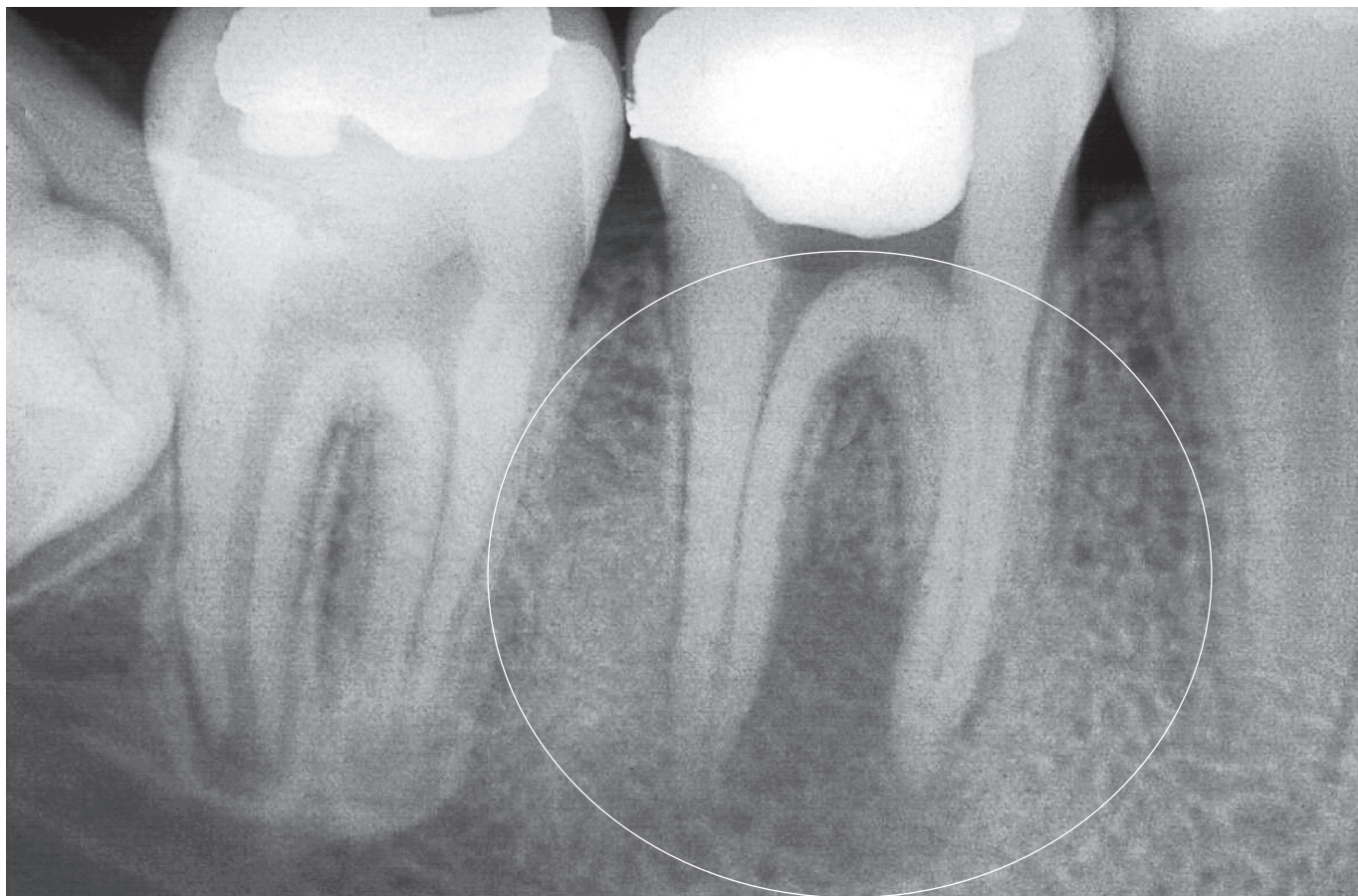


Figure 2. In bone environment, the lesion may be diagnosed as chronic focal rarefying osteitis related to necrotic pulp and chronic inflammatory periapical lesions with imagiologic bone rarefaction predominance with discrete sclerotic peripheral areas. From a clinical and dental point of view, this scenario can be diagnosed as chronic inflammatory periapical lesions compatible with chronic dentoalveolar abscess. The radiolucent areas are more extensive than in the case of Figure 1, and it indicates that the aggressor has a higher pathogenicity, comparatively. Clinically, there was intraoral fistula.

However, the term “necrosis”, conceptually, should only be applied to cells, as it represents cell death in a living organism without any genetic involvement in its occurrence. The bone, as an anatomical organ, is not in necrosis, but is biologically unfeasible as a tissue in the context of our body.

Many agents may act on bone and kill its cells, by necrotizing them, and if this occurs with osteocytes, which are its most internal cells and protected by mineralized matrix, it can be said that the bone became biologically unfeasible. It can be argued that a bone without osteocytes needs to be completely restored, it is with no biological viability, should be resorbed and replaced by new bone tissue rich in osteocytes.

Physical agents may act on bone tissue, such as radiation and excessive heat, and also chemical products. Both types of aggression can lead to osteocyte necrosis and therefore such injured areas can receive the name of osteonecrosis, but not as a clinical condition or disease.

The death of osteocytes and/or an area with osteonecrosis induces on its periphery, and then inside it, an inflammation localized and restricted to a certain area and with low symptomatology. Bone tissue made unviable by osteocytes death has a certain aggressiveness to the surrounding tissues, induces a low symptomatic and restricted inflammatory process in this bone area, i.e., induces an osteitis. In short, osteonecrosis induces and resolves itself after an osteitis.

After a few days of aseptic inflammation at the site, or osteitis in cancellous bone, it evolves to the formation of granulation tissue by migration, proliferation and invasion of endothelial and osteoblastic surrounding cells, permeating the medullary spaces of bone necrosis area. Gradually, the newly formed part replaces the old bone.

In cortical osteonecrotic areas, osteitis occurs almost in its interface, and gradually the clasts resorb and invade the small spaces, and the neighboring osteoblasts will be forming and entering in the osteonecrotic area, merging the old part with the new one, until all necrosed tissue is replaced. The formation of granulation tissue is very small and restricted to external surfaces.

Osteonecrosis, and subsequent osteitis, may delay or prevent bone healing and osseointegration; they are:

- a) **Osteonecrosis by local hyperthermia:** situation where part of the bone in a surgical area loses its viability by dehydration or denatur-

ation, which means loss of water with coagulation of proteins and loss of vitality of cells. The heat can be generated by electric surgical saws and worn cutters while placing implants. This tissue will be reabsorbed by clasts so it can be replaced by normal bone in a repair context. During this period while it is not fully resorbed, it will be infiltrated by poly and mononuclear leukocytes, as well as by clasts. At the local, exudate or inflammatory edema will also be present, characterizing a chronic osteitis induced by heat excess or local hyperthermia. Since the cause has been eliminated with the surgery, the only option is to wait until the body repair the area so it can be reevaluated the possible consequences, if any.

- b) **Chemical osteonecrosis:** chemical products can be poured on bone environment, such as chlorinated soda, used in endodontic irrigation. The acute inflammatory process can dilute the chemical, which will disappear in a few days. The local chronic osteitis, its macrophages, phagocytes, along with clasts, promote cleaning of the area, which gradually repair, unless it is secondarily infected by bacteria. In many cases, this process has been named chemical osteomyelitis, but the process is restricted to the site and without systemic involvement, proving wrong the use of the term osteomyelitis.
- c) **Drug-induced osteonecrosis:** Term used to identify areas of unviable bone believed to be associated with the use of bisphosphonates, especially in cancer patients. These drugs do not kill other osteocytes or bone cells, nor obliterate the vessels and even depress the immune system.

However, cancer patients are systemically debilitated, especially due to the numerous and powerful medicines ingested, as well as by chemotherapy and radiotherapy that they undergo. Patients get immunosuppressed, and their tissues with few vessels and cells. Any microorganism that gets to the bone of this type of patient may induce suppurative osteomyelitis clinical signs, whose evolution leads to fistula formation and bone losses. The ingestion of the bisphosphonate drug represents a superimposition in the situation and not a primary cause of this osteonecrosis, although many surgeons insist on assigning

such problems in cancer patients to bisphosphonates, which in biological and medical fields is not considered. Patients with cancer have several local and systemic debilitating conditions that increase their susceptibility to osteomyelitis.

Other often used terms in bone biopathology

In the jaws, rarely the systemic metabolic bone diseases alter the morphology of corticals and trabeculate, for the rate or velocity of bone turnover is very low. When affecting the jaws, the disease is highly evolved, or terminal. Long before this stage, other medical problems led the patient to seek for treatment and medical advice. Still, some concepts about skeletal states are important because they are often used or mentioned when describing pathological states of varied nature in the jaws. They are:

1. **Osteopenia:** Bone condition characterized by thinner and shorter trabeculae and thinner cortex, increasing the susceptibility to fractures. Several systemic metabolic bone diseases may promote this bone state, which is very difficult to happen in the jaws, being more often diagnosed in long bones. It is not a disease but a condition or bone state.
2. **Osteoporosis:** Bone condition characterized by osteopenic bone with subclinical or clinically diagnosed fractures. It can be argued that osteopenia can progress to osteoporosis, but not necessarily. This term is necessarily related to the presence of fractures in osteopenic bone. Osteoporosis can be classified into primary, when it is post-menopausal, and secondary, when results from endocrine or kidney disorders. Other factors associated with osteoporosis are smoking habit, alcoholism, low intake of calcium and surgical or premature menopause. It is not a disease but a condition or bone state that can be induced by various diseases.
3. **Osteomalacia:** Bone state characteristic of adults, resulting from a disturbance with inadequate mineralization of newly formed bone matrix. The term osteomalacia means soft bones. The osteopenic osteomalacia has a pattern with fractures or pseudo-fractures. Several diseases can lead to osteomalacia, often related to impaired metabolism of vitamin D.

4. **Osteopetrosis:** Group of at least nine rare congenital developmental disorders, characterizing a disease induced by an autosomal dominant developmental disorder, also known as stone bone or marble bone disease, which reflects his intense radiopaque appearance. The texture is very hard, like a rock, including the cartilaginous areas. The bone is easily fractured. There is almost no marrow and it is even described the splenomegaly and hepatomegaly with enlarged lymph nodes to compensate for lack of hematopoiesis, besides severe anemia. In the end there is compression of nerves in the foramen, also promoting facial paralysis.
5. **Sclerosis or bone condensation:** State with increase in thickness and number of bone trabeculae, decreasing the size and appearance of medullary spaces in radiographs and CT scans.

Conclusions

The reactional and inflammatory bone diseases are very common in the jaws and most of them are related or associated directly or indirectly with endodontic and periodontal changes.

The periapical lesions can be direct causes of inflammatory reactional bone lesions or may constitute the osteitis itself. For example, a chronic dentoalveolar abscess is a purulent chronic osteitis, just like a periapical granuloma is a chronic granulomatous osteitis. Imagiologically, chronic inflammatory periapical lesions are osteitis manifested as bone rarefactions with random and diffuse associated sclerosing areas, or peripherally, in a more organized way.

Often it is observed, in imagiologic reports, terms as diffuse rarefying lesion in the premolar periapex or the use of names such as chronic rarefying or sclerosing osteitis in the molar periapex. These terms are generally applied in these reports to identify inflammatory chronic periapical lesions that represent true bone inflammatory reaction, with specific names by the direct relationship with the teeth. These specific names would be dentoalveolar abscess and periapical granulomas, for example.

When teeth are extracted, structural changes may be imagiologically detected, such as bone sclerosis and rarefactions, with no possibility of establishing a cause and effect relationship, hindering the diagnosis in many cases. Knowing bone biopathology has fundamental importance, since teeth are inserted into the

bone, moving naturally or orthodontically through the bone, as well as jaws often receive and adapt themselves to dental implants.

In rehabilitation, orthodontic and pre-surgical planning, previous diagnosis of maxillary bone status

implies recognizing injuries and pathological situations involving them in clinical practice. The standardization of nomenclature and concepts can facilitate communication and the establishment of protocols and uniform behaviors.

References

1. Araki M, Matsumoto N, Matsumoto K, Ohnishi M, Honda K, Komiya K. Asymptomatic radiopaque lesions of the jaws: a radiographic study using cone-beam computed tomography. *J Oral Sci.* 2011 Dec;53(4):439-44.
2. Calhoun KH, Shapiro RD, Stiernberg CM, Calhoun JH, Mader JT. Osteomyelitis of the mandible. *Arch Otolaryngol Head Neck Surg.* 1988 Oct;114(10):1157-62.
3. Epstein JB, Wong FL, Stevenson-Moore P. Osteoradionecrosis: clinical experience and a proposal for classification. *J Oral Maxillofac Surg.* 1987 Feb;45(2):104-10.
4. Eversole LR, Leider AS, Corwin JO, Karian BK. Proliferation periostitis of Garré: its differentiation from other neoperiostoses. *J Oral Surg.* 1979 Oct;37(10):725-31.
5. Eversole LR, Stone CE, Strub D. Focal sclerosing osteomyelitis/focal periapical osteopetrosis: radiographic pattern's. *Oral Surg Oral Med Oral Pathol.* 1984 Oct;58(4):456-60.
6. Geist JR, Katz JO. The frequency and distribution of idiopathic osteosclerosis. *Oral Surg Oral Med Oral Pathol.* 1990 Mar;69(3):388-93.
7. Hudson JW. Osteomyelitis of the jaws. A 50-year perspective. *J Oral Maxillofac Surg.* 1993 Dec;51(12):1294-301.
8. Kadom N, Egloff A, Obeid G, Bandarkar A, Vezina G. Juvenile mandibular chronic osteomyelitis: multimodality imaging findings. *Oral Surg Oral Med Oral Pathol Oral Radiol Endod.* 2011 Mar;111(3):e38-43.
9. MacDonald-Jankowski DS. Idiopathic osteosclerosis in the jaws of Britons and of the Hong Kong Chinese: radiology and systematic review. *Dentomaxillofac Radiol.* 1999 Nov; 28(6):357-63.
10. Marx RE, Tursun R. Suppurative osteomyelitis, bisphosphonate induced osteonecrosis, osteoradionecrosis: a blinded histopathologic comparison and its implications of the mechanism each disease. *Int J Oral Maxillofac Surg.* 2012 Mar;41(3):283-9.
11. McDonnell D. Dense bone island; a review of 107 patients. *Oral Surg Oral Med Oral Pathol.* 1993 Jul;76(1):124-8.
12. Miloglu O, Yalcin E, Buyukkurt MC, Acemoglu H. The frequency and characteristics of idiopathic osteosclerosis and condensing osteitis lesions in a Turkish patient population. *Med Oral Patol Oral Cir Bucal.* 2009 Dec 1;14(12):e640-5.
13. Nortjé CJ, Wood RE, Grotepass F. Periostitis ossificans versus Garré's osteomyelitis: part II—radiologic analysis of 93 cases in the jaws. *Oral Surg Oral Med Oral Pathol.* 1988 Aug;66(2):249-60.
14. Sisman Y, Ertas ET, Ertas H, Sekerci AE. The Frequency and Distribution of Idiopathic Osteosclerosis of the Jaw. *Eur J Dent.* 2011 Aug;5(4):409-14.
15. Swei Y, Taguchi A, Tanimoto K. Diagnosis and classification of mandibular osteomyelitis. *Oral Surg Oral Med Oral Pathol Oral Radiol Endod.* 2005 Aug;100(2):207-14.
16. Tong AC, Ng IO, Yeung KM. Osteomyelitis with proliferative periostitis: an unusual case. *Oral Surg Oral Med Oral Pathol Oral Radiol Endod.* 2006 Nov;102(5):e14-9.
17. Williams TP, Brooks SL. A longitudinal study of idiopathic osteosclerosis and condensing osteitis. *Dentomaxillofac Radiol.* 1998 Sep;27(5):275-8.
18. Wood RE, Nortjé CJ, Grotepass F, Schmidt S, Harris AM. Periostitis ossificans versus Garre's osteomyelitis. Part I. What did Garré really say? *Oral Surg Oral Med Oral Pathol.* 1988 Jun;65(6):773-7.
19. Wood Nk, Goaz Pa. Diagnóstico diferencial das lesões bucais. 2a. ed. Rio de Janeiro: Guanabara Koogan; 1983.
20. Zand V, Lotfi M, Vosoughhosseini S. Proliferative periostitis: a case report. *J Endod.* 2008 Apr;34(4):481-3.