

Computed tomography in the diagnosis of root perforation

Priscila Dias **PEYNEAU**¹

Claudia Scigliano **VALERIO**¹

Andréia Cruz Pires Ribeiro de **SOUSA**¹

Flávio Ricardo **MANZI**²

ABSTRACT

Introduction: Perforation is defined as communication between the root canal and the external tooth surface, normally occurs during endodontic treatment and is induced by iatrogenic causes. There are some conditions that favor the perforations, among others the irregular morphology of root canals, root dilaceration, error during pulp chamber preparation, excessive wear of root canal walls and inadequate preparation for intraradicular post placement. **Methods:** The definitive diagnosis of this type of iatrogenic condition is very difficult due

the limitation of periapical radiography, as it offers a two-dimensional image and superimposition of structures. For this reason, imaging methods such as computerized tomography, which allows all the root faces to be evaluated, should be used in order to diagnose and inform the location of root perforations with greater precision. **Conclusion:** The present study demonstrated the importance of cone beam computerized tomography in the diagnosis of root perforation in three clinical cases.

Keywords: Root canal therapy. Tooth root. Cone-beam Computed tomography. Diagnosis. Root canal therapy.

How to cite this article: Peyneau PD, Valerio CS, Sousa ACPR, Manzi FR. Computed tomography in the diagnosis of root perforation. *Dental Press Endod.* 2012 Jan-Mar;2(1):65-9.

» The authors report no commercial, proprietary or financial interest in the products or companies described in this article.

Submitted: 02/20/2012. Revised and accepted: 02/24/2012.

¹MSc in Dental Clinics, PUC-Minas.

²Adjunct Professor of Radiology and Coordinator of MSc program in Dental Clinics, emphasis in Radiology, PUC-Minas.

Contact address: Flávio Ricardo Manzi
Av. Dom José Gaspar, Prédio 45 – Clínica de Radiologia Coração Eucarístico
30.535-901 – Belo Horizonte/MG – Brazil
E-mail: manzi@pucminas.br

Introduction

Perforation is one of the most frustrating complications of endodontic treatment. Over the last few years, the incidence has rise due to negligence, imprudence and inexperience of new professionals. An artificial communication in the root caused by iatrogenic conditions or pathological resorptions that result in an intimate relationship between pulp cavity and periodontal tissues may be considered a perforation. Iatrogenic perforations are caused by different factors, such as irregular morphology of root canals, high incidence of root dilaceration, error during pulp chamber preparation, excessive wear of root canal walls, calcifications and perforations resulting from inadequate preparations for intraradicular posts.¹⁻⁶

Among the clinical aspects of perforation, one could mention pain, sensitivity to palpation, presence of fistula and/or periodontal pocket. The radiographic characteristics include increase in the periodontal ligament space and bone rarification adjacent to the region of the perforation, in addition to visualization of the perforation when it occurs on the mesial and distal surfaces.^{2,3}

Periapical radiography is the first exam requested in cases of perforation, as it offers information about the condition and morphology of the root and root canal. However, there is the limitation of the vestibular-lingual plane, as the image is two-dimensional and anatomic repairs may be confused with pathological lesions.^{1,5,7} Therefore, advanced imaging methods, such as computerized tomography should be used, which allow visualization and evaluation of the root and alveolar bone, location and extension of the pulp chamber and a tridimensional view of the root.^{1,8}

Thus, tridimensional images are valuable in the diagnosis and treatment of dental problems.⁷

The prognosis for teeth with root perforation depends mainly on prevention and the use of biocompatible material in the repair to provide the best possible sealing against bacterial penetration and limit periodontal inflammation,⁶ in addition to the experience and skill of the professional, location of the perforation, quality of endodontic treatment, periodontal conditions and perforation size. Therefore, the greatest complication resulting from perforation is the potential for a secondary inflammation in the periodontal ligament causing loss of bone insertion and consequently leading to tooth loss.^{4,5,6}

The aim of this study is to demonstrate the importance of computerized tomography in locating and diagnosing root perforation, by means of three clinical case reports.

Clinical case 1

The patient, 43 years of age, was referred for evaluation of the maxillary right first molar that presented painful symptoms after root canal preparation for intraradicular post fabrication. By means of the clinical exam, probing, negative palpation and sensitivity to vertical and horizontal percussion, the presence of fistula was identified in the region of the tooth in question.

The patient was submitted to multislice computerized tomography, using the SOMATOM Sensation 64[®] appliance (Siemens, Erlangen, Germany) involving the region of interest. In the panoramic reconstruction, a lesion was observed in the furca and in the oblique reconstructions the presence of perforation and bone rarefaction in the palatine root of the

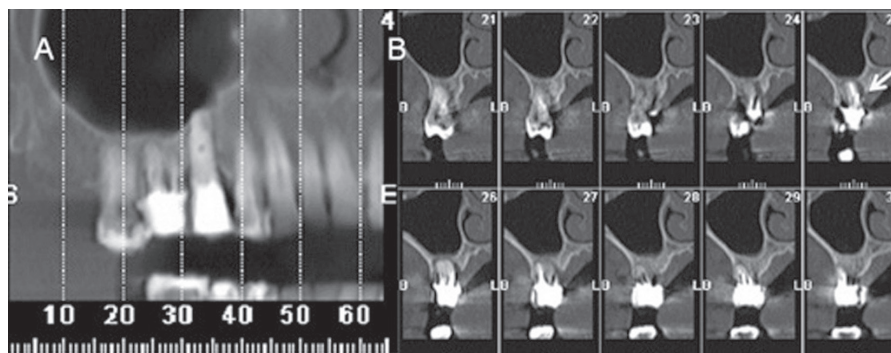


Figure 1. A) Observe tooth #16 in panoramic reconstruction. B) Oblique reconstruction: Note the white arrow indicating present of root trepanation in teeth #16 (slide 25).

maxillary right first molar (Fig 1). In this case, due to the compromised furca as and perforation, the prognosis was not favorable and the tooth was extracted.

Clinical case 2

Patient, 34 years of age presented at the dental clinic with slight painful symptoms and swelling in the apical region of tooth #21 seven months after conclusion of endodontic treatment in this tooth.

CBCT was performed with the appliance GXCB-500 Powered by i-CAT® (Imaging Sciences, Hatfield, USA). In the panoramic reconstruction, only bone rarefaction was observed in the periapex of tooth #21. In the oblique reconstructions, the presence of perforation can be identified (Fig 2). In this situation, the perforation was sealed with mineral trioxide aggregate (MTA), as it is a biocompatible material that prevents leakage and promotes tissue regeneration.

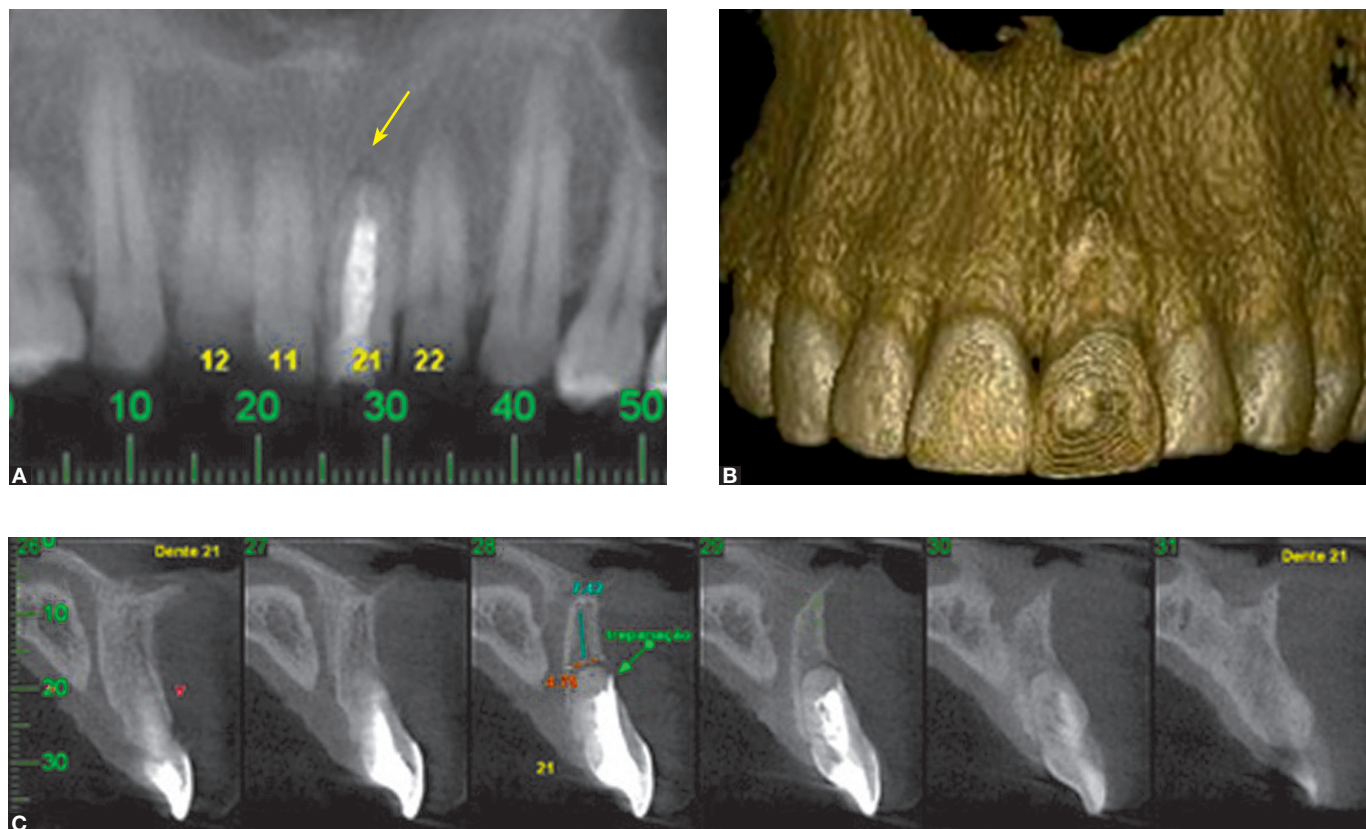


Figure 2. A) Panoramic reconstruction: Observe bone rarefaction in tooth #21 apex (yellow arrow). B) 3D reconstruction. C) Oblique reconstruction: Note root trepanation in slide 28.

Clinical case 3

Patient, 27 years of age, was referred for evaluation of the right central incisor which presented pain and recurrent fistula. During the clinical exam, swelling and sensitivity to touch were verified in the region in question. The patient was submitted to a cone beam computerized tomography exam of the maxilla, performed with the appliance GXCB-500 Powered by i-CAT® (Imaging Sciences, Hatfield, USA).

Bone rarefaction was observed at the apex of tooth #11 and a slightly hyperdense image on the mesial face of root. In the sagittal cut of tooth #11, the presence of perforation was identified, in addition to extravasation of the filling material in the middle third of the root (Fig 3). Due to the unfavorable prognosis, the tooth was extracted and the patient was referred for oral rehabilitation by means of an implant in the region.

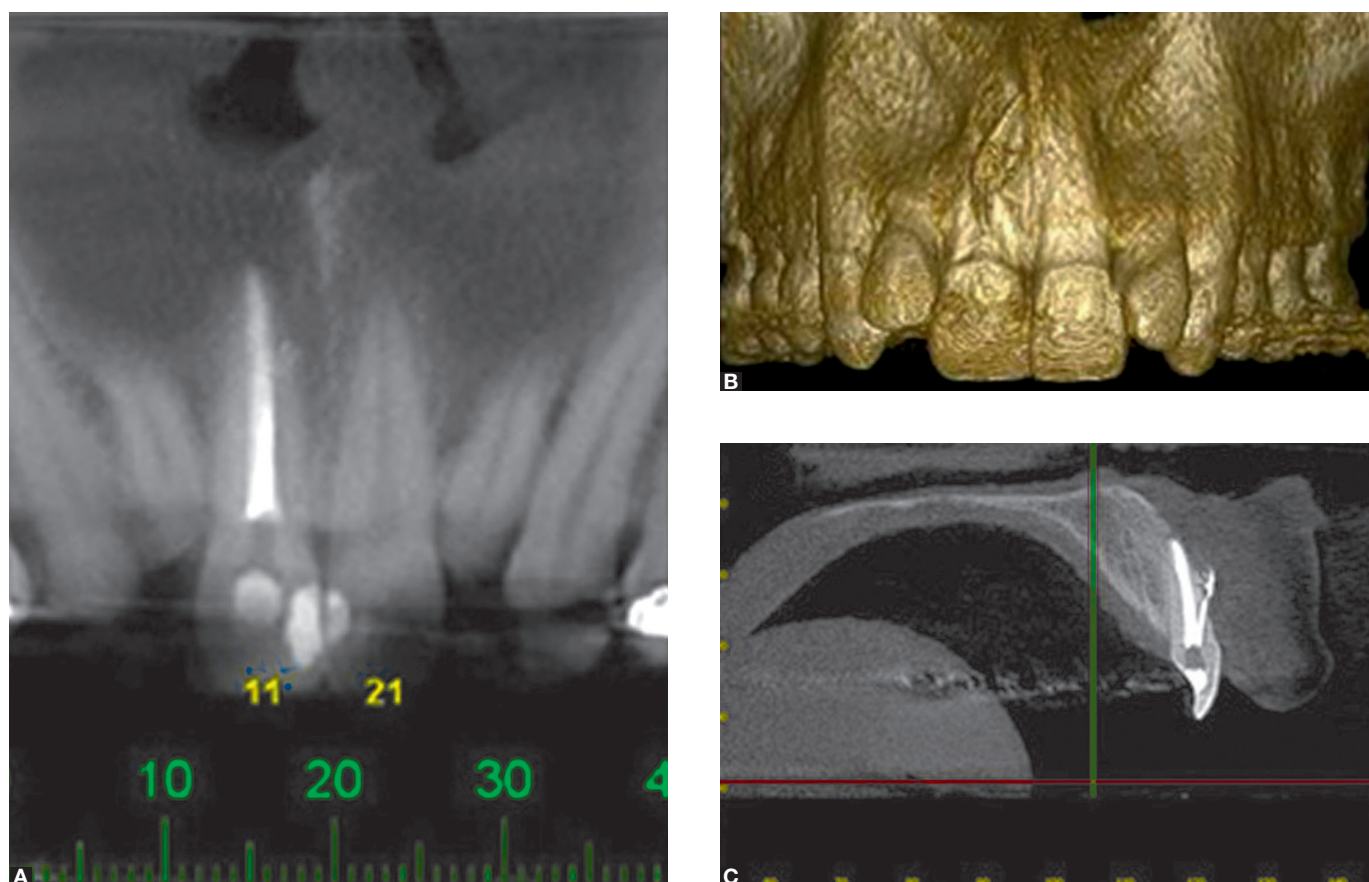


Figure 3. A) Note the bone rarefaction in the apex of tooth #11 in the panoramic reconstruction. B) 3D reconstruction: Observe tooth #11. C) Presence of trepanation in the radicular third of tooth #11 with leakage of the filling material in the sagittal reconstruction.

Discussion

Cases of root perforation are always harmful to the adjacent region to the tooth and are difficult to treat. In order to preserve the tooth, it is necessary to perform adequate treatment to correct the defect and achieve local conditions to maintain the health of the region.⁴

Root perforations are diagnosed by clinical symptoms such as edema, tooth mobility, fistula and sensitivity to percussion, and by imaging exams with periapical radiography and computerized tomography. These exams associated with well conducted anamnesis of the patient will provide a precise diagnosis.

According to the authors of some studies, periapical radiography imposes several limitations on interpretation due to the superimposition of structures and the image being two-dimensional.^{5,7,9,10} In the clinical cases described in this article, computerized tomography was used as a relevant exam in the

diagnosis, and provided precise information about the location of perforation. Panoramic reconstructions were made and the perforations were not visualized, as the defects found in the vestibular region were superimposed on the root, showing that in the majority of two-dimensional exams, depending on the region affected, it is not possible to observe this condition.

In 1981, Metzger¹ mentioned that the shape and direction of alveolar bone in relation to the root of the tooth and the shape of the root canal are essential characteristics for successful endodontic treatment. Therefore, computerized tomography can be mentioned as an important diagnostic imaging that provides information about the anatomic structures, helping with planning and performing endodontic treatment.

In 2011, D'Addazio et al⁷ conducted a study to diagnose different endodontic defects. As regards root perforations, periapical radiographs did not

identify any signs of perforation in 80% of the images evaluated and provided imprecise diagnoses in 20% of the cases. With cone beam computerized tomography all the alterations were identified and 20% were precise. The tomographic exam offered greater accuracy than periapical radiographs.

In their studies, in 2011, Bueno et al⁹ presented some considerations with regard to false interpretations of images obtained by means of cone beam computerized tomography due to metal artifacts. These may simulate endodontic defects and confuse the diagnosis of root perforation. The artifacts appear as dark strips producing errors of interpretation and may lead to disagreeable consequences in endodontic therapy. However, correct handling of images may minimize errors in diagnosis. Coronal, axial and sagittal images of 0.2 mm thick should be used (as was done in the clinical cases reported) because they provide precise information on the exact location of the point of communication between the root canals and periodontal space, frequently associated with hypodense areas, suggesting root

perforation. This method overcomes the limitations of periapical radiography, with the possibility of navigating the image, showing a dynamic visualization of images that previously were static. In the cases reported in this study, it was verified that computerized tomography enabled the diagnosis of root perforations in addition to helping with the preparation of clinical planning.

Conclusion

To make a definitive diagnosis of perforations is challenging, particularly due to the absence of pathognomic clinical signs and the limited capacity of periapical radiography to enable visualization of these perforations. Therefore, computerized tomography is a useful technology to the endodontist in the diagnosis and treatment of complex endodontic problems, as it allows tridimensional visualization of structures in different planes. Nevertheless, it is important to remember that the final diagnosis and choice of clinical therapy for root perforations must always be made in conjunction with the clinical findings.

References

1. Metzger Z, Shperling I. Iatrogenic perforation of the roots of restoration-covered teeth. *J Endod.* 1981 May;7(5):232-3.
2. Biggs JT, Benenati FW, Sabala CL. Treatment of iatrogenic root perforations with associated osseous lesions. *J Endod.* 1988 Dec;14(12):620-4.
3. Behnia A, Strassler HE, Campbell R. Repairing iatrogenic root perforations. *J Am Dent Assoc.* 2000 Feb;131(2):196-201.
4. Alves DF, Gomes FB, Sayão SM, Mourato AP. Tratamento clínico cirúrgico de perfuração do canal radicular com MTA – caso clínico. *Int J Dent.* 2005;4(1):37-40.
5. Eleftheriadis GI, Lambrianidis TP. Technical quality of root canal treatment and detection of iatrogenic errors in an undergraduate dental clinic. *Int Endod J.* 2005 Oct;38(10):725-34.
6. Young GR. Contemporary management of lateral root perforation diagnosed with the aid of dental computed tomography. *Aust Endod J.* 2007 Dec;33(3):112-8.
7. D'Addazio PSS, Campos CN, Ozcan M, Teixeira HGC, Passoni RM, Carvalho ACP. A comparative study between cone-beam computed tomography and periapical radiographs in the diagnosis of simulated endodontic complications. *Int Endod J.* 2011 Mar;44(3):218-24.
8. Patel S, Dawood A, Ford TP, Whaites E. The potential applications of cone beam computed tomography in the management of endodontic problems. *Int Endod J.* 2007 Oct;40(10):818-30.
9. Bueno MR, Estrela C, Figueiredo JA, Azevedo BC. Map-reading strategy to diagnose root perforations near metallic intracanal posts by using cone beam computed tomography. *J Endod.* 2011 Jan;37(1):85-90.
10. Shemesh H, Cristescu RC, Wesselink PR, Wu MK. The use of cone-beam computed tomography and digital periapical radiographs to diagnose root perforations. *J Endod.* 2011 Apr;37(4):513-6.