

Accidental swallowing of a Protaper® file during root canal treatment

Simony Hidee Hamoy **KATAOKA**¹

Flávio **MOREIRA**²

Lisandro de **BOUTTEVILLE**³

Celso Luiz **CALDEIRA**⁴

Oscar Faciola **PESSOA**⁵

ABSTRACT

Objective: To demonstrate to the general practitioner the importance of the use of rubber dam during endodontic treatment through a case report where was described the monitoring employed with a patient who accidentally ingested a rotary file S1 ProTaper® (Dentsply Maillefer, Switzerland) during the root canal preparation. **Case report:** A 28 years-old patient underwent root canal treatment without rubber dam and during the root canal therapy, swallowed a ProTaper® S1. He was accompanied to the hospital where, at first, was performed a gastrointestinal

high endoscopy and a CT scan. He remained asymptomatic after these two early interventions, was monitored over four days, through X-rays of chest and abdomen, until the foreign body was eliminated. **Conclusion:** General practitioners who do endodontics should be aware of the risks involved in swallowing and/or accidental aspiration of foreign bodies during endodontic treatment, and know how to avoid this problem by adopting a simple measure, the use of rubber dam.

Keywords: Deglutition. Rubber dams. Root canal preparation.

How to cite this article: Kataoka SHH, Moreira F, Boutteville L, Caldeira CL, Pessoa OF. Accidental swallowing of a Protaper® file during root canal treatment. *Dental Press Endod.* 2011 July-Sept;1(2):89-93.

» The authors report no commercial, proprietary, or financial interest in the products or companies described in this article.

¹PhD Candidate, Discipline of Endodontics, Department of Esthetic Dentistry, School of Dentistry, Universidade de São Paulo, São Paulo, SP, Brazil.

²Discipline of Endodontics, School of Dentistry, Centro Universitário do Pará, Belém, PA, Brazil.

³Discipline of Orthodontics, School of Dentistry, Centro Universitário do Pará, Belém, PA, Brazil.

⁴Professor Doutor Discipline of Endodontics, Department of Esthetic Dentistry, School of Dentistry, Universidade de São Paulo, São Paulo, SP, Brazil.

⁵Professor Doutor Discipline of Endodontics, School of Dentistry, Centro Universitário do Pará, Belém, PA, Brazil.

Received: July 7, 2011. Accepted: July 20, 2011.

Contact address: Oscar Faciola Pessoa
Travessa 9 de Janeiro, 927 – 66.065-510 – São Braz – Belém/PA - Brazil
E-mail: ofpesso@cesupa.br

Introduction

The placement of the rubber dam is considered the first step of security before endodontic procedures.¹ During the management of patients at the time of clinical procedures, the use of rubber dam serves to prevent ingestion or inhalation of the irrigation syringes, isolation clamps, drills and endodontic files.²

Currently rare, the ingestion of endodontic instruments during treatment can result in clinical complications and, therefore, even in legal proceedings.³

Grossman⁴ noted that 87% of foreign bodies passed to the digestive tract. In contrast, 13% were aspirated into the respiratory tract.

More serious complications caused by ingestion of instruments include impaction, obstruction or perforation of the digestive or respiratory tract.⁵ However, 1% or less requires surgical intervention.⁶

In this case reported, the patient accidentally swallowed an endodontic file during root canal treatment of the lower left first molar without a rubber dam.

Case description

Male patient, 28 years-old, submitted to endodontic treatment of left mandibular first molar, without the use of absolute isolation, swallowed a Protaper® S1 file, 25 mm in length. After referral to the Emergency Room, chest X-rays were performed 24 hours after the accident and medical recommendation was implemented. 12 hours after the radiographies, a computed tomography (CT) was performed, suggesting that the instrument was found in his stomach (Fig 1). By the gastroenterologist advice, the patient underwent an upper gastrointestinal videoendoscopy in order to remove the instrument by laparoscopy, but it was unsuccessful. The patient was then referred to the endoscopist, who warned about the fact of a possible overlap of the bowel, creating a false impression of a foreign body in the stomach. It was then requested an abdominal radiography, which was performed 2 hours after the laparoscopic surgery, noting that the instrument was located close to the angle of the cervix or spleen (Fig 2). The medical advice

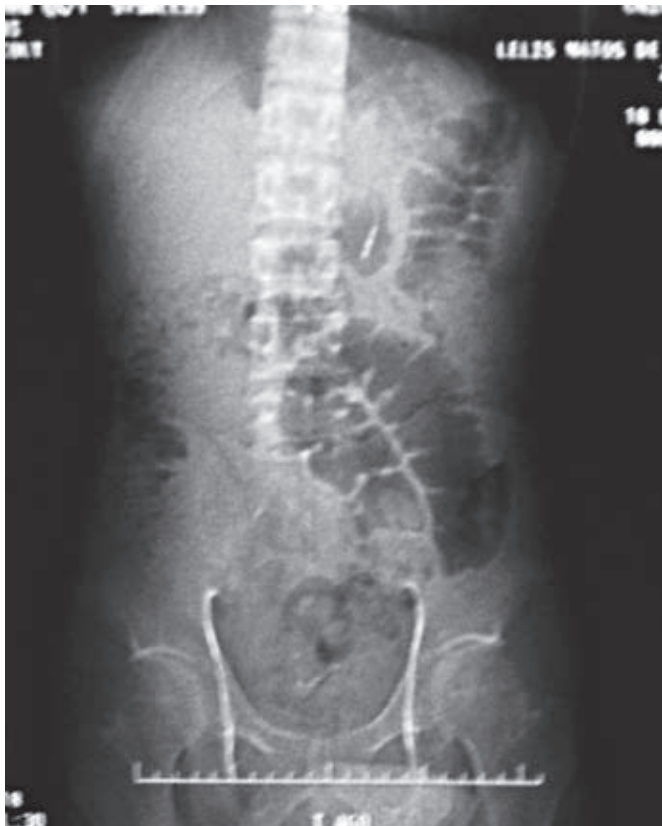

Figure 1. Stomach computer tomography.

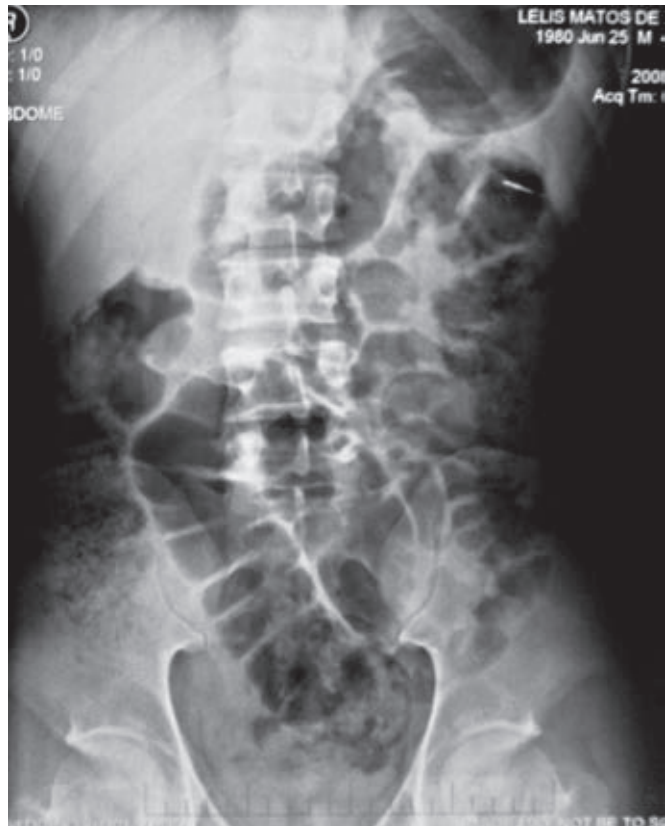

Figure 2. Abdominal X-ray showing the S1 file located close to the angle of the spleen.

was to perform radiographic monitoring every 12 hours, without food restrictions, discarding the need for hospitalization. After 15 hours the instrument was in the large intestine descending colon (Fig 3). Radiographs of the 2 subsequent days showed that the instrument was located in the pubis and rectum, respectively (Figs 4 and 5). The foreign body was expelled naturally by the patient 72 hours after the last radiography, and he did not want to do other radiography to confirm the file elimination.

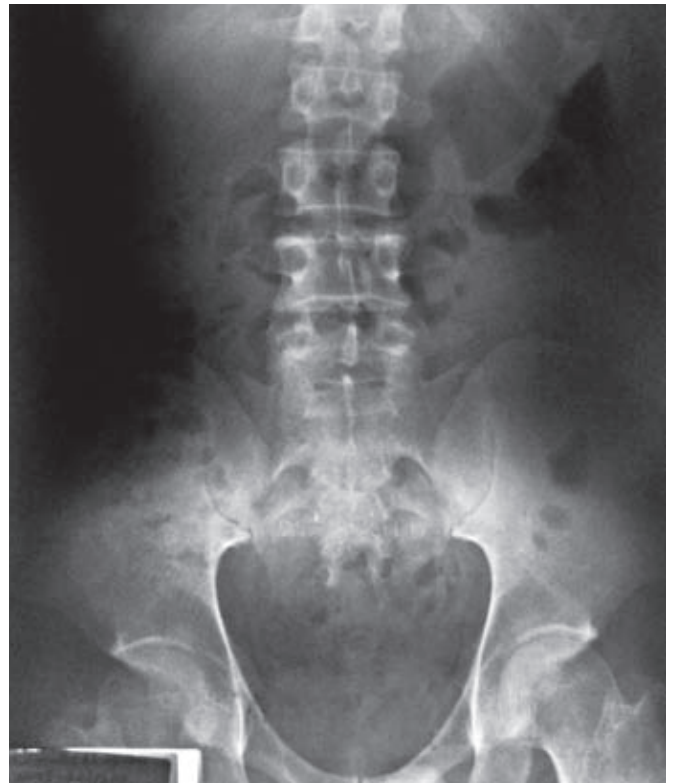

Figure 3. Abdominal X-ray in the large intestine descending colon.

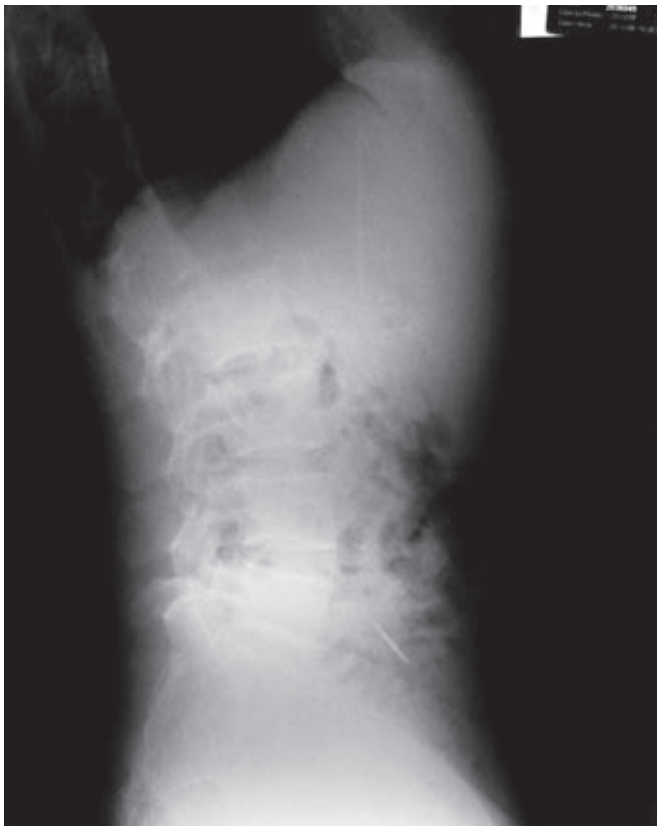


Figure 4. Abdominal X-ray, S1 file in the pubis (lateral view).

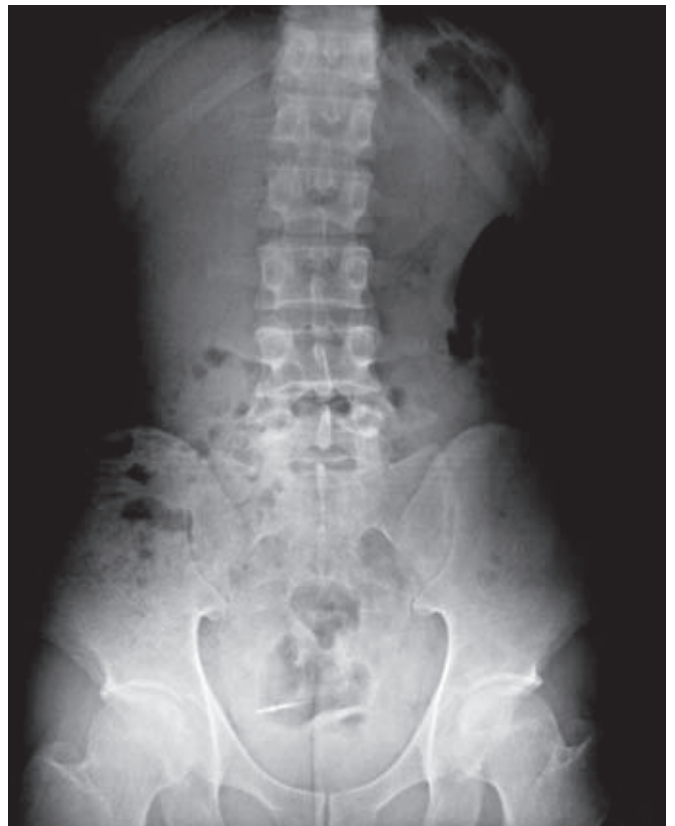

Figure 5. Abdominal X-ray, S1 file in the pubis.

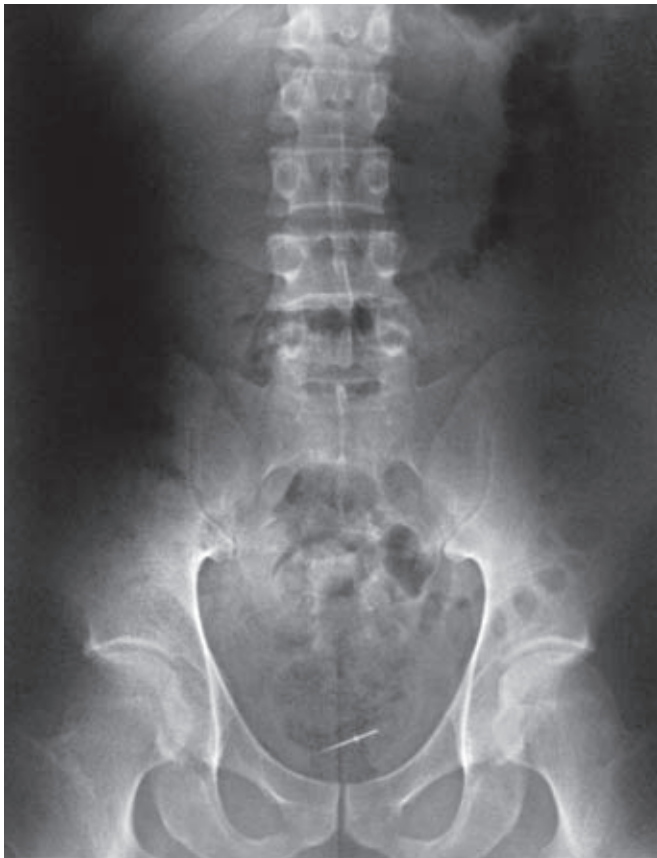

Figure 6. Abdominal X-ray, S1 file in the rectum.

Discussion

Security during treatment is an important component, and the use of rubber dam is undoubtedly essential to avoid accidents. Furthermore, the isolation of the tooth to be treated has many purposes, including the patient protection from aspiration or swallowing of

instruments, increased visibility and also prevention of the root canal system against contamination.⁷ When the instrument is lost in the oropharynx, it is immediately essential to determine its location and further penetration (into the respiratory or digestive tract), as when foreign bodies aspirated or ingested are not diagnosed or treated properly, serious complications can occur.

The examination and radiographic monitoring is mandatory for the differential diagnosis of the location, nature and size of the foreign body. Radiolucent objects often require endoscopy, computed tomography or simply physical monitoring.⁸ In this case, the radiopacity of the instrument allowed to follow its path through the abdominal X-ray without being necessary to submit the patient to the supine position. Because of the shape and sharp edge of the endodontic files, they present a high risk of perforation.⁹ However, usually the files that penetrate into the gastrointestinal tract are asymptomatic and atraumatic, and on average they are expelled within 4 days to 2 weeks.¹⁰ In this case report, the patient was also asymptomatic and the file expulsion time was short. The file position over the gastrointestinal tract, from the stomach until the rectal evacuation, did not result in complications.

Conclusion

Dentists should be aware of the risks involving the accidental swallowing and aspiration of foreign bodies of dental origin during endodontic treatment and this type of accident can be avoided through the use of rubber dam.

References

1. Fishelberg G, Hook D. Patient safety during endodontic therapy using current technology: a case report. *J Endod.* 2003;29(10):683-4.
2. Lambrianidis T, Beltes P. Accidental swallowing of endodontic instruments. *Endod Dent Traumatol.* 1996;12(6):301-4.
3. Kuo SC, Chen YL. Accidental swallowing of an endodontic file. *Int Endod J.* 2008;41(7):617-22.
4. Grossman LI. Prevention in endodontic practice. *J Am Dent Assoc.* 1971;82(2):395-6.
5. Reilly J, Thompson J, MacArthur C, Pransky S, Beste D, Smith M, et al. Pediatric aerodigestive foreign body injuries are complications related to timeliness of diagnosis. *Laryngoscope* 1997;107(1):7-20.
6. Webb WA. Management of foreign bodies of the upper gastrointestinal tract. *Gastroenterology.* 1988 Jan; 94(1):204-16.
7. Cohen S, Burns R. *Pathways of the pulp.* 7th ed. St. Louis: CV Mosby; 1998.
8. Samarasam I, Chandran S, Shukla V, Mathew G. A missing denture's misadventure! *Dis Esophagus.* 2006;19(1):53-5.
9. Rosenberg R. Hazards of endodontics without the rubber dam: Reports of three cases. *Ann Dent.* 1965;24:29-32.
10. Lyons MF II, Tsuchida AM. Foreign bodies of the gastrointestinal tract. *Med Clin North Am.* 1993;77:1101-14.