

Filling of a C-shaped canal using the Epiphany System and McSpadden compactors

André Luiz da Costa **MICHELOTTO**¹

Joel Alves da **SILVA JR.**²

Marili Doro Andrade **DEONIZIO**³

ABSTRACT

The aim of this paper was to report two cases of lower second molars, presenting C-shaped root canal systems. The procedures for root canal treatment were described and discussed along with those presented in the literature. Root canal

preparation was performed using a reciprocating system, and the root canal filling was performed using the Epiphany system associated with the McSpadden compactor.

Keywords: Root canal filling. C-shaped canal. Endodontics.

How to cite this article: Michelotto ALC, Silva Jr. JA, Deonizio MDA. Filling of a C-shaped canal using the Epiphany System and McSpadden compactors. *Dental Press Endod.* 2011 July-Sept;1(2):64-9.

» The authors report no commercial, proprietary, or financial interest in the products or companies described in this article.

¹Endodontics Adjunct Professor, UTP. Endodontics Specialization Professor, UTP/São Leopoldo Mandic - Curitiba. PhD in Endodontics, FOU SP, Brazil.

²Endodontics Specialization Professor, UNINGÁ - Criciúma, Brazil.

³Endodontics Adjunct Professor, UFPR. Endodontics Specialization Professor, UFPR. PhD in Endodontics, FOU SP - Brazil.

Received: July 13, 2011. Accepted: July 22, 2011.

Contact address: André Luiz da Costa Michelotto
Rua Manoel Eufrásio, 395 - 80.030-440 - Curitiba / PR, Brazil
E-mail: amichelotto@gmail.com

Introduction

Knowledge of internal anatomy, and possible variations that can occur in the root canal system, is essential to the success of endodontic treatment. Some dental groups may present a C configuration in the cross section of the root. Cooke and Cox¹ first described these cases. The literature shows variation in the prevalence of C-shaped root canals, depending upon the population studied, from 2.7% to 45.5%.¹⁻⁷ The difficulties in diagnosis, instrumentation and filling of root canals with this variation have been reported.^{1,8-12} The aim of this paper was to present two clinical cases with C-shaped root canals, filled using the epiaphany system and the McSpadden technique.

Case report 1

A 32-year-old female patient presented with spontaneous pain, exacerbated by cold and heat, in the lower right second molar. Clinical examination revealed extensive caries; radiographic examination revealed fused roots (Fig 1A). Upon completing the access cavity, the pulp chamber floor appeared to be in a C-shaped configuration (Fig 1B). After exploration, the distal, mesiolingual and mesiobuccal canals, the latter located between the first two, were found. After the clinical exam and the working length radiographic exam (Fig 1C), it was found that the root canals ended in the same foramen.

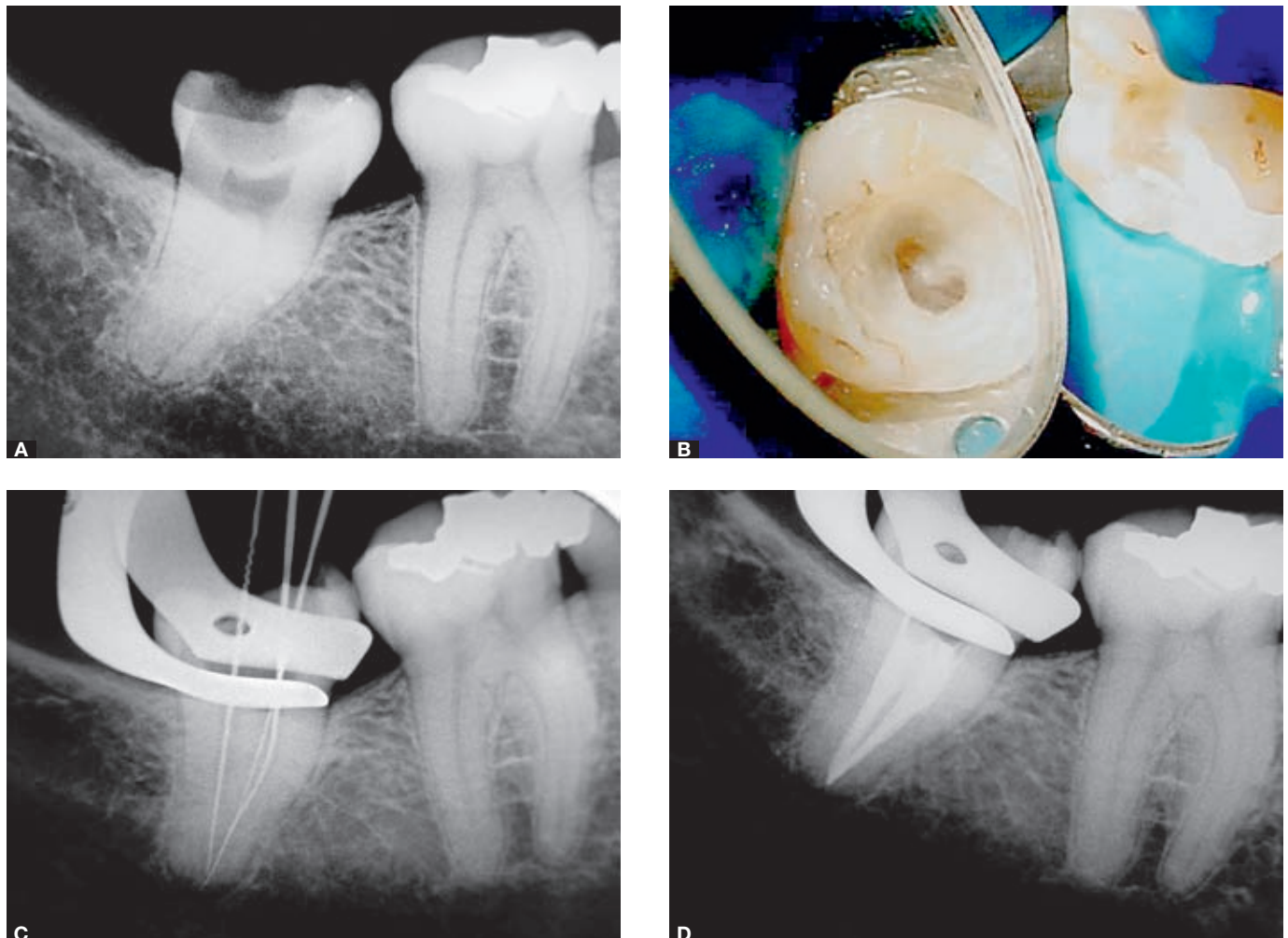


Figure 1. A) Preoperative radiograph. B) Image showing the C-Shaped canal. C) Working length radiograph. D) Final radiograph.

Case report 2

A 56-year-old female patient presented with large cavities, communicating with the pulp chamber, in the lower right second molar. The tooth was asymptomatic, and apical periodontitis (Fig 2A) was observed following radiographic examination. After removing the metal crown and caries, the floor of the pulp chamber presented a C-shaped configuration. After exploration, the distal, mesiolingual and mesiobuccal root canals, which are the most central, were located. The working length radiograph revealed the presence of a foramen for each root canal (Fig 2B). During instrumentation, there was an isthmus revealed from the entry to the region near the apical third, between the mesial canals.

In both cases, the preparation and filling of the root canals were performed the same way. After exploration with #10 and #15 K-files; #1, #2 and #3 Gates-Glidden drills (Maillefer, Ballaigues, Switzerland) were used, aiming for a straight access to the root canals. The Root ZX apex locator (Morita, Kyoto, Japan) established the working length 1.0 mm from the apex. The root canals were prepared using the crown-down technique¹³ with a reciprocating system (Kavo, Biberach, Germany) and Flexo-file files (Maillefer). For both cases, the apical thirds of the distal canals were prepared using a #40 instrument, and of the mesial canals using a #35.

Throughout the preparation, the canals were rinsed with 2.5% sodium hypochlorite solution. Final

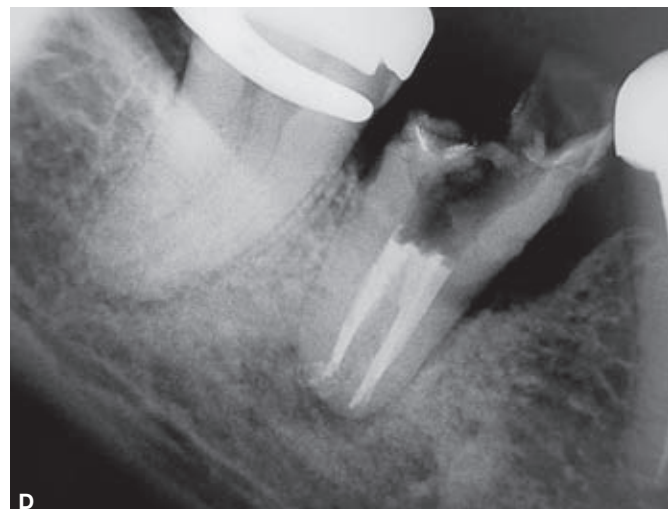
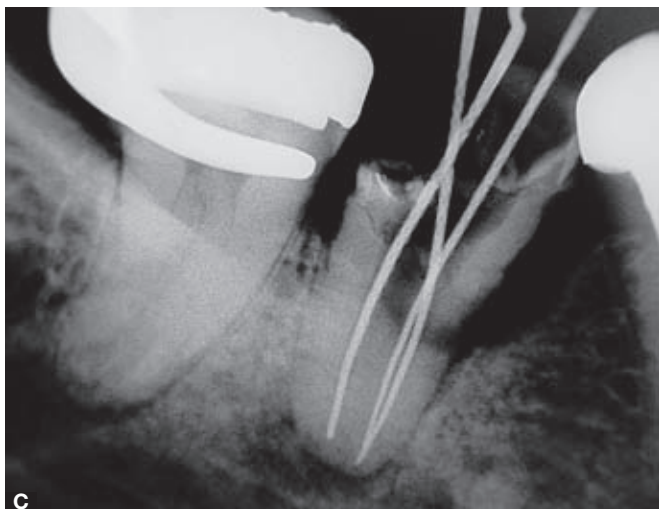
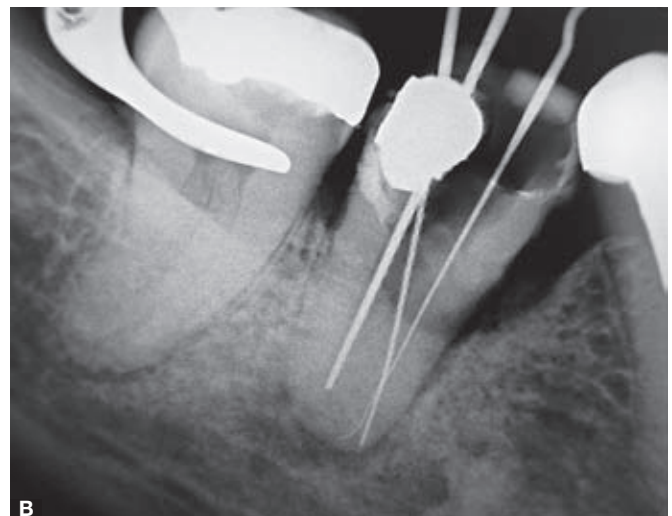
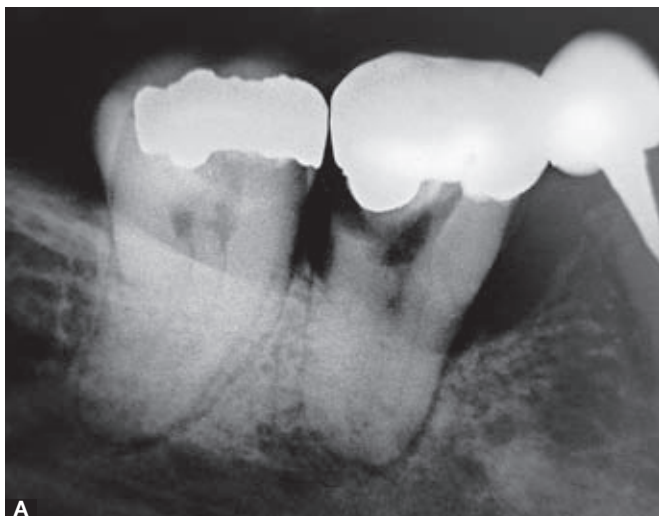

Figure 2. A) Preoperative radiograph. B) Odontometry radiograph. C) After instrumentation. D) Final radiograph.

irrigation was performed using a 17% EDTA solution and a saline solution.

For filling, the Epiphany system (Pentron, Wallingford, USA) and McSpadden compactors (Maillefer, Ballaigues, Switzerland) were used. The primer was applied to the walls of the canals to the working length using sterile absorbent paper points, and the excess was removed. Resilon master cones and an accessory cone M were selected, corresponding to the diameter of the last file to reach the working length of each root canal. Using the master cone, the sealer was inserted into the root canals, repeating until the final part of the cone was sealed.

The cones were kept within the canals and an accessory cone M was introduced into each root canal. A #50 McSpadden compactor was introduced using an in-and-out motion, oscillating a few millimeters. The filling material was plasticized and the root canal system was filled. The depth of compaction was determined by the anatomic conditions and took only a few seconds.¹⁴ After plasticization, vertical condensation and polymerization of the coronal portion of the filling was performed for 40 seconds.

Discussion

Knowledge of internal dental anatomy and variations is very important for endodontic therapy. Among the variations, root canal systems with C-shaped configurations may be noted. Some authors have shown the prevalence of these cases among the Asiatic,^{6,15,16} Lebanese⁴ and Saudi Arabian⁵ populations; although, in the reported cases, the patients were Caucasian and European.

The literature reports the higher frequency cases in the lower second molars, although occurrences in first molars, lower molars and premolars were also reported.^{1,3,8,9,11,17-21} Cook and Cox¹ reported the difficulty of radiographic diagnosis of C-shaped root canals. However, Haddad et al⁴ observed radiographic features common to almost all cases: The presence of fused roots, or very close roots; a large distal canal; a narrow mesial canal; and lack of clarity in the image of the third mesial canal. These characteristics were also found in the initial radiographs of presented cases, with the exception of the image of a large distal canal, although a clinically proven, large-diameter canal has also been found. Results from the studies by

Fan et al²² and Jung et al²³ suggest that it is possible to identify these cases in the radiographic exam by taking additional radiographs with 20 degrees of angulation in the mesial or distal directions. However, the identification of a C-shaped canal can be made only after access cavity and observing the pulp chamber floor. In these cases, endodontic treatment may be difficult due to the complexity of the anatomy. Melton et al²⁴ showed that the C-shaped configuration can change at different levels in the same tooth. Marroquin et al²⁵ and Green²⁶ found high incidences of irregularities in these cases, such as lateral or accessory canals and apical deltas, suggesting that cleaning, shaping and filling can present challenges. Cheung et al²⁷ showed that most teeth had two or three main canals, and a few specimens had four or more. Accessory canals, inter-communication canals and apical deltas ranged from 11% to 41% of cases. Bolger et al⁸ reported a case of a first molar with a C-shaped canal with four canals and four foramina. Marroquin et al²⁵ showed an incidence of 69% of teeth with one foramen; of only 31% with two foramina in the mesial root; and, of 87% and 13%, respectively, in the distal roots of mandibular second molars. Rocha et al²⁸ showed an incidence of 61% of teeth with one foramen; of 38.8% with two foramina in the mesial root; and, 97.4% and 2.6%, respectively, in the distal roots of mandibular second molars. Manning¹⁶ showed that most C-shaped canals had three main canals, all with lateral canals and a high incidence of apical deltas. The reported cases had three root canals: one distal and two mesial. The first case suggests the presence of one foramen for the three root canals (Fig 1C). In the second case, the radiography of the working length shows the presence of one foramen for the distal canal and separated foramina for the mesial canals (Fig 2B). However, after preparation of the mesial canals, it was not possible to maintain the instruments at the same time on the same working length established initially. This shows that the canals met each other, 1.0 mm from the apex (Fig 2C).

Fan et al²⁹ studied 54 extracted teeth with C-shaped root canals, collected from the Chinese population, using computed tomography. They reported that the average length of roots from the dentin-enamel junction to the root apex was 12.1 mm, ranging from 9.5 to 16.5 mm. The beginning of the bifurcation of the

canals occurred 2.0 mm from the apex in most cases, reaching a maximum of 4.0 mm in all cases. This emphasized the presence of the isthmus connecting the mesial and distal canals, which was more pronounced in the cervical third. This makes it difficult to visualize the entry of the canals, depending on the depth of the pulp chamber. The mesial and distal canals could be instrumented normally; but, the isthmus should be slightly larger, depending on the thickness, to avoid perforation.^{30,31} Therefore, irrigation and intra-canal medication is fundamental, especially in mortified pulp treatment. Preparation of the root canals with the reciprocating system provided instrumentation of most of the walls of the canal system, allowing use of the instrument in the region of the isthmus.

The filling of this region can be facilitated with a technique that promotes the plasticization of the filling material, although good results were reported with the lateral condensation technique.^{9,20,31,32} In both cases presented, the filling was performed using the Epiphany system and McSpadden technique, highlighting the filling of the isthmus at the cervical third (Figs 1D and 2D). Michelotto et al³³ found good results for the quality of the filling and the flow of filling material using this combination; Verissimo et al³⁴ presented good results in terms of infiltration.

The cases reported show that, by combining knowledge of anatomic variations with a treatment protocol, the professional can achieve good clinical and radiological results in these situations.

References

- Cooke HG, Cox FL. C-shaped canal configurations in mandibular molars. *J Am Dent Assoc.* 1979;99(5):836-9.
- Yang ZP, Yang SF, Lin YC, Shay JC, Chi CY. C-shaped root canals in mandibular second molars in a Chinese population. *Endod Dent Traumatol.* 1988;4:160-63.
- Weine FS. The C-shaped mandibular second molar: incidence and other considerations. *J Endod.* 1998;24:372-5.
- Haddad GY, Nehme WB, Ounsi HF. Diagnosis, classification, and frequency of C-shaped canals in mandibular second molars in the Lebanese population. *J Endod.* 1999;25(4):268-71.
- Al-Fouzan KS. C-shaped root canals in mandibular second molars in a Saudi Arabian population. *Int Endod J.* 2002;35(6):499-504.
- Seo MS, Park DS. C-shaped root canals of mandibular second molars in a Korean population: clinical observation and in vitro analysis. *Int Endod J.* 2004;37(2):139-44.
- Jin GC, Lee SJ, Roh BD. Anatomical study of C-shaped canals in mandibular second molars by analysis of computed tomography. *J Endod.* 2006;32(1):10-3.
- Bolger WL, Schindler WG. A mandibular first molar with a C-shaped root configuration. *J Endod.* 1988;14:515-9.
- Walid N. The use of two pluggers for the obturation of an uncommon C-shaped canal. *J Endod.* 2000;26(7):422-4.
- Dankner E, Friedman S, Stabholz A. Bilateral C shape configuration in maxillary first molars. *J Endod.* 1990;16(12):601-3.
- Yilmaz Z, Tuncel B, Serper A, Calt S. C-shaped root canal in a maxillary first molar: a case report. *Int Endod J.* 2006;39(2):162-6.
- Cheung LHM, Cheung GSP. Evaluation of a rotary instrumentation method for C-shaped canals with micro-computed tomography. *J Endod.* 2008;34:1233-38.
- Batista A, Sydney GS. Preparo do canal curvo. *JBE: J Bras Endo/Perio.* 2000;1(1):43-51.
- Michelotto ALC, Araki AT, Moura-Netto C, Akisue E, Moura AAM, Sydney GB. In vitro analysis of thermocompaction time and gutta-percha type on quality of main canal and laterals canals filling. *Braz Oral Res.* 2010;24(3):290-5.
- Walker RT. Root form and canal anatomy of mandibular second molars in southern Chinese population. *J Endod.* 1988;14(7):325-9.
- Manning SA. Root canal anatomy of mandibular second molars. Part II. C-shaped canals. *Int Endod J.* 1990;23(1):40-5.
- Newton CW, McDonald S. A C-shaped canal configuration in a maxillary first molar. *J Endod.* 1984;10:397-9.
- Cleghorn BM, Christie WH, Dong CC. Root and root canal morphology of the human permanent maxillary first molar: a literature review. *J Endod.* 2006;32(9):813-21.
- Lyroudia K, Samakovitis G, Pitas I, Lambrianidis T, Molyvdas I, Mikrogeorgis G. 3D reconstruction of two C-shape mandibular molars. *J Endod.* 1997;23(2):101-4.
- De Moor RJG. C-shaped root canal configuration in maxillary first molars. *Int Endod J.* 2002;35:200-8.
- Lu TY, Yang SF, Pai SF. Complicated root canal morphology of mandibular first premolar in a Chinese population using the cross section method. *J Endod.* 2006;32(10):932-6.
- Fan B, Cheung GSP, Fan M, Gutmann JL, Fan W. C-shaped canal system in mandibular second molars: part II – radiographic features. *J Endod.* 2004;30:904-8.
- Jung HJ, Lee SS, Huh KH, Yi WJ, Heo MS, Choi SC. Predicting the configuration of a C-shaped canal system from panoramic radiographs. *Oral Surg Oral Med Oral Pathol Oral Radiol Endod.* 2010;109(1):e37-41.
- Melton DC, Krell KV, Fuller MW. Anatomical and histological features of C-shaped canals in mandibular second molars. *J Endod.* 1991;17(8):384-8.
- Marroquin BB, El-Sayed MA, Willershausen-Zonnchen B. Morphology of the physiological foramen: I. Maxillary and mandibular molars. *J Endod.* 2004;30(5):321-8.
- Green D. A stereo-binocular microscopic study of the root apices and surrounding areas of 100 mandibular molars; preliminary study. *Oral Surg Oral Med Oral Pathol.* 1955;8(12):1298-304.
- Cheung GSP, Yang J, Fan B. Morphometric study of the apical anatomy of C-shaped root canal systems in mandibular second molars. *Int Endod J.* 2007;40(4):239-46.
- Rocha LF, Souza Neto MD, Fidel SR, da Costa WF, Pécora JD. External and internal anatomy of mandibular molars. *Braz Dent J.* 1996;7(1):33-40.
- Fan B, Cheung GSP, Fan M, Gutmann JL, Bian Z. C-shaped canal system in mandibular second molars: part I – anatomical features. *J Endod.* 2004;30(12):899-903.
- Chai WL, Thong YL. Cross-sectional morphology and minimum canal wall widths in C-shaped roots of mandibular molars. *J Endod.* 2004;30(7):509-12.
- Jafarzadeh H, Wu Y. The C-shaped root canal configuration: a review. *J Endod.* 2007;33(5):517-23.
- Liewehr FR, Kulild JC, Primack PD. Obturation of a C-shaped canal using an improved method of warm lateral condensation. *J Endod.* 1993;19(9):474-7.
- Michelotto ALC, Moura-Netto C, Araki AT, Akisue E, Chavez JERF, Moura AAM, et al. Estudo da penetração do sistema obturador Real Seal associado a técnicas termoplásticas em canais laterais simulados. *Braz Oral Res.* 2006;20 Suppl:159.
- Verissimo DM, Vale MS, Monteiro AJ. Comparison of apical leakage between canals filled with gutta-percha/AH plus and resilon/Epiphany system, when submitted to two filling techniques. *J Endod.* 2007;33(3):291-4.