

Root canal filling with calcium hydroxide paste using Lentulo spiral at different speeds

Marili Doro **DEONÍZIO**, DDS, PhD¹

Gilson Blitzkow **SYDNEY**, DDS, PhD¹

Antonio **BATISTA**, DDS¹

Carlos **ESTRELA**, DDS, PhD²

ABSTRACT

Objective: This study analyzed the effectiveness of filling the root canal with calcium hydroxide paste using the Lentulo spiral at different speeds. **Methods:** Thirty mandibular premolars after root canal preparation were divided in three groups. Calcium hydroxide paste was inserted in the root canals with a Lentulo spiral at 5,000 rpm (G1), 10,000 rpm (G2) and 15,000 rpm (G3). The optical density was determined by the use of the digital radiography system Kodak Dental RGV-5000. **Results:** The highest optical density obtained in the apical third was in G3 and in the middle and

cervical third in G1. Statistical difference (Kruskal-Wallis - Anova) was observed ($p < 0.05$) between G1 and G3 in the apical third and G1 and G2 in the middle third. No difference was observed in the cervical third ($p > 0.05$). **Conclusion:** Different speeds are necessary for the correct filling of the root canal with calcium hydroxide paste. The 15,000 rpm speed was more effective in filling the apical third and 5,000 rpm speed was more effective in filling the cervical and middle thirds.

Keywords: Calcium hydroxide. Intracanal dressing. Root canal filling.

Deonizio MD, Sydney GB, Batista A, Estrela C. Root canal filling with calcium hydroxide paste using Lentulo spiral at different speeds. *Dental Press Endod.* 2011 apr-june;1(1):58-63.

¹Department of Endodontics, School of Dentistry, Federal University of Paraná, Curitiba, PR, Brazil.

²Department of Endodontics, School of Dentistry, Federal University of Goiás, Goiânia, GO, Brazil.

Received: January 2011 / Accepted: February 2011

Correspondence address: Gilson Blitzkow Sydney
Federal University of Paraná - Department of Endodontics
Rua da Glória 314, suite 23 - Zip code: 80.030060 - Curitiba/PR, Brazil
E-mail: gsydney@bbs2.sul.com.

Introduction

The success of endodontic treatment is related to different factors like correct cleaning and shaping and sanitization of the root canals.¹ Biomechanical preparation using instruments and irrigating solutions offers a way to combat the endodontic microbiota. In this way, intracanal dressing increases the power of the sanitization process.^{2,3}

Calcium hydroxide is, currently, the most used intracanal dressing, due to its physical and chemical properties. It has a high pH, antibacterial activity, acts in the degradation of bacterial lipopolysaccharides, induces healing through the formation of hard tissue, and controls radicular resorption.^{3,4,5,6}

As ionic calcium hydroxide dissociation occurs, the paste quantity to be placed within the root canal must be enough to supply hydroxyl and calcium ions over a period of time necessary for sanitization of the root canal system.^{4,7,8,9} Its effectiveness is dependent on the direct action between the paste and remaining microorganisms in the dentinal tubules.^{10,11} To reach this goal the root canal must be homogeneously and completely filled with the paste showing a tri-dimensionally dense x-ray image.^{6,8} Many times, ineffectively of calcium hydroxide can be explained by the manner in which it is placed, ie, the canals are not filled in the middle and apical thirds.⁹

In general, its insertion is performed by using instruments and endodontic materials, such as K-files, reamers, absorbent paper points, gutta-percha cones, amalgam carriers, McSpadden compactors, Lentulo spirals, ultrasonic and sonic files, ML syringe (SS White), and 27G long needles.^{3,4,5}

Cvek et al¹² proposed the use of an injection syringe or Lentulo spiral aided by lateral condensation. Weber et al¹³ suggested the use of a plastic transporter to drive the paste into the root canal followed by an effective vertical condensation. To Anthony and Senia¹⁴ the ideal way of calcium hydroxide filling is using the Lentulo spiral. Leonardo¹⁵ recommended the use of a special syringe with a long G-27 needle in the Calen system. Sigurdsson et al¹⁶ comparing the Lentulo spiral, endodontic file and syringe, pointed to the first, the best results accompanied by others authors.^{12,14} However, these findings have not been unanimous, and empty spaces have been identified in some studies.^{3,17,18} Estrela et al³ analyzing the placement of

calcium hydroxide in dog's teeth obtained the lowest number of empty spaces when the paste was inserted using a K-file, absorbent paper points and vertical pluggers, followed by the Lentulo spiral. Torres et al¹⁹ concluded that the radiodensity of the paste in curved plastic resin block canals was significantly greater using a Lentulo spiral only technique.

But, there are two critical points with the Lentulo spiral filling: the speed and the paste quantity inserted at each time. Different speeds have not yet been studied. In the methodology used by Deveaux et al¹⁸ the speed of 500 rpm was referred to. However, Rahde et al²⁰ and Caliskan et al²¹ only refer to low and moderate speeds, without specifying it.

The aim of this study was to verify the efficacy of calcium hydroxide filling with the Lentulo spiral at different speeds.

Material and Methods

Thirty lower premolars from the tooth bank of the Federal University of Paraná Dentistry School — by authorization of the Research Ethics Committee of the Health Sciences Sector – CEP/SD registration number 584.121.08.07; CAAE research protocol: 2407.0.000.091-08 — were selected for this study. The teeth were classified by an average length of 20 mm and the presence of a single root canal, confirmed through a mesiodistal and buccolingual radiography. The crown was maintained in order to reproduce the clinical conditions.

Access was performed using a spherical diamond-tipped high-speed drill n°. 1014 (KG Sorensen) and completed with n° 3205 (KG Sorensen). The working length was determined 1 mm from the anatomic apex, maintaining patency with a #10 K-file

Root canal preparation was performed in a crown-down technique aided by a reciprocating angle TEP 4R-NSK. Teeth were instrumented to a # 50 master apical file 1 mm from the anatomic apex. The canals were irrigated with 1% sodium hypochlorite followed by 17% EDTA-T witch was left in place for 3 minutes to remove smear layer, followed by a final flush with sodium hypochlorite. The foramen was coated with a small piece of wax to prevent calcium hydroxide extrusion.

The specimens were randomly divided into 3 experimental groups. Calcium hydroxide paste was prepared for each tooth by mixing 1 g of calcium

hydroxide P.A. (Merck Kgaa) lot 1020471000 and 0,015 g of barium sulphate P.A. (Alphatec Química Fina: analytic reagent) lot 15559, in two drops of distilled water until a toothpaste consistency.

Lentulo # 40 spiral in a clockwise rotation was inserted in the root canal always with a small paste quantity, at different speeds: G1 = 5,000 rpm; G2 = 10,000 rpm; and G3 = 15,000 rpm, coupled to a 1:1 angle in an Endo Plus electric motor (VK Driller Ltda, Jaguaré, São Paulo, Brazil). The Lentulo spiral was inserted up to 3 mm short of the working length for filling of the apical third. This procedure was repeated 3 times, followed by condensation with an apical plugger which diameter was compatible with that of the root canal diameter⁵. For filling the middle and cervical thirds, the spiral was 5 mm short, and used as described above. The extrusion of the calcium hydroxide paste through access cavity, clinically determined the complete filling.

To analyze the quality of root canal filling, the Kodak Digital Dental Systems (RVG 5000- Eastman Kodak Company, Rochester, NY, USA), was used. It has an electrical and optical sensor of 3 juxtaposed slides: a scintillation crystal, fiber optics, and a CCD (charge coupled device), producing an electrical signal that generates an image with a real image resolution of 14 px/mm and resolution of 27.03 px/mm.

A millimeter screen (Plexus odonto-technology, Gloucester, UK) was connected to a shield made of light cardboard (2.0 cm by 1.5 cm) and fixed to the sensor in the digital system. It was kept connected to the Rx device by means of a positioner in the digital system (Rinn XCP - DS).

The crown of each specimen was fixed to an Ependorf tube with ethyl cyanoacrylate. The tube was cut at by using a carborundum disk, leaving it 20 mm in length. Transversal grooves were made to obtain an insertion pathway in the casting material made of silicone Speedex putty (Coltène Swiss AG), used as a connection between the positioner and the Rx tube.

The radiographic apparatus (Spectro 70 X, Dabi-Atlante) was used with an electrical stabilizer (Gnatu T-1. 200S 110 V.), 70 kVp and 7mA. The cylinder was positioned perpendicularly at a distance of 5.0 cm and with an exposure time of 0.32 seconds. Optical density values in pixels were obtained from the digital

image capture using filter tools for clarity and densitometry analysis from the digital system, following the millimeter ruler lines from the apical to the cervical subdivided into thirds at equidistant points. The data obtained from the images of each of the specimens, before and after filling with calcium hydroxide paste were registered. The pixels difference before and after filling were statistically analyzed by means of the Kruskal-Wallis test ($p < 0.05$).

Results

Statistical tests (Levene, K-S, and Lilliefors) were used to verify the normality and homogeneity of the data. The absence of this in all groups analyzed directed to the Kruskal-Wallis ANOVA median test ($p < 0.05$), which showed a statistical difference ($p = 0.0318$).

The optical density means and standard deviation for each group in the cervical, middle and apical third were: 43.25 (± 20.90), 38.70 (± 24.40) and 16.71 (± 19.85) for G1; 36.98 (± 15.97), 23.16 (± 15.16) and 20.28 (± 22.48) for G2 and 35.75 (± 22.21), 21.21 (± 10.16), 25.17 (± 15.26), respectively.

Once the minimum significant difference was calculated, multiple comparisons were performed, demonstrating a difference between G1, G2 and G3 and from G1 to G3 in the apical third ($p < 0.05$). In the cervical third, independently of speed there was no significant statistical difference ($p > 0.05$).

Figure 1 shows the results for different speeds in all thirds.

Discussion

The effectiveness of intracanal dressing with calcium hydroxide has been observed by various authors.^{4,6,11,12,22,23,24} However, its application needs special attention in order to completely fill the root canal space. It needs a direct contact with dentine walls in order to act in a direct and indirect mode.^{4,5,7,9,18} Holland et al²⁵ states that if the root canal is not well instrumented and thoroughly irrigated, the dressing will not be useful. So, root canal must be enlarged to diameters compatible with its anatomic condition. Simcock and Hicks²³ demonstrated that, independently of the technique used, in canals that were only slightly enlarged, the filling proved ineffective. That is why in this experiment root canals were enlarged to a # 50 K-file.

The calcium hydroxide paste was prepared with a distilled water base, because it is a hydrosoluble vehicle, which increases the effectiveness of calcium hydroxide.^{3,24,25} Barium sulphate was used as a radiopaque substance to differentiate the optical density of the calcium hydroxide from the dentine. The ratio of barium sulphate used to calcium hydroxide was 1:2.^{13,17}

The insertion of the paste was performed using small quantities at a time. When activated, the Lentulo spiral launched the paste against the canal walls, and the use of a plugger allowed its condensation in all thirds.

The speeds used were determined based on the maximum speeds possible in dental equipment (around 20,000 rpm). The higher the speed and the quantity of paste in the Lentulo, the greater the quantity of air that ends up being retained inside of the root canal, generating air bubbles formation that do

not allow the complete filling and, consequently, the desired action. Thus, the speeds used in the study were 15,000 rpm, 10,000 rpm, and 5,000 rpm, which were maintained constant through an electric motor (Driller – São Paulo, Brazil).

Digital radiography today represents one of the great advances in imaging, allowing speed and simplicity in the capture of images with a significant reduction in exposure time and allowing standardization, high-quality analysis, besides becoming a viable and safe alternative for the results interpretation, conferring greater diagnostic precision. The use of digital technology besides being reproducible is a system that allows almost instant images of the structures to be observed, without the need for chemical processing and with a reduced exposure time.²⁶

The assessment of areas filled in the cervical, middle,

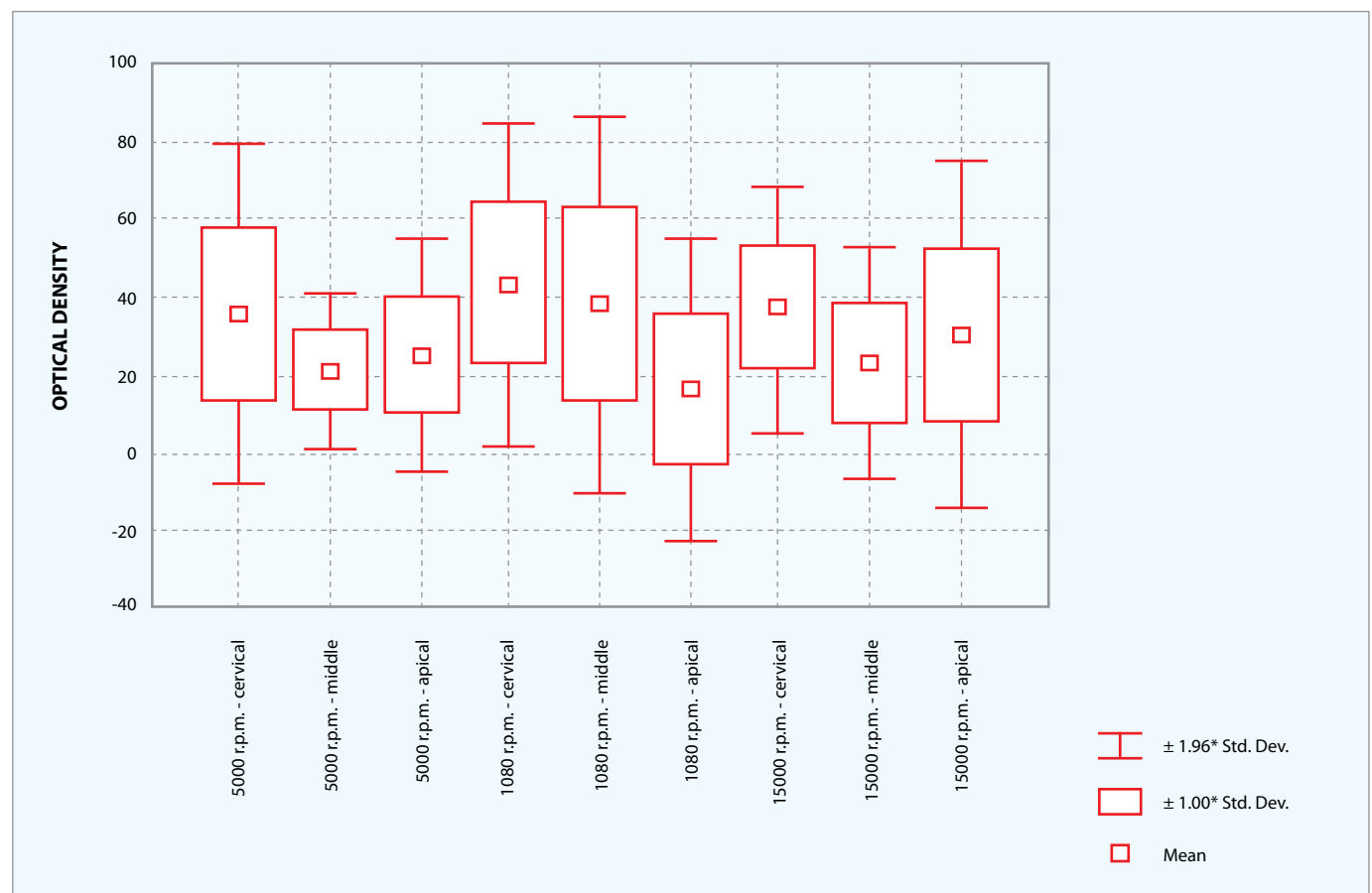


Figure 1. Optical density in the groups and thirds.

and apical thirds was performed based in the number of pixels (optical density) in the captured digital image. The millimeter screen used had the objective of serving as a measurement parameter before and after each of the specimens was filled with paste, at equidistant points, both in the dentine and in the root canal.⁴

The higher the optical density the better the filling of the root canal. The results obtained demonstrate that the middle third in G1 was better filled than G2 and G3, and statistically significant ($p < 0.05$). G3 was better filled in the apical third than G1 and G2, statistically significant in relation to G1 ($p < 0.05$).

Our results are in agreement with those by Cvek et al,¹² Sigurdsson et al,¹⁶ Deveau et al,¹⁸ Torres et al¹⁹ and Radhe et al.²⁰ The greatest difficulty in clinical practice is filling the apical third. According to our

results, beginning with 15,000 rpm for the apical third, and then reducing the speed to 5,000 rpm to fill the middle and cervical thirds, can help the three-dimensional filling of the root canal.

More studies are necessary, but our results allow us to infer that different speeds are necessary for complete calcium hydroxide filling with the Lentulo spiral.

Conclusion

1. Different speeds are necessary for the correct filling of the root canal with calcium hydroxide paste.
2. The speed of 15,000 rpm was more effective in filling the apical third.
3. The speed of 5,000 rpm was more effective in filling the cervical and middle thirds.

References

- Schilder H. Cleaning and shaping the root canal. *Dent Clin North Am.* 1974;18(2):269-96.
- Bystron A, Sundquist G. Bacteriologic evaluation of the efficacy of mechanical root canal instrumentation in endodontic therapy. *Scand J Dent Res.* 1981;89(4):321-8.
- Estrela C, Mamede I Neto, Lopes H, Estrela CR, Pécora J. Root canal filling with calcium hydroxide using different techniques. *Braz Dent J.* 2002;13(1):53-6.
- Estrela C. Endodontic science. São Paulo: Artes Médicas; 2009. v. 1.
- Sydney G. Medicação intra-canal: estágio atual. In: Bottino MA. Livro do ano: clínica odontológica brasileira. São Paulo: Artes Médicas; 2004. p. 131-61.
- Siqueira JF Jr, Uzeda M. Influence of different vehicles on the antibacterial effects of calcium hydroxide. *J Endod.* 1998;24(10):663-5.
- Dumsha TC, Gutmann JL. Clinical techniques for the placement of calcium hydroxide. *Compend Contin Educ Dent* 1985;6(7):482-9.
- Safavi KE, Nichols FC. Effect of calcium hydroxide on bacterial lipopolysaccharide. *J Endod.* 1993;19:76-8.
- Teixeira FB, Levin LG, Trope M. Investigation of pH at different dentinal sites after placement of calcium hydroxide dressing by two methods. *Oral Surg Oral Med Oral Pathol Oral Radiol Endod.* 2005;99:511-6.
- Estrela C, Pimenta FC, Ito IY, Mammann LL. In vitro determination of direct antimicrobial effect of calcium hydroxide. *J Endod.* 1998;24:15-7.
- Estrela C, Pimenta FC, Ito IY, Bammann LL. Antimicrobial evaluation of calcium hydroxide in infected dentinal tubules. *J Endod.* 1999;25:416-8.
- Cvek M, Hollender L, Nord CE. Treatment of non-vital permanent incisor with calcium hydroxide. A clinical microbiological and radiological evaluation of treatment in one sitting of teeth with mature or immature root. *Odontol Revy.* 1976;27(2):93-108.
- Webber RT, Schwiebert KA, Cathey GM. A technique for placement of calcium hydroxide in the root canal system. *J Am Dent Assoc.* 1981;103:417-21.
- Anthony DR, Senia S. The use of calcium hydroxide as temporary paste fill. *Tex Dental J.* 1981;99(10):6-10.
- Leonardo MR. Endodoncia: Tratamiento de conductos radiculares. São Paulo: Artes Médicas; 2005. vol. 2.
- Sigurdsson A, Stancill R, Madison S. Intracanal placement of calcium hydroxide: a comparison of techniques. *J Endod.* 1992;18:367-70.
- Staehle HJ, Thomä C, Muller HP. Comparative in vitro investigation of different methods for temporary root canal filling with aqueous suspension of calcium hydroxide. *Endod Dent Traumatol.* 1997;13:106-12.
- Deveaux E, Dufour D, Boniface B. Five methods of calcium hydroxide intracanal placement: an in vitro evaluation. *Oral Surg Oral Med Oral Pathol Oral Radiol Endod.* 2000;89:349-55.
- Torres CP, Apicella MJ, Yancich PP, Parker H. Intracanal placement of calcium hydroxide: a comparison of techniques, revisited. *Int Endod J.* 2004;30:225-7.
- Rahde N, Figueiredo JA, Oliveira EP. Influence of calcium hydroxide points on the quality of intracanal dressing filling. *J Appl Oral Sci.* 2006;14(3):219-23.
- Caliskan M, Turkun M, Turkun L. Effect of calcium hydroxide as an intracanal dressing on apical leakage. *Int Endod J.* 1998; 31:173-7.
- Holland R, Otoboni A Filho, Souza V, Nery MJ, Bernabé PFE, Dezan E. A comparison of one versus two appointment endodontic therapy in dog's teeth with apical periodontitis. *J Endod.* 2003;29:121-4.
- Simcock RM, Hicks ML. Delivery of calcium hydroxide: comparison of four filling techniques. *J Endod.* 2006;32:680-2.
- Safavi KE, Nakayama TA. Influence of mixing vehicle on dissociation of calcium hydroxide in solution. *J Endod.* 2000;11:649-51.
- Holland R, Valle GF, Taintor JF, Ingle JL. Influence of bony resorption on endodontic treatment. *Oral Surg Oral Med Oral Pathol.* 1983;55:191-203.
- Kawauchi N, Bullen IRFR, Chinell LEM. Evaluation of the linear measurements by conventional radiographs indirect digital images in the endodontic treatment. *J Appl Oral Sci.* 2004;12:330-6.