

The importance of the use of computed tomography in diagnosis and in endodontic planning: a case report

Renato Piai **PEREIRA**¹
João Milton Rocha **GUSMÃO**¹
Rogério Vieira **SILVA**²
David Costa **MOREIRA**¹

ABSTRACT

Objective: The aim of this study was to report a case of an endodontic re-treatment in a patient submitted to orthognathic surgery, using computed tomography to aid the diagnosis and treatment plan. **Methods:** The patient was referred for endodontic evaluation of anterior teeth with a history of orthognathic surgery on the maxilla and rigid internal fixation with miniplates for osteosynthesis in the region close to the

dental apices. **Results:** A three-dimensional evaluation of the region demonstrated periapical lesion of the left central incisor. The endodontic re-treatment resulted in remission of symptoms and regression of periapical bone rarefaction. **Conclusion:** The use of computed tomography was essential to the resolution of this case, what was proved with bone neoformation.

Keywords: Cone-beam computed tomography. Periapical periodontitis. Endodontics.

How to cite this article: Pereira RP, Gusmão JMR, Silva RV, Moreira DC. The importance of the use of computed tomography in diagnosis and in endodontic planning: a case report. *Dental Press Endod.* 2013 May-Aug;3(2):75-9.

» The authors report no commercial, proprietary or financial interest in the products or companies described in this article.

Received: June 8, 2013. Accepted: August 23, 2013.

¹Assistant professor at State University of Southwestern Bahia (UESB).

²Assistant professor at Northeastern Independent College.

Contact address: João Milton Rocha Gusmão
Rua José Moreira Sobrinho, Jequié/BA – Brazil – Departamento de Saúde
CEP: 45206-190 – E-mail: joao.milton@ig.com.br

Introduction

The necessity of evaluating structures in three dimensions in endodontic practice is noted especially in complex cases. Conventional radiographs are originally limited to a two-dimensional visualization, but, even with parallelism techniques, distortions and overlapping structures, are inevitable. The information of the anatomy is obscured and does not accurately reveal some aspects considered important to obtain a correct diagnosis and planning.¹

The difficulty of visualization of periapical lesions in two-dimensional radiography has been reported.²⁻⁵ Cone-beam computed tomography (CBCT) scans have identified more cases of periapical lesions than conventional radiography.⁶

The use of miniplates for osteosynthesis in orthognathic surgery promotes overlay images in conventional radiographs, which can hinder the diagnosis in Endodontics. There are reports of endodontic complications caused by the installation of miniplates.^{7,8}

Computed tomography provides a method for accurate diagnosis with high-resolution images, which can reduce the incidence of false-negatives,⁵ minimize interference of the observer and increase the reliability of interventions.

The aim of this study was to report a case of endodontic re-treatment in a patient submitted to orthognathic surgery, using computed tomography for the diagnosis and treatment plan.

Case report

A 32-year-old female patient complaining of pain in the anterior maxilla was referred to the service of Endodontics for endodontic evaluation of anterior teeth. Her previous dental history revealed that the patient had been submitted to orthognathic surgery two years before.

During the intraoral evaluation no edema or mobility of anterior teeth were observed. Palpation did not contribute to the diagnosis due to the presence of miniplates in the area next to the dental apices. The vertical percussion was positive for tooth #21. Electric pulp testing showed pulp sensitivity consistent with normal teeth for #11 and #22 elements. Radiographic examination showed the presence of endodontic treatment for teeth #21 and #12, with unsatisfactory aspect for tooth #21. However, radiographic interpretation of the periapical

region of the teeth was compromised by overlapping images caused by the miniplates (Fig 1). Therefore, a CBCT was requested for a three-dimensional visualization of the anterior maxilla. By means of the CBCT, an extensive area of bone rarefaction in the periapical region of tooth #21 was observed (Fig 2).

With the diagnosis of chronic apical periodontitis for tooth #21, the endodontic re-treatment began. After all preoperative care inherent to the treatment, such as dental prophylaxis, local anesthesia and use of rubber dam, the access to the root canal was performed by means of a round diamond bur and Endo Z bur (Microdont, São Paulo, Brazil). Gates Glidden drills (Microdont, São Paulo, Brazil) were used to remove two-thirds of the root canal material. Hedstrom files (Dentsply-Maillefer, Ballaigues, Switzerland) were then used in a reaming motion to reach the working length and copious irrigation with sodium hypochlorite at 5.25%.

The apparent length of the tooth was obtained by the measuring tool present in the software for reading the CBCT and the working length was determined by means of an electronic apex locator, Endex (Osada, Tokyo, Japan), since the root apex could not be visualized through radiographic examination of the tooth length (Fig 3). The canal was instrumented by K-files (Dentsply-Maillefer, Ballaigues, Switzerland) with a working length of 19 mm to a #60 final file size. The final irrigation was performed with 17% EDTA (Fórmula & Ação, São Paulo, Brazil) and the intracanal dressing for 30 days, with calcium hydroxide Callen (SS White, Rio de Janeiro, Brazil). After that period, there was remission of symptoms and obturation was performed by means of the cold lateral condensation technique with gutta-percha cones and Pulp Canal Sealer EWT (SybronEndo, Orange, USA) (Fig 4).

Two years after endodontic therapy was concluded, a new CBCT was carried out and it revealed regression of periapical bone rarefaction (Fig 5).

Discussion

Periapical radiographs are complementary tests widely used in Endodontics due to their technical simplicity and for allowing the resolution of a large number of cases. However, their limitation of two-dimensional visualization can hinder the diagnosis and the planning of specific cases.¹

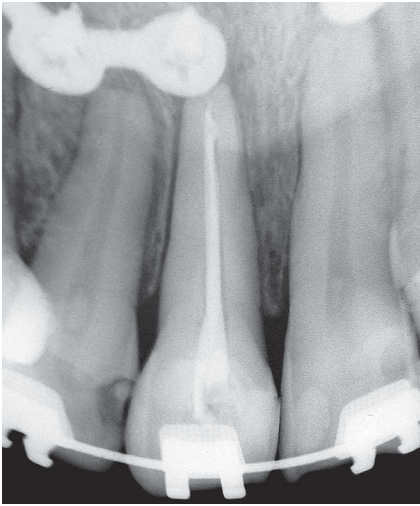


Figure 1. Preoperative periapical radiograph of tooth #21.

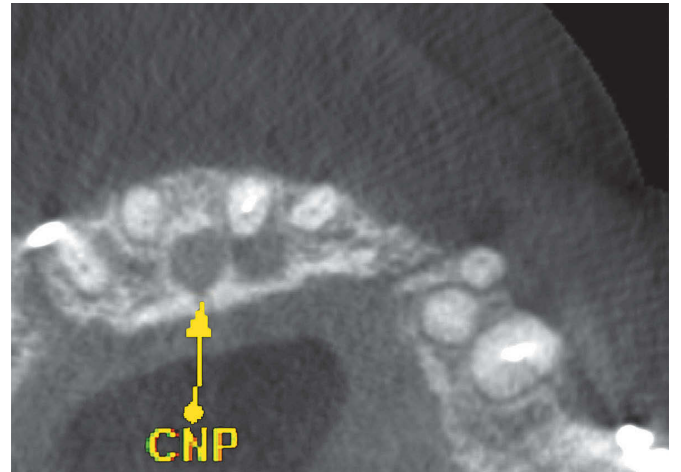
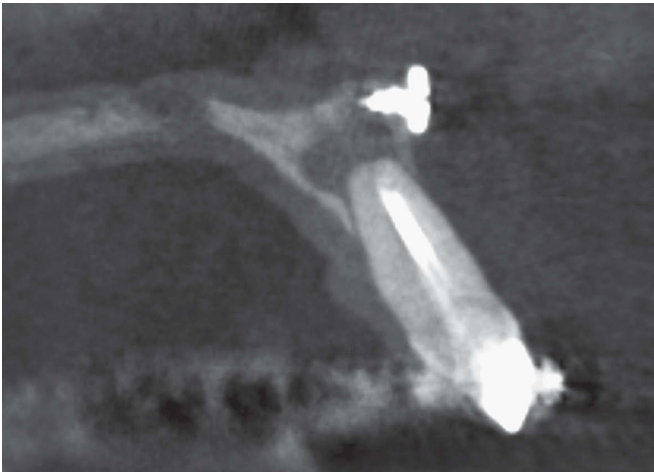

Figure 2. Sagittal and axial CBCT tomographic sections demonstrating periapical lesion.

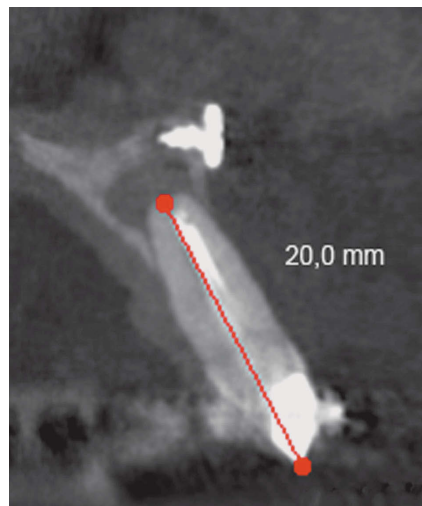
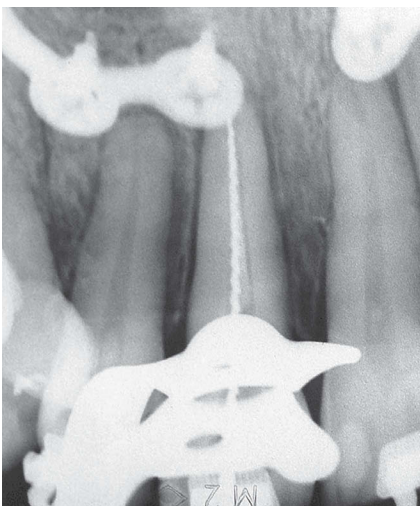


Figure 3. Periapical radiograph and CBCT for odontometry determination.

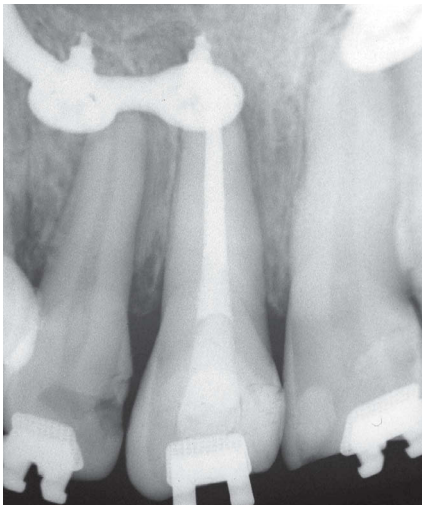


Figure 4. Postoperative periapical radiograph of tooth #21.

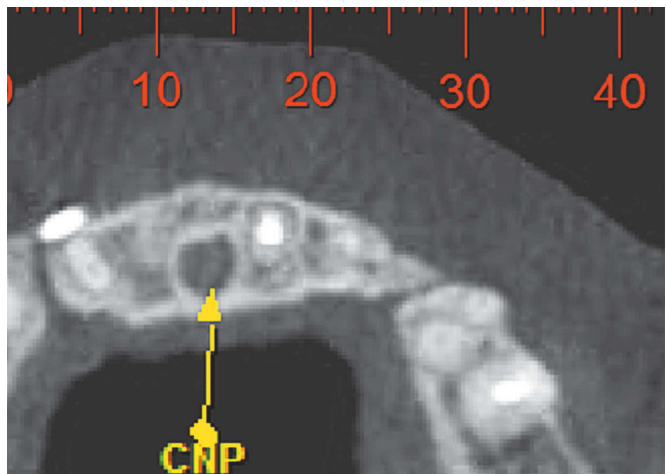
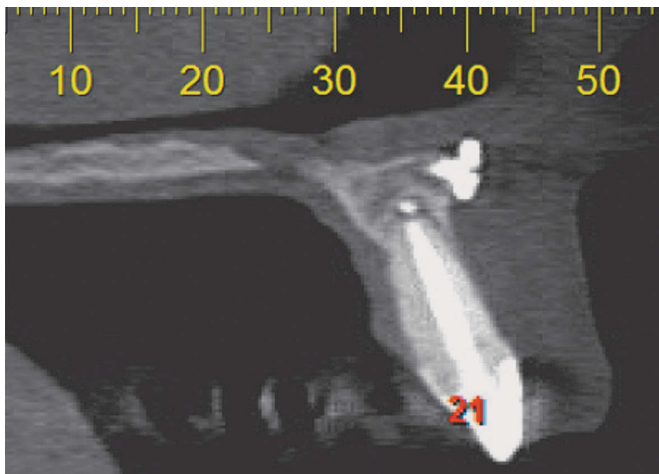


Figure 5. Sagittal and axial tomographic sections taken 2 years after treatment demonstrating regression of periapical lesion.

The importance of computed tomography in Endodontics is unquestionable as it presents many applications such as detection of root fractures, location of root canals, evaluation of complications such as resorption, calcification and perforation, and interpreting three-dimensional anatomical structures.^{2,9,10,11} Despite being an excellent diagnostic tool, the request for a CBCT in Endodontics is necessary only for selected cases, since it is able to reproduce images of areas do not reached by conventional radiographies.⁹

In this case report, the symptoms could be interpreted as a complication arising from orthognathic surgery. Complications associated with the use of miniplates include metal sensitivity, infection, neurologic

injury, dental trauma, stress shielding, and malocclusion.⁷ Arikan et al⁸ reported a case of root perforations originated during screws plate installation of miniplates. The injuries caused pulp necrosis in two teeth.

Radiographs showed miniplates overlapping the root apex, which made radiographic interpretation difficult. Tomography eliminated structures overlapping and allowed visualization of the extensive periapical lesion. The diagnosis and planning of this report would not be complete without this tool.

Computed tomography is currently associated with increased rates of identification of periapical lesions when compared to conventional radiograph.^{3,4,6,12,13} Estrela et al⁶ demonstrated that cone-

beam computed tomography (CBCT) identified more cases of periapical lesions than routine radiographic examination, and that these lesions were only identified by conventional methods when a severe condition was present.

Conclusion

Based on these results, it was concluded that the use of computed tomography was indispensable for the diagnosis, treatment plan and for the solution of this case, which was proved by bone neoformation.

References

1. Costa CCA, Moura-Neto C, Koubik ACGA, Michelotto ALC. Aplicações clínicas da tomografia computadorizada cone beam na Endodontia. *Rev Inst Ciênc Saúde*. 2009;27(3):279-86.
2. Patel S, Dawood A, Ford TP, Whaites E. The potential applications of cone beam computed tomography in the management of endodontic problems. *Int Endod J*. 2007;40(10):818-30.
3. Patel S, Dawood A, Whaites E, Ford T P. Detection of periapical defects in human jaws using cone beam computed tomography and intraoral radiography. *Int Endod J*. 2009;42(6):507-15.
4. Liang Y, Li G, Wesselink PR, Wu M. Endodontic Outcome Predictors Identified with Periapical radiographs and Cone-beam Computed Tomography Scans. *J Endod*. 2011;37(3):326-31.
5. Estrela C, Bueno MR, Azevedo BC, Azevedo JR, Pécora JD. A new periapical index based on Cone Beam Computed Tomography. *J Endod*. 2008;34(11):1325-3.
6. Estrela C, Bueno MR, Leles CR, Azevedo B, Azevedo JR. Accuracy of cone beam computed tomography and panoramic and periapical radiography for detection of apical periodontitis. *J Endod*. 2008;34(3):273-9.
7. Aziz SR, Ziccardi VB, Borah G. Current therapy: complications associated with rigid internal fixation of facial fractures. *Compend Contin Educ Dent*. 2005;26(8):565-71.
8. Arıkan H, Kaptan F, Kayahan B, Haznedaroğlu F. Managing perforations due to miniplate application. *J Endod*. 2006;32(5):482-5.
9. Kim E, Kim KD, Roh BD, Cho YS, Lee SJ. Computed tomography as a diagnostic aid for extracanal invasive resorption. *J Endod*. 2003;29(7):463-5.
10. Patel S. New dimensions in Endodontics imaging: Part 2. Cone beam computed tomography. *Int Endod J*. 2009;42(6):463-75.
11. Ball RL, Barbaziam JV, Cohenca N. Intraoperative endodontic applications of cone-beam computed tomography. *J Endod*. 2013;39(4):548-57.
12. Low KMT, Dula K, Bürgin W, Arx T. Comparison of periapical radiography and limited Cone-Beam Tomography in posterior maxillary teeth referred for apical surgery. *J Endod*. 2008;34(5):557-62.
13. Nakata K, Naitoh M, Izumi M, Inamoto K, Arijı E, Nakamura H. Effectiveness of dental computed tomography in diagnostic imaging of periradicular lesion of each root of a multirrooted tooth: a case report. *J Endod*. 2006;32(6):583-7.