

# Treatment of a lately replanted avulsed permanent tooth: Case report

Jefferson J. C. **MARION**<sup>1</sup>  
 Frederico Campos **MANHÃES**<sup>2</sup>  
 Karina Yamada **DANILUSSI**<sup>3</sup>  
 Thaís Mageste **DUQUE**<sup>4</sup>

## ABSTRACT

Avulsion after dental trauma is one of the most serious emergencies in the dental offices. Treatment success for this kind of injury lies on explaining to patients and dentists about the prompt management of the avulsed tooth. In the present study it's emphasized the relationship between the wishes of the patient and his parents and the maintenance of the avulsed tooth in the oral cavity, exerting its esthetic and masticatory functions. Besides the time, other factors such as handling the tooth to be

reimplanted, replantation technique, storage medium, endodontic treatment of the reimplanted tooth, intracanal medication and postoperative control contribute to a better prognosis. Dental avulsion usually affects children during their periods of bone growth, thus replantation aims to eliminate esthetic, psychological and social consequences for the patient, and can avoid prosthesis, satisfying patient's wishes.

**Keywords:** Dental avulsion. Dental replantation. Facial traumas.

**How to cite this article:** Marion JJC, Manhães FC, Danilussi KY, Duque TM. Treatment of a lately replanted avulsed permanent tooth: Case report. *Dental Press Endod.* 2012 Oct-Dec;2(4):57-64.

» The authors report no commercial, proprietary, or financial interest in the products or companies described in this article.

<sup>1</sup>PhD Student in Dental Clinic/Endodontics, UNICAMP. Professor, Endodontics Department, ABO and Uningá.

<sup>2</sup>PhD Student in Endodontics, UNICAMP.

<sup>3</sup>Specialist in Endodontics, Uningá.

<sup>4</sup>PhD Student in Dental Clinic/Endodontics, UNICAMP.

Received: October 01, 2012 / Accepted: November 03, 2012.

Contact address: Jefferson José de Carvalho Marion  
 Rua Nêo Alves Martins, 3176 – 6º andar – Sala 64 – Centro  
 CEP: 87.013060 – Maringá/PR – Brazil  
 Email: jefferson@jmarion.com.br

## Introduction

Dental trauma is one of the main causes of loss of permanent anterior teeth.<sup>34</sup> Avulsion, as a possible result of traumatic injuries, is one of the most serious emergencies in dental offices,<sup>26</sup> causing the complete separation of the tooth and its alveolus (bone cavity where it is inserted), and disruption of the periodontal ligament fibers, remaining part of it adhered to the cementum of the tooth and the other part to the bone.<sup>23</sup>

The traumatic removal of a tooth from its respective alveolus produces disruption of periodontal ligaments and blood supply to the pulp tissue. As a result, the dental pulp gets necrosis and the periodontium is severely damaged. The type of cure is directly related to the extent of extra-oral time and the conditions under which the tooth was kept before replanted.<sup>6</sup> The replantation has been proposed as an attempt to reintegrate the avulsed tooth to its normal anatomical position. It represents one of the most conservative behavior in dentistry because it allows the preservation of function and esthetics, postponing the need for fixed or removable prosthesis and reducing the psychological impact resulting from immediate tooth loss.<sup>2,20,23,27,32</sup>

The highest incidence of avulsion affects the upper incisors in children from 7 to 12 years of age due to the childhood and adolescence activities. The overjet with incisors protrusion and insufficient lips sealing are predisposing factors to dental trauma.<sup>20,23,26,27,28,32</sup>

The tooth loss can determine a psychosocial impact especially among teenagers. The body appearance, especially the face, plays an important role in humans relations,<sup>38</sup> and the eyes and the mouth are the components most commonly associated with physical attraction, acting as key-factors in social interactions and in determining the personal success.<sup>9</sup>

Although it is impossible to guarantee the long term maintenance of a traumatized tooth, the patient's age, injury severity, timely treatment and follow-up of the teeth can maximize the success chances.<sup>3</sup> The delay in reimplanting the tooth is often related to the lack of knowledge of the patients, their parents or who treated them.<sup>32</sup>

Mackie and Wortington<sup>21</sup> mentioned that replantation should always be considered as an alternative

for the treatment. Andreassen<sup>5</sup> concluded that there are many factors that influence the treatment, as factors outside the office and the way the dentist works. Also concluded that the most important factor is the extra-alveolar time, and the smaller the time the tooth remains outside its alveolus, the greater the odds of a successful replantation.

The factors that can change the prognosis of replantation are: The extent of the trauma, length of extra-alveolar time, storage medium, contamination, how the tooth is handled and status of the avulsed tooth. These factors can cause problems such as periodontal inflammation, root resorption, and ankylosis, which interfere with the success of reimplants.<sup>20,23</sup>

The best storage medium for avulsed teeth would be the alveolus itself.<sup>24</sup> When there is no possibility of maintaining the tooth in the patient's mouth, the ideal solutions are: Milk, saliva, saline solution, blood and tissue culture media.<sup>11,14,20,32,37</sup>

It is important to carefully handle the tooth, not touching and/or scraping the periodontal ligament. The accidental removal of part of this ligament determine the ankylosis of the reimplanted tooth.<sup>28</sup>

Therefore, the endodontic treatment of an avulsed tooth is necessary since pulp necrosis occurs as a consequence. Some dressing therapies are proposed as a way to preserve the tooth, however the medications exchange time vary with the degree of impairment and sequelae.<sup>8,16,18</sup> A new therapy with chlorhexidine gel, calcium hydroxide and zinc oxide for treating avulsed and reimplanted teeth has been proposed by Soares and Souza-Filho.<sup>37</sup>

For this reason, aiming at enlightening the treatment and replantation of avulsed teeth, this case report will describe the clinical and radiographic condition of an anterior avulsed and reimplanted tooth, treated with dressing of calcium hydroxide with different vehicles, and the seven years follow-up.

## Case report

An 11-year-old female patient presented to the endodontics office 40 days after the avulsion and replantation of tooth #21.

Before the anamnesis, her mother (legal responsible) demanded the non-extraction of the traumatized tooth. Therefore the whole endodontic therapy

was elucidated and discussed in order to prevent or postpone the extraction of that tooth. Thus the mother reported that the patient was playing in the playground and fell to the ground causing the avulsion of tooth #21. After the accident she took about 15 minutes to find the avulsed tooth. After this period she was suggested to wash the tooth with water for about 5 minutes. The mother asked the patient to keep it under her tongue and went to a dental office where the dentist cleaned the tooth in a saline solution without scraping the root external surface. About one hour after the avulsion, the dentist performed the replantation with a semi-rigid orthodontic wire (splinting), performed the coronary access, pulpectomy, application of calcium hydroxide-based dressing with saline solution and temporary restoration with Coltosol.

The dentist prescribed prophylactically tetanus vaccine — since the patient's mother had doubts whether her daughter had received this medication — as well as prescribed amoxicillin-based systemic and antibiotic medication.

The splinting was maintained for approximately 30 days and only after its removal the patient went to the endodontist. Also during the anamnesis it was found that the patient had no systemic health problem, and the radiographic examination showed that the #21 tooth presented a large area with external root resorption and also an open apex, although in this evaluation it was observed the absence of root fracture or bone fracture (Fig 1A).

About 40 days later, the coronal opening was improved and biomechanical preparation of the root canal was performed with endodontic hand files and 1% sodium hypochlorite. The odontometry was performed during the canal preparation to confirm the working length (Fig 1B).

The canal was dried with sterile paper points, and flooded with 17% EDTA for 3 minutes with manual agitation. After removal of EDTA, a new drying was performed and calcium hydroxide aqueous solution (saline) was inserted into the root canal, which was replaced after 15 days.

In the second session it was inserted a calcium hydroxide paste with propylene glycol and iodoform (Fig 1C). The dressing was changed when it was radiographically verified that it had been partly resorbed.

These exchanges are justified because it was a tooth with external resorption and incompletely formed apex.

After one year and nine months, the endodontist was informed by the responsible for the patient that she would take part on a exchange program abroad for 3 years. Thus the endodontist decided to make a temporary root canal filling with calcium hydroxide, 2% chlorhexidine gel and zinc oxide in a 02:01:02 proportion,<sup>37</sup> in Coltosol consistency, which was incrementally inserted and adapted by means of vertical condensers throughout the whole root canal until apical portion. Later, the teeth were sealed with Coltosol, restored with composite resin and then radiographed (Fig 1D).

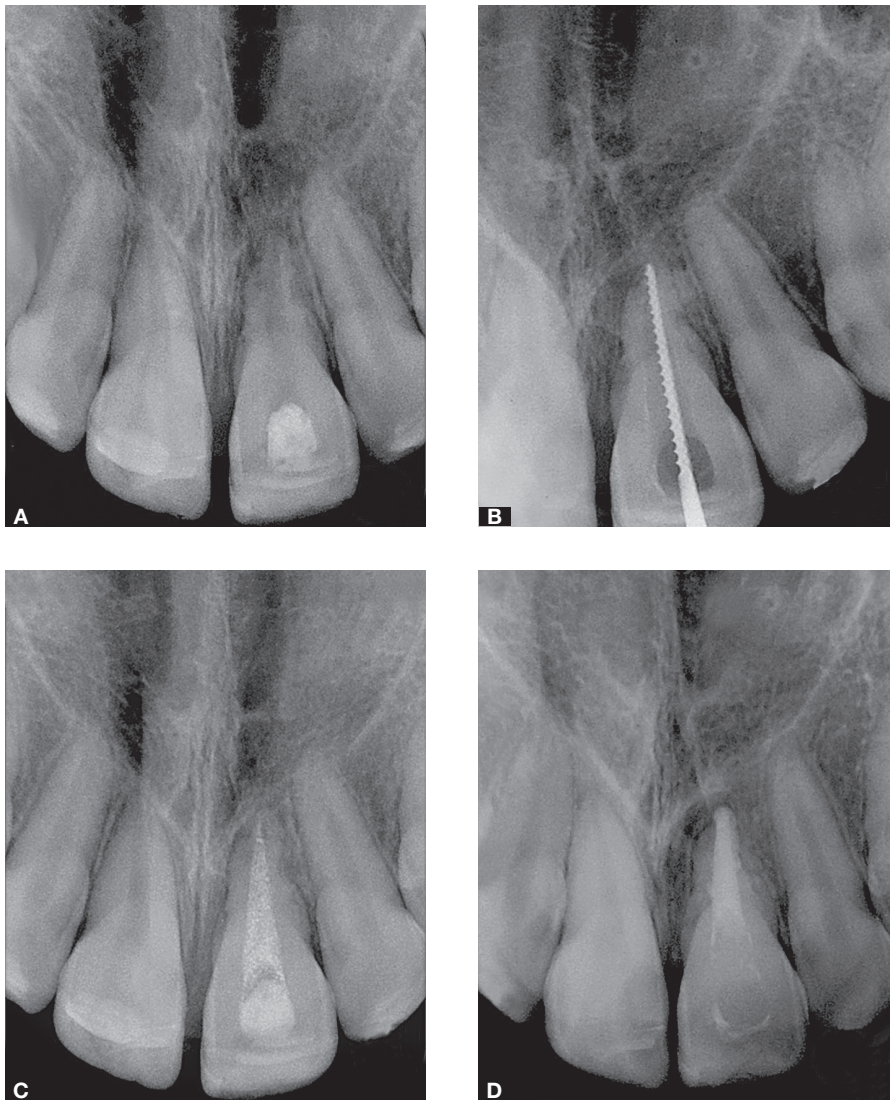
After three years and one month the patient returned to the office to continue the treatment. It was made a periapical intraoral radiograph (Fig 2A) and also requested a cone beam tomograph to accurately assess the root involvement (Fig 2B). When evaluating the results it was observed mild resorption of the temporary filling of root canal, and stabilized root resorption, offering conditions for the permanent root canal obturation.

A few days later the endodontist removed the temporary filling of the root canal, performed new biomechanical preparation, as described before, and performed root canal filling with gutta-percha and sealer based on calcium hydroxide (Figs 2C, 2D).

After seven years, the patient presented to perform follow-up. Periapical intraoral radiographs, cone beam computed tomograph and intraoral photographs were requested. Through these exams it was observed the root resorption stabilization (Fig 3A); mild coronary darkening possibly due to the use of iodoform; cervical gingival recession and periodontal health (Fig 3B); lack of mobility and presence of periapical repair with continuous lamina dura throughout root length (Fig. 3C).

## Discussion

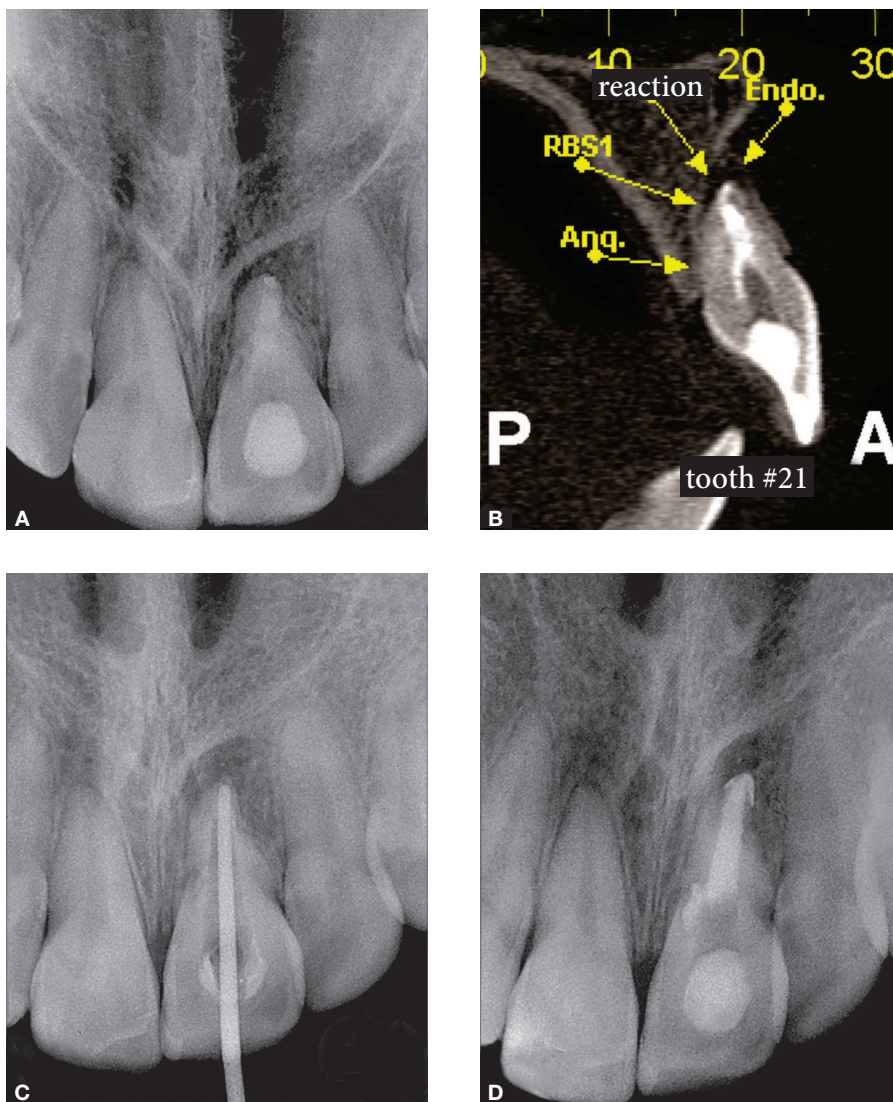
Dental replantation is one of the most conservative procedures in dentistry,<sup>2</sup> although the improper handling of the teeth can lead to its loss.<sup>36</sup> According to Poi et al<sup>32</sup> and Marzola,<sup>23</sup> this occurs because almost 82% of the population don't know what to do after dental traumas. In the present case report, after the avulsion, the mother washed the tooth with water and asked the



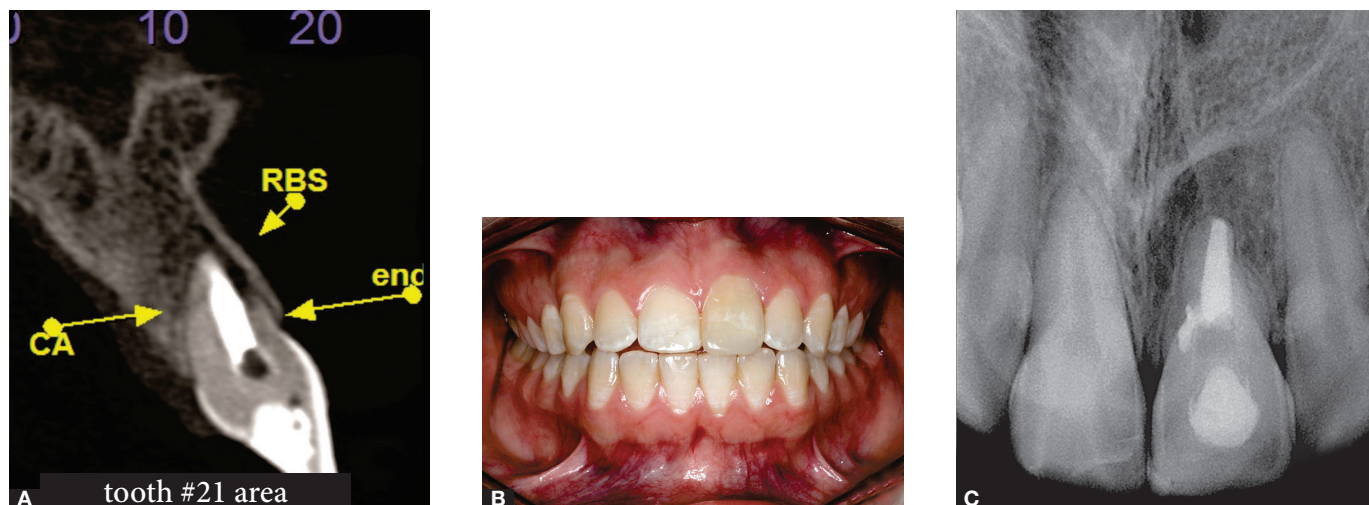**Figure 1.** **A)** Initial radiograph showing area with external root resorption and open apex. **B)** Odontometry to confirm the working length. **C)** Dressing with calcium hydroxide, propylene glycol and iodoform. **D)** Temporary root canal filling with calcium hydroxide, 2% chlorhexidine gel and zinc oxide in 02:01:02 proportion.

patient to put it under the tongue. According to Marzola et al,<sup>22</sup> the best storage medium to avulsed tooth is its alveolus. Morgado et al<sup>28</sup> reported that water as that storage medium is as harmful as the dry medium, because it is important the correct osmolarity and pH of the storage medium and the hypotonic conditions result in lysis of cells. However Blomlof,<sup>11</sup> O'Donnell and Wei<sup>30</sup> report that despite saliva has some disadvantages such as low osmolarity and bacterial content, it minimizes the storage period in dry medium and maintains the tooth moisturized, offering the highest success odds.

Also according to Marzola<sup>23</sup> and Peterson et al<sup>31</sup> the milk can also act very effectively, promoting amazing results and helping to remove debris from the root and dissolve bacteria. In addition, due to its availability, remains the best option to be recommended and disseminated to the general population.<sup>10</sup> Thus, with the huge amount of information available in the media and internet, dentists should utilize these resources to make the patients aware that if the avulsed tooth cannot be immediately reimplanted, it should be kept in a proper storage medium.



**Figure 2.** **A)** Radiograph after 3 years and 1 month with temporary filling. **B)** Tomographic image showing the root involvement. **C)** Removal of root canal temporary filling. **D)** Definitive root canal obturation with gutta-percha and calcium hydroxide-based sealer.



**Figure 3.** **A)** Follow-up tomography, after 7 years of treatment beginning. **B)** Photograph showing mild crown darkening, cervical gingival recession and healthy periodontium. **C)** Follow-up radiograph, after 7 years of treatment beginning, evidencing the presence of periapical repair, with continuous lamina dura.

The recommended ones according to Hwang et al<sup>19</sup> are: Hank's saline solution, eggwhite, milk powder, Gatorade®, propolis and green tea.

At the office, the dentist chose to clean the tooth with saline solution and do not scrap the root surface before dental replantation. This is corroborated by Ruellas et al,<sup>34</sup> Morgado et al<sup>28</sup> and Marzola,<sup>23</sup> who attest that the presence of periodontal ligament remnants in the root surface is essential to the success of reimplanted teeth, and the preservation of its vitality is the primary factor. Saad Neto et al<sup>35</sup> believe that even parched, the cemental periodontal ligament should be preserved. If well-treated it promotes the functional recovery of the structures on the periodontal ligament space. Morgado et al<sup>28</sup> and Marzola<sup>23</sup> attest that in order to inhibit or retard the external root resorption, the treatment of this root surface can be done with the use of fluoride associated with immersion in antibiotic. According to Moreira<sup>27</sup> and Marzola,<sup>23</sup> replantation must be done immediately by slow insertion, to allow the leakage of fluids from the alveolus, along with continuous pressure for five to ten minutes. If replantation is abrupt the pressure of fluid may cause extrusion of the tooth, and care must be taken not to let it in premature occlusal contact.

After the replantation, the dentist performed a semi-rigid splinting with orthodontic wire, which was maintained for a period of 30 days in order to stabilize the tooth in the alveolus. The semi-rigid immobilization allowed arrangement of functional periodontal ligament fibers, avoiding ankylosis.<sup>24</sup> However the period in which the splinting was used in this case contradicts the period recommended by other authors<sup>6,7,33</sup> who claim that the ideal time is 7 to 10 days, since the more rigid and lasting is the stabilization, greater root resorption is expected.

The current trend is to make a soft splinting and establish an occlusal function that will act as a physiological stimulus in the metabolism of periodontal tissues.<sup>23,31</sup> The physiological movements of the teeth are indicated because they promote fibrous union instead of osseous union of root to alveolar bone.<sup>31</sup>

EDTA was used before the medication for all sessions and before the final root canal filling in order to increase the permeability of dentin and facilitate the diffusion of calcium hydroxide ions on dentin. This is justified because in the literature there is a great num-

ber of studies using EDTA in different concentrations and associations, in order to improve the cleaning of root canal walls, by removing the smear layer.<sup>15,25</sup>

In order to help in the decontamination of root canal, to promote the apical closure and/or deposition of mineralized tissue and to stabilize resorption, the endodontist firstly used in this case report a dressing based in calcium hydroxide paste with aqueous vehicle (saline solution), promptly promoting the diffusion of calcium hydroxide; and at a second moment, a viscous vehicle (propyleneglycol) in order to promote a slower diffusion of calcium hydroxide. This association with various vehicles can also inhibit bacterial growth and control infections by residual lipopolysaccharides. Aiming to decrease the number of necessary exchanges of this medication, other authors<sup>16,17,29</sup> agree with this protocol employed. However Felipe et al<sup>13</sup> disagree because they claim that this medication could remain for longer periods as three, six or twelve months. The use of temporary filling based in calcium hydroxide, 2% chlorhexidine gel and zinc oxide is corroborated by Soares and Souza-Filho<sup>37</sup> that state that when this medication was maintained for an average of 9.1 months caused a decrease in the percentage of all clinical signs and symptoms initially observed, with the exception of ankylosis, which remained unchanged, showed a significant reduction in the percentage of thickening of the periodontal ligament. And regarding root resorption, it can be noted that there was no reduction in the percentage of inflammatory resorption. The presence of these resorption associated with dental trauma was also reported by Andreasen.<sup>4</sup>

In the present study we believe that the period of extra-alveolar time, the roots washing with water and saline solution, semi-rigid splitting, intracanal dressing and temporary filling with the paste contributed to preserve the tooth in the oral cavity exercising its esthetic and masticatory function, avoiding prosthetic or even radical procedures, such as extraction. Thus, we can say that spite of the tooth being a little more dark and with gingival retraction, it was the right decision not to extract the teeth in the initial treatment. We also believe that the satisfaction of the patient and their parents was achieved because, as in the study of Moreira,<sup>27</sup> giving the patient information about the treatment and prognosis, and explaining the possible consequences of replantation after

avulsion (ankylosis, external resorption and infection) is extremely important to obtain patient collaboration with the selected therapy.

## Conclusion

Based on the clinical results of this case report, we stated that the replantation of avulsed permanent teeth is a valid clinical management, because it can

preserve the tooth in the oral cavity, and we believe that intracanal dressing based in calcium hydroxide, still reveals as the better substance to be used in an attempt to obtain good clinical condition to establish the tooth in the oral cavity. The dentists should, whenever it's possible, try to respect the wishes and desires of the patients, because in this way the patient will get better cooperation across the treatment.

## References

1. Abou-Rass M, Oglesby SW. The effects of temperature, concentration and type on the solvent ability of sodium hypochlorite. *J Endod.* 1981;7(8):376-7.
2. Abrams RA. Replantation of an avulsed incisor. Case report. *Quintessence Int.* 1978;9(11):85-7.
3. Andreasen JO, Andreasen FM, Skeie A, Hjorting-Hansen E, Schwartz O. Effect of treatment delay upon pulp and periodontal healing of traumatic dental injuries: a review article. *Dent Traumatol.* 2002;18(3):116-28.
4. Andreasen JO. Traumatic injuries of the teeth. 3<sup>rd</sup> ed. Copenhagen: Munksgaard; 1984. 478p.
5. Andreasen JO. Atlas of replantation and transplantation of teeth. Philadelphia: WB Saunders; 1992.
6. Andreasen JO. Periodontal healing after replantation of traumatically avulsed human teeth: assessment by mobility testing and radiography. *Acta Odontol Scand.* 1975;3(35):325-35.
7. Andreasen JO. Etiology and pathogenesis of traumatic dental injuries. A clinical study of 1,298 cases. *Scand J Dent Res.* 1970;78(4):329-42.
8. Anjos Neto DA, Marion JJC, Borlina SC, Murata SS. A influência do hidróxido de cálcio como curativo de demora e do cimento obturador no reparo de lesão periapical crônica extensa. Relato de caso. *Rev Ciênc Odontol.* 2005;8(8):63-7.
9. Baldwin DC. Appearance and esthetics in oral health. *Community Dent Oral Epidemiol.* 1980;8(5):244-56.
10. Bastos JV, Cortes MIS, Gonçalves APC, Cançado CFL, Ferreira FS, Lourenço MS, et al. Avulsão dental: manejo e tratamento emergencial dos casos encaminhados à clínica de traumatismos dentários da FO-UFMG. *Anais do 8º Encontro de Extensão da UFMG;* 2005 Out. 3-8; Belo Horizonte: UFMG; 2005.
11. Blomlöf L. Storage of human periodontal ligament cells in a combination of different media. *J Dent Res.* 1981;60(11):1904-6.
12. Côrtes MIS, Marcenes W, Sheiham A. Prevalence and correlates of traumatic injuries to the permanent teeth of school children aged 9-14 in Belo Horizonte. *Endod Dent Traumatol.* 2001;17(1):22-6.
13. Felipe MC, Felipe WT, Marques MM, Antoniazzi JH. The effect of the renewal of calcium hydroxide paste on the apexification and periapical healing of teeth with incomplete root formation. *Int Endod J.* 2005;38(7):436-42.
14. Frujeri MLV. Avulsão dentária: efeito da informação na mudança de comportamento em diferentes grupos profissionais [dissertação]. Brasília (DF): Universidade Federal de Brasília; 2006.
15. Goldman L, Goldman M, Kronman J, Lin PS. The efficacy of several irrigating solutions for endodontics: a scanning electron microscopic study. *Oral Surg.* 1981;52(2):197-204.

16. Holland R, Souza V, Nery MJ, Mello W, Bernabé PFE, Otoboni Filho JA. Effect of the dressing in root canal treatment with calcium hydroxide. *Rev Fac Odontol Araçatuba*. 1978;7(1):39-45.
17. Holland R, Souza V, Tagliavini RL, Milanezi LA. Healing process of teeth with open apices. Histological study. *Bull Tokyo Dent Coll*. 1971;12(4):333-8.
18. Holland R, Souza V. Ability of a new calcium hydroxide root canal filling material to induce hard tissue formation. *J Endod*. 1985;11(12):535-43.
19. Hwang JY, Choi SC, Park JH, Kang SW. The use of green tea extract as a storage medium for the avulsed tooth. *J Endod*. 2011;37(7):962-7.
20. Isolan TMP, Borges CB, Renon MA, Pesce ALC, Moro M. Reimplante dental: conduta clínica atualizada. *RGO: Rev Gaúcha Odontol*. 1994;42(5):371-84.
21. Mackie IC, Worthington HV. An investigation of replantation of traumatically avulsed permanent incisor teeth. *Br Dent J*. 1992;172(1):17-20.
22. Marzola C, Toledo-Filho JL, Valarelli TP, Rosa-Marques R. Avulsão dental: a comunidade leiga e o cirurgião dentista sabem o que fazer? [dissertação]. São Paulo (SP): Associação Hospitalar de Bauru; 2006.
23. Marzola C. Fundamentos de cirurgia buco maxilo facial. Bauru: Ed. Independente; 2005. CDR com 70 capítulos de Cirurgia e Traumatologia.
24. Massler M. Tooth replantation. *Dent Clin North Am*. 1974;18(2):445-52.
25. McComb D, Smith DC, Beagrie GS. The results of "in vivo" endodontic chemomechanical instrumentation. A scanning electron microscopy study. *J Brit Endod Soc*. 1976;9(1):11-8.
26. Miranda ACE, Habitante SM, Calendária LFA. Revisão de determinados fatores que influenciam no sucesso do reimplante dental. *Rev Biociência*. 2000;6(1):35-9.
27. Moreira TC. Condutas clínicas para o reimplante de dentes permanentes avulsionados: revista da literatura. *Ortodon Gaúch*. 1998;2(1):50-7.
28. Morgado MLC, Sagretti OMÃ, Guedespinto AC. Reimplantes dentários. *Rev Bras Odontol*. 1992;9-10(3):38-44.
29. Nedley MP, Powers GK. Intentional extraction and reimplantation of an immature invaginated central incisor. *ASDC J Dent Child*. 1997;64(6):417-20.
30. O'Donnell D, Wei SHY. Management of dental trauma in children. In: Wey SHY. *Pediatric dentistry: total patient case*. Philadelphia: Lea & Febiger; 1988. 615 p.
31. Peterson LJ, Ellis E, Hupp JR, Tucker MR. *Cirurgia Oral e Maxilofacial Contemporânea*. 4ª ed. Rio de Janeiro: Elsevier; 2005. p. 549-55.
32. Poi WR, Salineiro SL, Miziara FV, Miziara EV. A educação como forma de favorecer o prognóstico do reimplante dental. *Rev Assoc Paul Cir Dent*. 1999;53(6):474-9.
33. Ram D, Cohenca N. Therapeutic protocols for avulsed permanent teeth: review and clinical update. *Pediatr Dent*. 2004;26(3):251-5.
34. Ruellas RMO, Ruellas AÇO, Ruellas CVO, Oliveira MM, Oliveira AM. Reimplante de dentes permanentes avulsionados: relato de caso. *Rev Univ Alfenas*. 1998;4:179-81.
35. Saad Neto M, Santos Pinto R, Colli Boatto MD. Reimplante imediato de incisivos de ratos tratados com antibiótico. Estudo histológico. *Rev Odontol Unesp*. 1991;20(1):143-54.
36. Shusterman S, Meller SM, Kane J. Reimplantation of traumatically avulsed immature incisor: a report of case. *J Dent Child*. 1976;43(1):49-52.
37. Soares AJ, Souza-Filho FJ. Traumatized teeth submitted to a new intracanal medication protocol. *Braz J Dental Traumatol*. 2011;2(2):1-5.
38. Vallittu PK, Vallittu AS, Lassila V.P. Dental esthetics: a survey of attitudes in different groups of patients. *J Dent*. 1996;24(5):335-8.