

The use of white MTA in the treatment of internal root resorption: Case report

Carlos Alberto Herrero de **MORAIS**¹

Aline Gabriela **CANDIDO**²

Larissa Coelho **PIRES**²

Renata Corrêa **PASCOTTO**³

ABSTRACT

Introduction: Internal root resorption is a rare occurrence, asymptomatic, with slow progression, detected through routine radiographic examination, in which appears as a radiolucent and uniform lesion. The etiology and pathogenesis are not well understood, and it can occur as a result of trauma, orthodontic force, excess of heat, and other iatrogenic causes. After diagnosis of internal resorption, endodontic treatment is the choice.

Objective: This article aims to report the clinical case of a female patient, 19 years of age, underwent orthodontic treatment. After three years of treatment in the clinical and radiographic examination was verified the presence of internal root resorption in the tooth #22, which was asymptomatic. **Methods:** Pulpectomy and changes of calcium

hydroxide curative was performed. After six months of the beginning of treatment, with the tooth asymptomatic, radiographically stable and no bleeding, was performed the fill of the pulp cavity with white MTA. In esthetic recovery of the element, was chosen subepithelial connective tissue graft through the technique of plastic and microsurgery, subsequently a direct facet of composite resin was made. **Conclusion:** Therefore, it can be concluded that the clinical and radiographic control of patients undergoing orthodontic treatment is important in the diagnosis of internal resorption. The White MTA presented itself as an excellent alternative for treatment of internal resorption, assisted with esthetic treatments.

Keywords: Root resorption. Root canal obturation. Esthetics.

How to cite this article: Morais CAH, Candido AG, Pires LC, Pascotto RC. The use of white MTA in the treatment of internal root resorption: Case report. *Dental Press Endod.* 2012 Oct-Dec;2(4):51-6.

¹Associate Professor of Endodontics, Department of Dentistry, Maringá State University.

²MSc student of Integrated Dentistry, PGO, Maringá State University.

³Associate Professor of Dentistics, Department of Dentistry, Maringá State University.

» The authors report no commercial, proprietary or financial interest in the products or companies described in this article.

Received: August 14, 2012. Accepted: August 20, 2012.

Contact address: Carlos Alberto Herrero de Morais
Rua Macapá, 63 – Jardim Social – Maringá/PR – Brazil
CEP: 87.010-010 – caherrero@endodontiamaringa.com.br

Introduction

Root resorption is characterized by the loss of hard dental tissues by the action of clastic cells (osteoclasts, odontoclasts and dentinoclasts).^{2,16}

Internal root resorption is a relatively rare occurrence,^{4,9,12,14,16,20} generally asymptomatic,^{1,3,4,5,8,11-14,16,17,18} and is detected in routine radiographic exams,^{1-5,8,11,12,14,17-20} in which it appears as a radiolucent^{1,3,4,12,14,16,18} and uniform^{1,4,14} lesion.

When this pathology has been diagnosed — if the tooth is considered restorable and has a reasonable prognosis —, endodontic treatment is the treatment of choice,¹⁶ and must begin as quickly as possible to limit the progression of internal resorption.⁸

Selection of the suitable restorative material for cases of root perforation continues to be a challenge, especially if there is extensive tooth loss.¹¹ Various biomaterials have been used to seal root perforations, among them MTA has gained popularity due to its biocompatibility,^{1,4,7,11,15,18} potential to induce osteogenesis and cementogenesis,¹⁹ sealing capacity superior to that of other materials,^{1,4,11,14,15,18} mechanical strength,¹⁹ capacity to promote healing of the peri-radicular tissues,¹⁹ bactericidal activity,^{14,18} capacity for adhesion in the presence of blood,^{14,18} radiopacity,^{4,14} resistance to humidity,⁴ in addition to being well tolerated by the tissues.⁹

Due to its excellent physical and biologic properties, MTA has been used in various clinical situations, such as: pulpotomy,^{1,7,11,15,18} pulp capping,^{1,7,11,15} cases of root perforation,^{1,4,11,14,15,18} apexification,^{7,14,18} root canal filling,^{14,15} and in root resorptions.^{4,11}

White MTA has a reduced setting time, increases the fracture resistance of a weakened tooth, in addition to being of a color similar to that of the tooth.¹⁹

The aim of this article is to report a clinical case of internal root resorption with root perforation, using white MTA as reparative material.

Case report

The patient, a 19-year-old woman, was indicated for endodontic treatment after radiographic analysis of tooth #22, as it presented no clinical signs or symptoms. In anamnesis, the patient reported that she had undergone orthodontic treatment for three years.

In the clinical exam, tooth #22 did not respond to the test for pulp sensitivity to cold, and in the radiographic exam (Fig 1) the presence of an oval-shaped

bone rarefaction was verified in the middle third of the root, which characterized internal root resorption.

The patient was informed of the diagnoses, treatment and prognosis, which could even compromise maintenance of the tooth, seeing that communication of the internal resorption with the alveolar bone had been visible in the initial radiograph.

After coronal opening and access to the root canal, pulpectomy was performed with Hedström files, with the aid of ultrasound, odontometry, irrigation with sodium hypochlorite and final irrigation with physiological solution and dressing with $\text{Ca}(\text{OH})_2$ paste and distilled water. There was abundant bleeding, characteristic of teeth with internal root resorption. The presence of dystrophic calcification did not allow access to the apical third of the root (Fig 2).

In the second week, the second session was performed, with instrumentation of the canal up to #80 file, irrigation with sodium hypochlorite and final irrigation with physiological solution activated by ultrasound and dressing with $\text{Ca}(\text{OH})_2$ paste, propylene glycol and iodoform. The canal was filled, using a 1.2 ml special syringe and 0.17 Capillary Tip (Ultradent®) (Fig 3). As the patient presented sensitivity, 500 mg of naproxen every 12 hours for 3 days was prescribed.

After this a new appointment was made to change the $\text{Ca}(\text{OH})_2$ dressing for 15 days, then another three changes every 30 days and a final change at 60 days, all performed with canal instrumentation, irrigation with sodium hypochlorite and final irrigation of physiological solution activated by ultrasound and dressing with $\text{Ca}(\text{OH})_2$ paste (Fig 4).

After the period of 6 months from the beginning of treatment, and finding that the tooth was asymptomatic, without bleeding and the internal resorption radiographically stable, including the formation of mineralized tissue in the area of communication of the internal cavity with the periodontium, the internal pulp cavity was filled with white MTA (Ângelus - Londrina - PR, Brazil) with the aid of calibrated shims of the Schilder type (Fig 5).

Clinical/radiographic control was continued for one year after beginning with the clinical treatment (Fig 6). The tooth was shown to be stable, without signs and symptoms and with absence of apical rarefaction, however, with perceptible change in color, especially

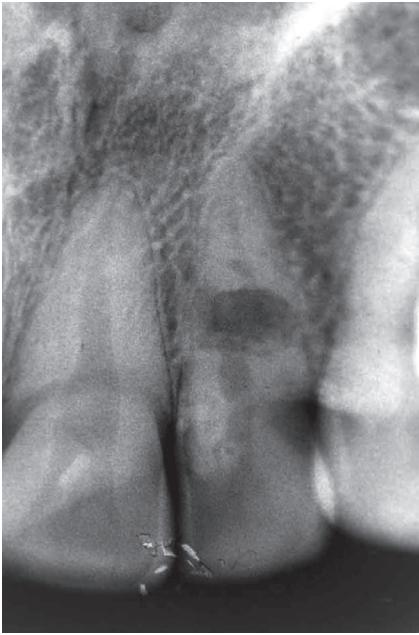

Figure 1. Initial radiograph of tooth #22, evidencing internal resorption.

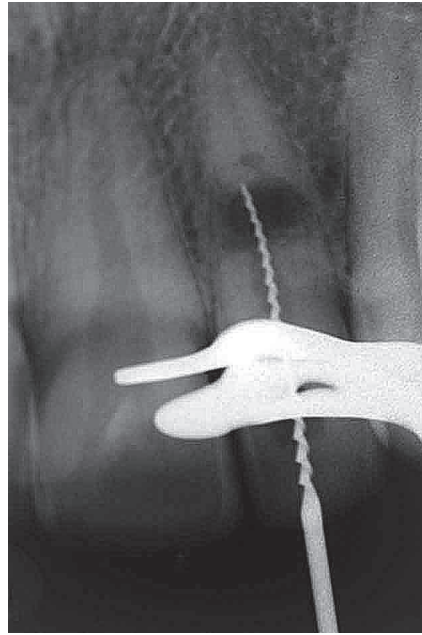


Figure 2. Odontometry and emptying of root canal with the aid of a Hedström file and ultrasound.

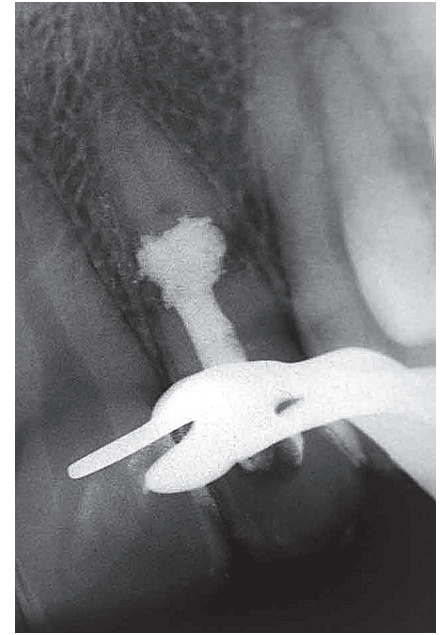


Figure 3. Radiograph showing root canal filling with Ca(OH)₂ paste and iodoform.

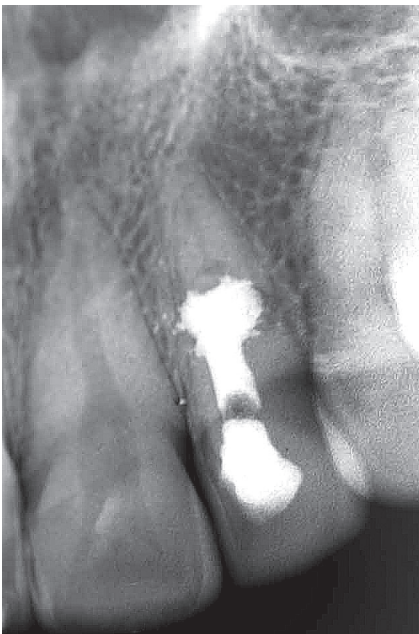


Figure 4. Radiograph showing root canal filling with Ca(OH)₂ paste and iodoform, 15 days after the first session.

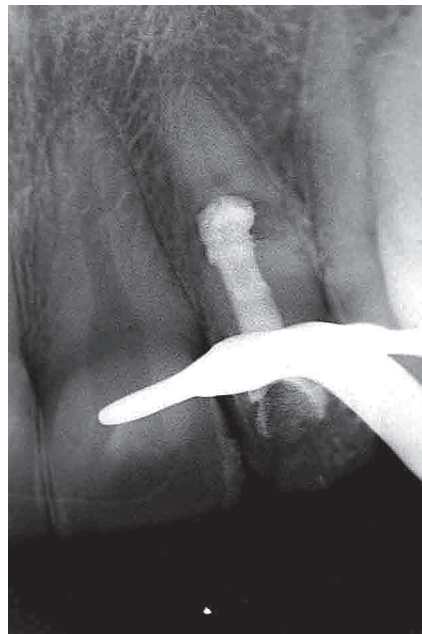

Figure 5. Radiograph showing root canal filling with white MTA. It can be observed the formation of mineralized tissue.

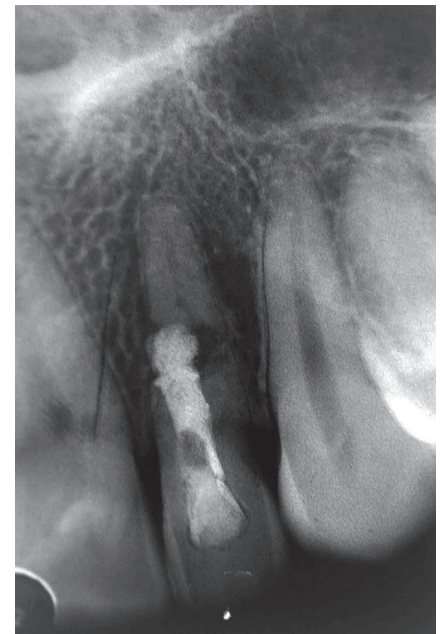


Figure 6. Follow-up radiograph after one year of treatment.

in the cervical third (Fig 7). As a minimally invasive alternative for the esthetic recovery of this tooth, initially the option was to place a subepithelial conjunctive tissue graft, by means of the micro plastic surgery tech-

nique, in order to increase the thickness of the inserted gingiva, helping to mask the root discoloration at the gingival margin (Fig 8) and afterwards, the fabrication of a direct facet made of resin composite (Fig 9).

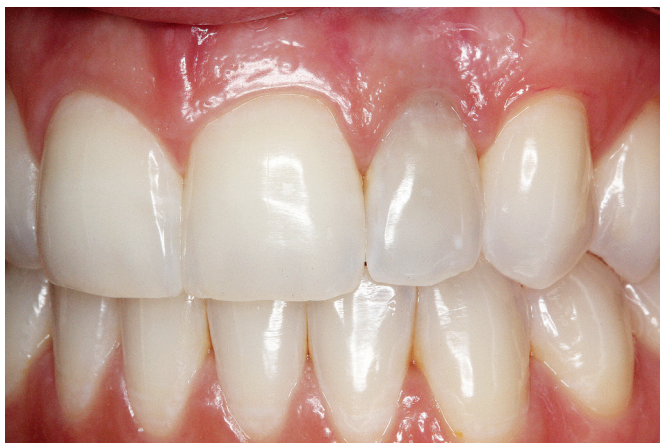

Figure 7. Lateral view, evidencing the darkening of tooth #22, mainly on cervical.

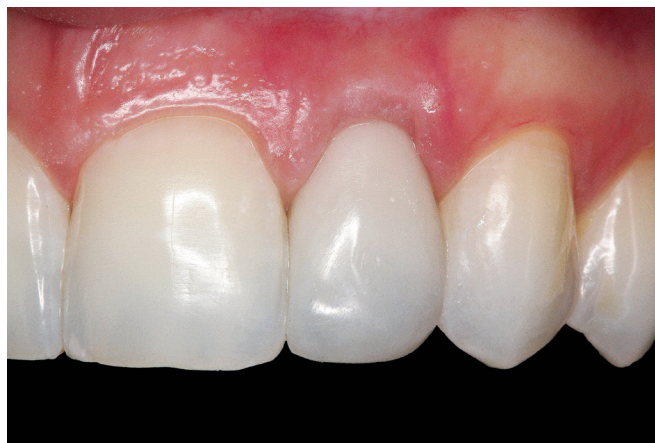

Figure 8. Clinical aspect of right facet in composite resin, performed after the graft for increasing gingival thickness of tooth #22.

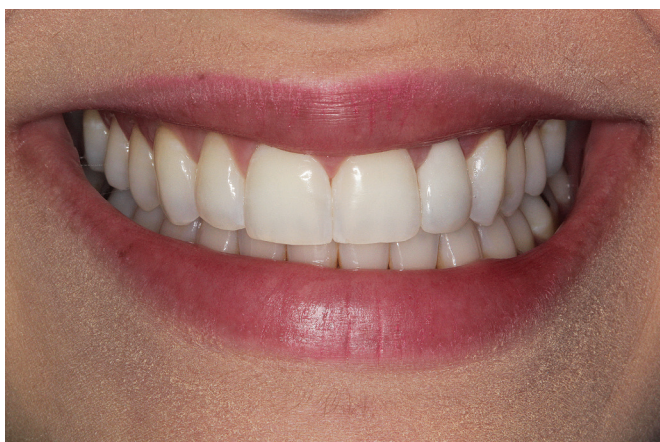

Figure 9. Final aspect of smile, preserving the element #22 and reestablishing anterior esthetics.

Discussion

Although its etiology and pathogenesis have still not been completely elucidated,¹⁶ some factors have been proposed for the development of internal root resorption, such as trauma,^{8,9,12,13,14,16,19} excessive heat generated during denting cutting,^{9,14,16,19} resection of the roots,¹⁶ and other iatrogenic causes. When there is no specific cause, it is denominated idiopathic internal root resorption.¹⁸ These factors stimulate the pulp tissue, leading to the development of inflammation, and after this, some cells within the pulp differentiate into osteoclasts and macrophages, resulting in dentinal resorption.¹³

The cement acts to protect the external root surface. The pre-dentin and odontoblast layers act to prevent the resorption of dentin. However, the pulp inflammation may lead to loss of the pre-dentin and odontoblast layers, thus permitting resorption by the clastic cells.² The internal aspect of the root canal is resorbed by the action of multinucleated giant cells which are adjacent to the granulation tissue of the inflamed pulp.^{1,12}

Orthodontic movement has been associated with some alterations in the dentin-pulp complex, such as interruption of the odontoblast layer, alteration in the microcirculation of the pulp and hypoxia. Depending on the duration, type and magnitude of force, these alterations may affect the pulp tissue in a reversible or irreversible manner. Orthodontic forces are capable of triggering a cell response similar to that observed during caries progression, cavity preparation and occlusal trauma.⁶ This may have occurred in the case presented, involving tooth #22, which led to the appearance of internal root resorption, however, as it did not present signs and symptoms, late diagnosis was made. Irrespective of the trigger factor (trauma, orthodontic treatment or some other factor), there is a general consensus that in order for progression to occur, internal root resorption depends on two situations: the pulp tissue in the area of resorption must be vital, and the coronal pulp must be completely or partially necrotic so that resorption occurs, because it allows the bacterial infection and microbial antigens to enter into the root canal. Microbial stimulation is

necessary for the continuation of inflammatory internal root resorption.⁹ Nevertheless, a negative pulp sensitivity test cannot be obtained as a result of the presence of necrotic pulp tissue in the coronal portion of the root canal,¹² as occurred in the clinical case described, in which tooth #22 did not respond to the sensitivity to cold test.

After the diagnosis of internal root resorption, the treatment must be started rapidly, with the objective of removing any vital remnant of apical tissue and necrotic coronal portion of the pulp, which may be sustaining and stimulating the resorption cells by means of their blood supply.¹⁶ Therefore, coronal opening of tooth #22 was immediately instituted in order to empty the pulp cavity, using Hedström files and ultrasound. According to Jacobovitz,¹¹ when blocking the activities of the cells responsible for the resorption process, one avoids greater loss of hard tissue, in addition to preventing this loss from attaining the external surface of the root, resulting in root perforation,¹⁴ and destruction of the adjacent periodontal tissues.^{3,14} However, in the case of tooth #22, when the diagnosis was made, communication between the pulp cavity and the alveolar bone had already occurred.

In the treatment of teeth with internal root resorption, there is a great deal of bleeding due to the presence of a part of the pulp that is alive, which may make it difficult to visualize access to the canal. By means of irrigation with sodium hypochlorite, one obtains a reduction in bleeding, thus facilitation visualization of, and access to the canal.⁹ Calcium hydroxide may also be used to control the bleeding; in addition to this, it acts on necrotizing the residual pulp and causes the necrotic tissue to become more soluble in the sodium hypochlorite.⁹ Calcium hydroxide has properties such as antibacterial action to destroy microorganisms, dissolution of tissues, stimulating the formation of hard tissues and inhibiting clastic cells.¹⁷

The irregularities present in the root canal system, especially in internal root resorption defects, make it difficult to clean and fill the root canal. The persistence of organic rests and bacteria in these irregularities may interfere in the success of endodontic treatment in the long term.¹⁸ The removal of vital tissues from the resorption gaps is aided by irrigation with

sodium hypochlorite and the use of calcium hydroxide paste, filling the entire canal and resorption gap, leading to necrosis of any remaining tissue present in this region, and causing these tissue remainders to be removed by means of the irrigation with sodium hypochlorite.²⁰ In the clinical case of tooth #22, irrigation with ultrasound and calcium hydroxide dressings were used to promote adequate cleaning and induce repair by hard tissue deposition.

MTA may create an environment favorable to periodontal cure, allowing the growth of cement on its surface.¹ The clinical use of MTA in humans has demonstrated its applicability in a humid environment, preventing bacterial infiltration and alkalization of the medium. On account of the presence of calcium oxide in its formulation, it has biologic properties similar to those of calcium hydroxide, making it useful for healing the tissue.¹¹ This is why MTA was elected the filling material in the clinical case of tooth #22.

One of the disadvantages of MTA is related to its color.¹ The original formulation, gray MTA, may cause a gray line that may be visible through the tooth structure.¹⁰ White MTA was introduced in 2002 for use in esthetic areas.¹⁰ With the introduction of white MTA on the market, the problem of discoloration was resolved.¹ Because we used white MTA in the clinical case of tooth #22, in spite of a year having passed, there was a discrete discoloration of the tooth, and it was necessary to perform a graft to increase the thickness of the gingiva, and afterwards place an esthetic facet.

Conclusions

Performing clinical and radiographic control of teeth in patients submitted to orthodontic treatment is important in the diagnosis of internal root resorption.

With the use of adequate techniques for emptying the pulp cavity, irrigation activated with ultrasound and medications that help with hemostasis, high success rates may be obtained in the treatment of teeth with internal resorption.

The use of white MTA was shown to be an excellent alternative filling in internal resorptions with great destruction and communication, as occurred in this case, and with a favorable prognosis for the maintenance of the tooth.

References

1. Altundasar E, Demir B. Management of a perforating internal resorptive defect with mineral trioxide aggregate: a case report. *J Endod.* 2009;35(10):1441-4.
2. Bhuvu B, Barnes JJ, Patel S. The use of limited cone beam computed tomography in the diagnosis and management of a case of perforating internal root resorption. *Int Endod J.* 2011;44(8):777-86.
3. Brito-Júnior M, Quintino AFC, Camilo CC, Normanha JA, Faria-e-Silva AL. Nonsurgical endodontic management using MTA for a perforative defect of internal root resorption: report of a long term follow-up. *Oral Surg Oral Med Oral Pathol Oral Radiol Endod.* 2010;110(6):784-8.
4. Brun DF, Scarparo RK, Kopper PMP, Grecca FS. Internal inflammatory root resorption and apex treated with MTA: a case report. *Rev Odonto Ciênc.* 2010;25(2):213-5.
5. Caliskan MK, Turkun M. Prognosis of permanent teeth with internal resorption: a clinical review. *Endod Dent Traumatol.* 1997;13(2):75-81.
6. Caviedes-Bucheli J, Moreno JO, Ardila-Pinto J, Toro-Carreño HR, Saltarín-Quintero H, Sierra-Tapias CI, et al. The effect of orthodontic forces on calcitonin gene-related peptide expression in human dental pulp. *J Endod.* 2011;37(7):934-7.
7. Clauder T, Shin SJ. Repair of perforations with MTA: clinical applications and mechanisms of action. *Endod Topics.* 2009;15(1):32-55.
8. Culbreath ET, Davis GM, West NM, Jackson A. Treating internal resorption using a syringeable composite resin. *J Am Dent Assoc.* 2000;131(4):493-5.
9. Haapasalo M, Endal U. Internal Inflammatory root resorption: the unknown resorption of the tooth. *Endod Topics.* 2006;14(1):60-79.
10. Hawley M, Webb T, Goodell GG. Effect of varying water-to-powder ratios on the setting expansion of white and gray mineral trioxide aggregate. *J Endod.* 2010;36(8):1377-9.
11. Jacobovitz M, Lima RKP. Treatment of inflammatory internal root resorption with mineral trioxide aggregate: a case report. *Int Endod J.* 2008;41(10):905-12.
12. Keinan D, Heling I, Stabholtz A, Moshonov J. Rapidly progressive internal root resorption: a case report. *Dent Traumatol.* 2008;24(5):546-9.
13. Kinomoto Y, Noro T, Ebisu S. Internal root resorption associated with inadequate caries removal and orthodontic therapy. *J Endod.* 2002;28(5):405-7.
14. Meire M, De Moor R. Mineral trioxide aggregate repair of a perforating internal resorption in a mandibular molar. *J Endod.* 2008;34(2):220-3.
15. Parirokh M, Torabinejad M. Mineral trioxide aggregate: a comprehensive literature review – Part III: clinical applications, drawbacks, and mechanism of action. *J Endod.* 2010;36(3):400-13.
16. Patel S, Ricucci D, Durak C, Tay F. Internal root resorption: a review. *J Endod.* 2010;36(7):1107-21.
17. Rossi-Fedele G, Figueiredo Jap, Abbott PV. Teeth with double internal inflammatory resorption: report of two cases. *Aust Endod J.* 2009;36(3):122-9.
18. Sari S, Sonmez D. Internal resorption treated with mineral trioxide aggregate in a primary molar tooth: 18-month follow-up. *J Endod.* 2006;32(1):69-71.
19. Silveira FF, Nunes E, Soares JA, Ferreira CL, Rotstein I. Double "pink tooth" associated with extensive internal root resorption after orthodontic treatment: a case report. *Dent Traumatol.* 2009;25(3):43-7.
20. Urban D, Mincik J. Monozygotic twins with idiopathic internal root resorption: a case report. *Aust Endod J.* 2010;36(2):79-82.