

Influence of coronal opening in the location of root canals in mandibular incisors

Renata Carvalho Cabral de **VASCONCELLOS**¹

Vandson Ferreira **BARBOSA**²

Inês de Fátima de Azevedo Jacinto **INOJOSA**³

José Lécio **MACHADO**⁴

Roberto Alves dos **SANTOS**⁵

Rebeca Ferraz de **MENEZES**⁶

Natália Maria Luccas Tenório **SOARES**⁶

ABSTRACT

Objective: This study evaluated the influence of shapes of coronary opening on the localization of root canals in lower incisors. **Methods:** It were used 32 teeth extracted from humans, being 16 with a single canal and 16 with two root canals that received, initially, conservative oval coronary opening, followed by random setting on mannequin, for clinical evaluation of number of root canals by two specialists. After that, the openings were enlarged to non-conservative triangular shape, being submitted to a second clinical evaluation regarding the number of root canals. **Results:** On the examination of the conservative opening, the examiners 1 and 2 obtained, respectively, 15(94%) and 14(87%) scores for the teeth with one

canal, with none (0%) and 5 scores (31,2%) for the teeth with two canals. After enlarging the opening, the examiners 1 and 2 obtained, respectively, 16 scores (100%) in cases with one canal, with 5 (31,2%) and 10 (62%) scores in cases with two canals. Between the examiners, on the non-conservative opening it was obtained Kappa = 0,456 and, on the conservative, Kappa = 0,629, determining mild concordance. According to results, the non-conservative triangular coronary opening lead to a greater percentage of scores on the localization of canals of lower incisors than the oval conservative opening, being this difference statistically significant ($p < 0,05$).

Keywords: Root canal preparation; Endodontics; Pulp cavity.

How to cite this article: Vasconcellos RCC, Barbosa VF, Inojosa IFAJ, Machado JL, Santos RA, Menezes RF, Soares MMLT. Influence of coronal opening in the location of root canals in mandibular incisors. *Dental Press Endod.* 2012 July-Sept;2(3):74-9.

¹MSc student in Endodontics, FOP/UPE.

²Graduated in Dentistry, FOUFAL.

³Assistant Professor IV, FOUFAL.

⁴Assistant Professor, FOUFAL.

⁵Assistant Professor IV, FOP/UPE.

⁶MSc student in Endodontics, FOP/UPE.

» The authors report no commercial, proprietary or financial interest in the products or companies described in this article.

Submitted: September 16, 2012. / Accepted: September 20, 2012.

Contact address: Renata Carvalho Cabral de Vasconcellos
Rua Hélio Pradines, 475 – Edif. Pêrgamo, Apto 802 – Ponta Verde – Maceió/AL
CEP: 57035-220 – Email: recarvalhocabral@hotmail.com

Introduction

The clinical access to the root canals system, obtained through an opening ideally planned and performed on the tooth crown, aims not only to access the pulp chamber but to prepare it properly to locate and explore the root canals that will be submitted to procedures of cleaning, modeling and obturation of the canals system, contributing for the success of the treatment.

On the opening of lower incisors, a single root canal with larger vestibulolingual dimension is localized in most cases, however, such teeth may present two root canals (buccal and lingual) in an incidence ranging from 11,5 to 45,0% according to the studies performed by Madeira and Hetem,¹ Benjamin and Dowson,² Kartal and Yanikoglu³ and Oliveira et al.⁴

For Buchanan,⁵ the traditional or classic access cavity that involves all the circumference of the pulp chamber in a triangular or oval shape, results in an access 50% larger than the necessary, which means a huge waste of healthy dental structure. Thus, it is recommended that during access of anteroinferior teeth the shape of the contour be oval, with conservative detrition of 1,5 mm on the mesiodistal direction. However, Nielsen and Shahmohammadi⁶ mentioned that the appropriate shape of access depends more of the anatomy itself and on the case of lower incisors, considerable attention must be given on the preparation of the access cavity in order to locate two canals. Therefore, to enlarge mesiodistally more than 1 mm is reasonable, if it is necessary to obtain adequate visualization and instrumentation of the canal.

According to Peters,⁷ the openings errors usually are originated from openings shorter or longer than the necessary. Small openings may not lead the professional to find the canals, or if it was found and not with a straight access, it increases the chances of file fracture or canal transportation. Very large cavities usually originate unnecessary removal of dental structure and weaken the remaining crown, maybe causing, in the long term, irreparable compromising of the dental element.

Before this, the present work has as objective to compare whether conservative oval coronary opening and non-conservative triangular coronary opening affect the localization of root canals in lower incisors.

Material and Methods

It were used human permanent lower incisors, granted by the Bank of Teeth of the Federal University of

Alagoas (FOUFAL), not being recorded the reason of extraction, the antimere, age, gender and race of the patient. The project was approved by the Committee of Ethics in Research (CER) under the protocol number 000470/2011-85.

Took part in the survey only the lower incisors with healthy crowns or with small restorations on the proximal surfaces with no implication on the pulp chamber, carriers of healthy roots, free of calcifications on the pulp cavity, having one or two root canals with bifurcation on the cervical third. To confirm the absence of calcification, as well as the number of canals, it were performed digital radiographs from mesial to distal and from buccal to lingual using an x-ray device (Intra-oral Focus, Kavo[®]), of 60 kVp and 10 mA, set for 0,3 seconds of exposure (Fig 1).

A total of 32 lower incisors, being 16 with a single canal and 16 with two root canals (buccal and lingual) were used. To evaluate if the shape of the opening affected the localization of root canals, all samples had their accesses done in conservative way (oval conservative group), followed by clinical evaluation by two examiners specialists in Endodontics. Completed this step, the same teeth received an additional detrition in their openings, originating the second group (triangular non-conservative group), for posterior clinical evaluation regarding the number of root canals.

On the oval conservative coronary opening it was used a high rotation spherical diamond tip, number 1011 (KG Sorensen[®]) to work in enamel on the center of the lingual surface, aiming to obtain an oval shape with

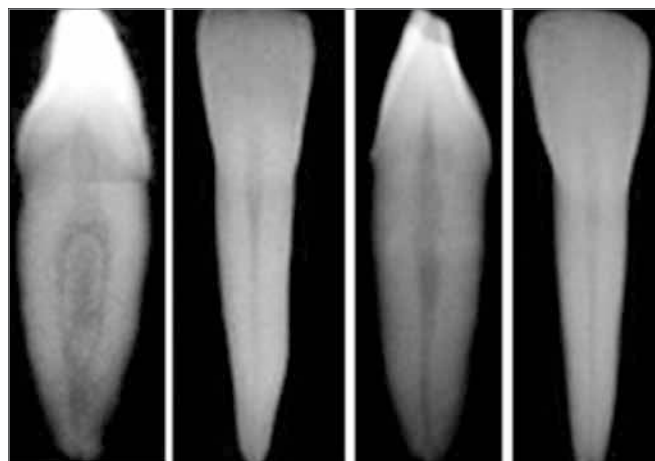


Figure 1. Periapical radiographs of two samples, on vestibulolingual (VL) direction and mesiodistal (MD) direction to confirm the absence of calcification as well as the number of canals.

larger cervico-incisal diameter, which went from the incisal edge to an area above the cingulum. After giving the initial oval shape, the pulp chamber was perforated with the spherical tip and, with a conical diamond tip of inactive extremity, number 3028 (Kg Sorensen®), in high rotation, it was removed the roof of the pulp chamber and buccal interference, slightly inclining the diamond tip to the incisal edge of the opening. Then, it was performed the detrition of the lingual dentin located underneath the cingulum. The mesiodistal width of the conservative opening was between 1,0 and 1,25 mm (Fig 2).

On the triangular non-conservative coronary opening the oval contour shape was enlarged with the same diamond tip 3028 (KG Sorensen®), leaving the proximal walls of the access slightly devious to incisal. On the incisal edge of the opening it was performed a bevel aiming to comprise the incisal edge of the tooth and, cervically, the opening was extended to the cingulum area, receiving an additional detrition of the dentin located on the lingual wall of the opening. The mesiodistal extension of the opening was between 1,5 and 2 mm (Fig 3).

For examination of the number of root canals, the incisors with one and two canals, previously identified, were randomly positioned on the anteroinferior segment of a mannequin for periodontia (Prodens®) and evaluated in both moments by two specialists in Endodontics with different periods of experience (the observer 1 with 7 years of experience and the observer 2 with 25 years of experience).

With the mannequins properly positioned on the dental chair and under lighting from a floodlight

(Gnatus, Persus Simple), each observer received a form for identification of dental elements, plane dental mirror, an endodontic probe and files type K #10 of 21 mm (Dentsply Maillefer) to explore and identify the number of root canals.

For analysis of agreement inter and intraexaminers it was used the Kappa index and for comparison of the results obtained with different types of openings it was used the McNemar test ($p = 0,05$).

Results

On Table 1, it was observed that on the conservative opening the examiners 1 and 2 obtained, respectively, 94% and 97% of scores on the identification of cases with a single canal, obtaining 0 and 31% of scores in cases with two canals. Besides, from the 16 cases that had a single canal, the examiners 1 and 2 mistakenly classified one and two teeth as carriers of two root canals, respectively. After examined the enlarged openings (triangular non-conservatives), the examiners 1 and 2, respectively, obtained scores of 5 (31,2%) and 10 (62%) of the 16 cases with two canals, with 100% of score for the cases with a single canal.

Table 2 shows that the examiner 1 obtained 15 scores and 11 errors on the localization of the canals on the same teeth on the two shapes of opening (oval and triangular). However, with the six errors occurred on the examination of the teeth with conservative openings, it occurred scores when they were examined after enlarging the cavity. To compare the results obtained by examiner 1, it was used McNemar test, obtaining a p value



Figure 2. Conservative oval opening.

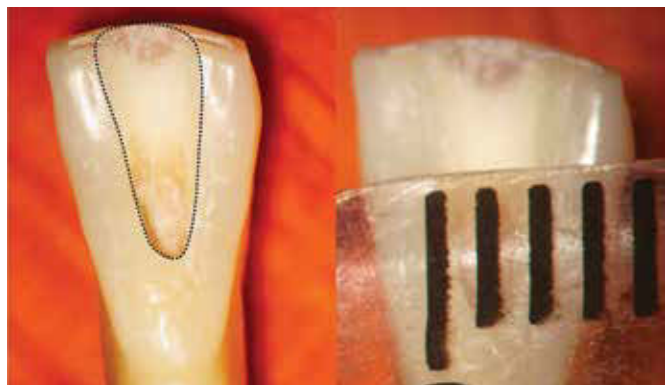

Figure 3. Non-conservative triangular opening.

Table 1. Identification of root canals in lower incisors with conservative and non-conservative opening.

	Coronary opening			
	Conservative (oval)		Non-conservative (triangular)	
	Examiner 1	Examiner 2	Examiner 1	Examiner 2
Scores / single canal (n = 16)	15 (94%)	14 (87%)	16 (100%)	16 (100%)
Scores / two canals (n = 16)	0 (0%)	5 (31%)	5 (31%)	10 (62%)
Scores / total (n = 32)	15 (47%)	19 (59%)	21 (66%)	26 (81%)

Table 2. Results of Examiner 1 on the identification of canals of incisors with conservative and non-conservative coronary opening.

	Conservative Oval		Total
	Score	Error	
Non-conservative Triangular			
Score	15	6	21 (65.6%)
Error	0	11	11 (34.4%)
Total	15 (46.9%)	17 (53.1%)	32 (100%)

Table 3. Results of Examiner 2 on the identification of canals of incisors with non-conservative and conservative coronary opening.

	Conservative (oval)		Total
	Score	Error	
Non-conservative Triangular			
Score	18	8	26 (81.3%)
Error	1	5	6 (18.7%)
Total	19 (59.4%)	13 (40.6%)	32 (100%)

of 0,031, which indicates the existence of significant difference between the techniques ($p < 0,05$), where the non-conservative coronary opening had a score percentage higher than the conservative opening. The coefficient of concordance between the techniques of opening to locate root canals for examiner 1 was Kappa = 0,632, indicating that there was mild concordance between the two techniques of coronary opening on the localization of root canals.

Table 3 demonstrates that for examiner 2 there were 18 scores and 5 errors both in oval conservative shape and triangular non-conservative shape, being observed that in 8 cases of error of conservative opening occurred scores when the cavity was enlarged. To compare the results, it was used McNemar test, with p value of 0,039, which indicates the existence of significant difference between the techniques ($p < 0,05$), where the triangular non-conservative coronary opening had a percentage of scores of 81,3% versus 59,4% of the oval conservative opening.

The coefficient of concordance between the techniques was Kappa = 0,363, indicating that for examiner 2 there was a low concordance between the two techniques of coronary opening on the localization of root canals. The coefficient of concordance between examiners 1 and 2 for triangular non-conservative opening was Kappa = 0,456 and, for oval conservative opening, was Kappa = 0,629, thus determining that examiners

1 and 2 presented mild concordance. The highest concordance of results between examiners on the determination of number of canals occurred in the shape of oval conservative opening because the number of errors was higher for both examiners in this stage. However, for both examiners the triangular non-conservative opening was more efficient than the conservative on the detection of number of canals.

Discussion

For the lower incisors with two canals Warren and Laws⁸ and Clements and Gilboe⁹ recommend that the coronary opening is performed by buccal or, according to LaTurno and Zillich,¹⁰ Mauger et al¹¹ and Johnson,¹² that the cavity is extended more to vestibular, once the opening by lingual will difficult the localization and exploration of the second canal because of the presence of prominent protuberance of the dentin in the cingulum area. About the extension of the cavity of access to vestibular, Mauger et al¹¹ concluded that on teeth with greater detrition of the incisal edge, the ideal place to obtain access in straight line switches from buccal to incisal edge. In this work the best results obtained on triangular shaped openings may have been affected by the involvement of the incisal edge of teeth in the access cavity, according to mentioned by authors that defend this approach.

On the other side, Janik states to be essential to extend the access cavity to the cingulum area to locate and properly debride the lingual canal, should radiographic evidences suggest the possibility of existing two canals in lower incisors. In agreement with this approach, are authors such as Ingle et al,¹⁴ Vertucci et al,¹⁵ Buchanan⁵ and Peters.⁷ Similar procedures were adopted in this study, where non-conservative openings had the cavity enlarged to the cingulum area, with greater detrition of the lingual dental wall, which may have facilitated the higher score obtained by the examiners in relation to the localization and determination of the canals in lower incisors.

Regarding the shape and size of the access cavity Stock,¹⁶ Ingle et al¹⁴ and Vertucci et al¹⁵ asserted that the external contour of coronary openings in lower incisors can be triangular or oval, depending on the prominence of the mesial and distal pulp horns. Ruddle¹⁷ recommends that the size of the access cavity is determined by the position of the inlet orifice of canals and, regarding the axial walls, he recommends that are laterally extended so that the orifice is in continuity with them. About this, Janik¹³ reports that in an overly small access, the file inserted in the tooth generally will freely pass on the buccal canal, not locating the lingual canal. Such fact was observed in the present work where the difficulty to locate two canals was greater in oval conservative openings, when compared to non-conservatives, for both examiners.

Corcoran et al¹⁸ demonstrated in a study that the professional experience affects the localization of additional canals. In the present work, by examining the dental elements with oval conservative coronary openings, no case that had two canals was identified by examiner 1 (less experienced). However, on the same conservative group, the examiner 2 (more experienced) scored 5 (31,2%) from the 16 cases that presented two root canals. When the same 16 teeth were examined in the second moment, i.e., after enlarging the conservative opening, the examiner 1 increased the scores, localizing in 5 (31,2%) from the 16 cases the two canals, and the examiner 2 scored 10 from the 16 cases that presented two root canals. On the conservative opening, 6,2% (1 tooth)

and 13% (2 teeth) from the 16 teeth that had single canal, were mistakenly classified as carriers of two canals by the examiner 1 and 2, respectively, not being observed cases of error on the identification of cases with one canal after obtaining the shape of triangular non-conservative opening, both for examiners 1 and 2.

This work shows the necessity for procedure of access on anterior inferior teeth with two canals present a greater amplitude on mesiodistal and cervico-incisal directions to facilitate the localization of the lingual canal. The non-involvement of the incisal edge, as well as of the cingulum area of the tooth on the cervico-incisal extension of the conservative oral opening, made it very difficult the localization of the second canal and, according to Janik,¹³ many times the preservation of the cingulum may lead to failure in locate the lingual canal, as well as the traditional access through lingual may leave a second canal without treatment, according to Warren and Laws⁸ and Clements and Gilboe,⁹ who defend the involvement of the vestibular surface or of the incisal edge on the opening of lower incisors. The small extension of the oval opening on the mesiodistal direction (1,0 a 1,25 mm), defended by authors such as Buchanan,⁵ may have injured the lighting and indirect inspection on the clinical examination of the teeth that had two canals, because its walls are not expulsive as on the non-conservative triangular openings, which allows better transition of the light reflected by the mirror to the inner part of the cavity. Besides, according to Nielsen and Shahmohammadi,⁶ to mesiodistally enlarge beyond 1 mm is reasonable if it is necessary to obtain the appropriate visualization and instrumentation of the canal.

Conclusion

Based in this study, it can be concluded that the non-conservative triangular coronary opening favors significantly the localization and determination of root canals of lower incisors when compared to conservative oval opening. However, as in none of both shapes of opening there was 100% of score on the localization of presence of two canals, additional researches are necessary to observe if coronary opening with buccal approach affect the localization of the second canal of lower incisors.

References

1. Madeira M, Hetem S. Incidence of bifurcations in mandibular incisors. *Oral Surg*. 1973;36:589-91.
2. Benjamin KA, Dowson J. Incidence of two root canals in human mandibular incisor teeth. *Oral Surg Oral Med Oral Pathol*. 1974;38(1):122-6.
3. Kartal N, Yanikoglu FC. Root canal morphology of mandibular incisors. *J Endod*. 1992;18(1):562-4.
4. OLiveira SHA, Moraes LC, Faig-leite H, Camargo SEA, Camargo CHR. In vitro incidence of root canal bifurcation in mandibular incisors by radiovisiography. *J Appl Oral Sci*. 2009;17(3):234-9.
5. Buchanan LS. Access procedures: breaking and entering safely and effectively. *Endod Ther*. 2006 [Access 2011 Mai 16]. Available from: http://www.endobuchanan.com/downloads/Access_Procedures.pdf
6. Nielsen CJ, Shahmohammadi K. The effect of mesio-distal chamber dimension on access preparation in mandibular incisors. *J Endod*. 2005;31(2):88-90.
7. Peters OA. Accessing root canal systems: knowledge base and clinical techniques. *Endod Pract Today*. 2008;2(2):87-104.
8. Warren EM, Laws AJ. The relationship between crown size and the incidence of bifid root canals in mandibular incisor teeth. *Oral Surg*. 1981;52(4):425-9.
9. Clements RE, Gilboe DB. Labial endodontic access opening for mandibular incisor: endodontic and restorative considerations. *J Can Dent Assoc*. 1991;57(7):587-9.
10. Laturno SAL, Zillich RM. Straight-line endodontics access to anterior teeth. *Oral Surg Oral Med Oral Pathol*. 1985;59(4):418-9.
11. Mauger MJ, Ware RM, Alexander JB, Schindler WG. Ideal Endodontic access in mandibular incisors. *J Endod*. 1999;25(3):206-7.
12. Johnson BR. Endodontic access. *Gen Dent*. 2009;57(6):570-7.
13. Janik JM. Access cavity preparation. *Dent Clin North Am*. 1984;28(4):809-19.
14. Ingle JI, et al. Endodontic cavity preparation In: Ingle, Jhon I, Bakland LK. *Endodontics*. 5th ed. Hamilton: Decker; 2002. p. 405-570.
15. Vertucci FJ, Haddix JE, Britto LR. Tooth morphology and access cavity preparation In: Cohen S, Hargreaves KM. *Pathways of the pulp*. 9th ed. St. Louis: CV Mosby; 2006. chapter 7.
16. Stock CJR. Anatomy and canal length measurement. *Int Endod J*. 1979;12 Suppl 1:37-44.
17. Ruddle CJ. Nickel-titanium rotary instruments: current concepts for preparing the root canal system. *Aust Endod J*. 2003;29(2):87-98.
18. Corcoran J, Apicella MJ, Mines P. The effect of operator experience in locating additional canals in maxillary molars. *J Endod*. 2005;33(1):15-7.