

# The use of calcium hydroxide as an intracanal medication for the apexification of immature permanent teeth

Jefferson José de Carvalho **MARION**<sup>1</sup>

Frederico Campos **MANHÃES**<sup>2</sup>

Thais Mageste **DUQUE**<sup>3</sup>

Suellen Denuzzi **ACHITTI**<sup>4</sup>

## ABSTRACT

The objective of this study was to present, through a clinical case, the treatment of two traumatized dental elements with incomplete root formation, extensive periapical lesion and root resorption. The treatment of choice for teeth with incompletely formed apices was the apexification by changing the intracanal medication to promote apical closure, periapical lesion repair as well as root resorption stabilization. The

intracanal dressing, calcium hydroxide paste mixed with propyleneglycol as a vehicle, was changed a total of four times during a period of one year and two months. It has been concluded that this technique for apexification provides favorable conditions for the closure of root apices as well as repairing periapical lesions and stabilizing root resorption.

**Keywords:** Apexification. Incomplete root formation. Calcium hydroxide. Intracanal dressing. Dental traumatism.

**How to cite this article:** Marion J, Manhães FC, Duque TM, Achitti SD. The use of calcium hydroxide as an intracanal medication for the apexification of immature permanent teeth: a case report. *Dental Press Endod.* 2012 July-Sept;2(3):67-73.

» The authors report no commercial, proprietary or financial interest in the products or companies described in this article.

<sup>1</sup>PhD student in Endodontics, UNICAMP. MSc in Endodontics, Marília University – UNIMAR.

<sup>2</sup>PhD student Doutor - Doutorando em Clínica Odontológica/Endodontia pela Universidade Estadual de Campinas - UNICAMP, Piracicaba, SP, Brasil, Professor da Faculdade de Odontologia São José - RJ.

<sup>3</sup>Mestre - Mestranda - em Clínica Odontológica/Endodontia pela Universidade Estadual de Campinas - UNICAMP, Piracicaba, SP, Brasil.

<sup>4</sup>Cirurgia Dentista - Faculdade Ingá - UNINGÁ, Maringá, PR, Brasil.

Recebido: August 10, 2012. Aceito: November 21, 2012.

Contact address: Jefferson José de Carvalho Marion  
Rua Neo Alves Martins, 3176 - 6ª andar - sala 64, Centro  
Cep: 87.013-060 - Maringá, PR, Brazil.  
Email: jefferson@jmarion.com.br; atendimento@jmarion.com.br

## Introduction

The eruption of the permanent dentition has its onset around the age of six, continuing until the age of twelve, with a root development for a continuous period of one year and a half to two and a half years after the eruption. Thus, trauma to the oral cavity in patients aged between six and fourteen and a half years old has a potential to disrupt, modify or intercept the complete formation of the root. The functional and aesthetic importance of the traumatized tooth with incomplete root formation associated with the young age of the patient, has motivated several studies in an attempt to ensure their stay for as long as possible in function. According Andreasen, literature review makes clear that school children have a high incidence of traumatic injuries in permanent teeth with incomplete root formation and can often develop pulp and periapical complications, developing pulp mortification, diffuse calcifications of the pulp, internal or external root resorption, even after a long period of time of the dental trauma. The disease and degenerative processes of these complications, however, are not well understood. When the incomplete root formation is associated with pulp necrosis, the situation becomes even more complicated because the process of root formation by deposition of dentin ends. In these cases, endodontic treatment is aimed to promoting the full apical closing. According Heithersay the apicification is a treatment which allows the apical closure and allows the root elongation if the Hertwig's epithelial sheath has not been irreversibly damaged. The disadvantage of this technique is that the time required for treatment is prolonged. Thus, in teeth with incompletely formed apex, the use of the instruments and auxiliary chemical substance does not allow a complete cleaning of the root canal, a unfavorable condition to tissue repair in the apical region, because the healing process only occurs in the absence of contamination. The auxiliary chemical substance, with its multiple properties, should provide an effective antimicrobial activity and increased the permeability of the root canal system in order to complete the cleaning. Numerous medications have also been used in endodontic treatment of teeth with incomplete root formation to complement the cleaning, emphasizing its capacity to diffusion in the

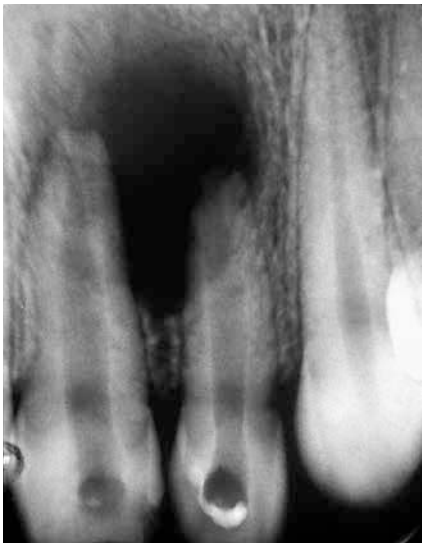endodontic system. According Estrela and Sydney, to achieve the apicification, must obtain an alkaline medium within the root canal system which facilitates the formation of a barrier apical of mineralized tissue even after the pulp had lost its vitality. Thus, the high pH of calcium hydroxide is fundamentally important for the success of treatment. Therefore, this work was carried out to verify the effectiveness of the apicification technique using the folder calcium hydroxide as intracanal dressing and observe the time required for closure apical of teeth 21 and 22 with pulpar necrosis, incompletely formed apex and root resorption

## Case Report

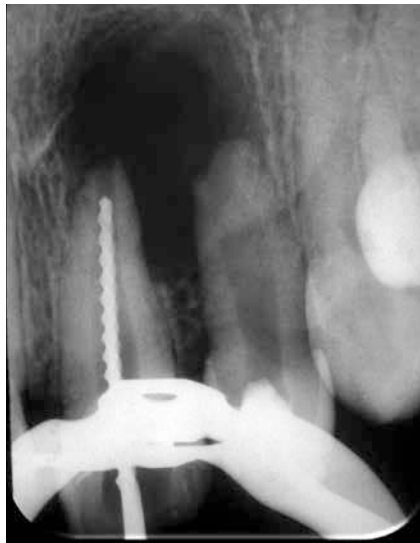Patient MP, female, 16 years old, attended the private clinic to perform endodontic treatment accompanied by his mother. During interview, when asked about dental history, was aware that with six-year-old the patient suffered a fall injuring the dental elements 21 and 22. Since then, the patient underwent several professionals who could not resolve the problem. In the intra-oral clinical examination, there was edema in the region of the palate and on the bottom of the hall in the region of the elements 21 and 22. Although it was noted that access cavities that were open were very retentive with presence of the roof of the pulp chamber. In the radiographic examination it was found that the teeth 21 and 22 had incomplete root formation, extensive radiolucent periapical and root resorption (Fig 1).

After the patient aware of the difficulties of, endodontic treatment has been proposed by apicification using calcium hydroxide. Agreeing with the proposed treatment, the first session was carried on 14/01/1998 by performing local anesthesia, rubber dam installation and improvement of access openings. The biomechanical preparation of root canal was done with hand endodontic files and sodium hypochlorite 2.5%. During root canal preparation, odontometry was performed to confirm the working length. In the two dental elements the patency was performed and the apical third was prepared with K # 80 files to 1mm from the radiographic apex (Figs 2 and 3).

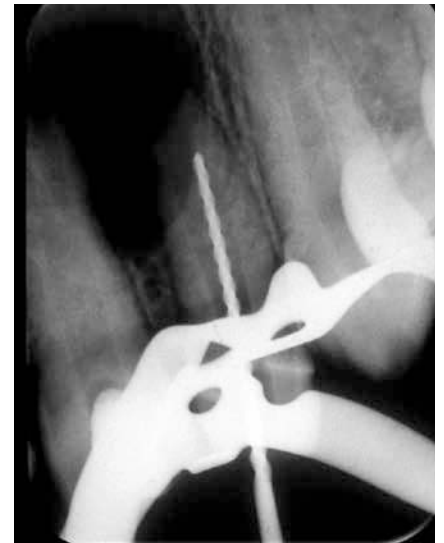After biomechanical preparation, the root canals were dried with sterile paper cones and flooded with EDTA trisodium 17% for three minutes. After removal



**Figure 1.** Initial radiograph showing incomplete root formation, extensive radiolucent periapical and root resorption.



**Figure 2.** Tooth 21 odontometry for confirmation of the working length.

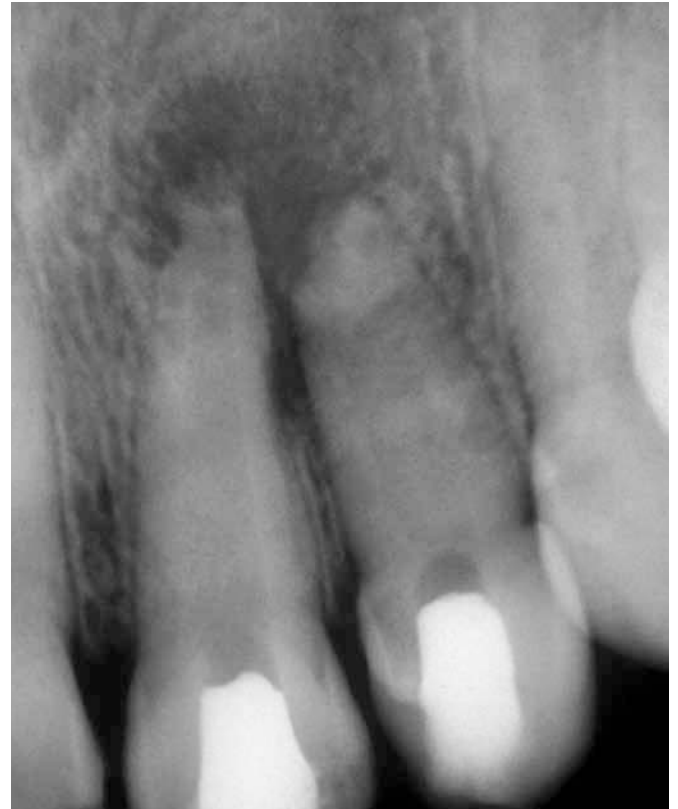

**Figure 3.** Tooth 22 Odontometry for confirmation of the working length.

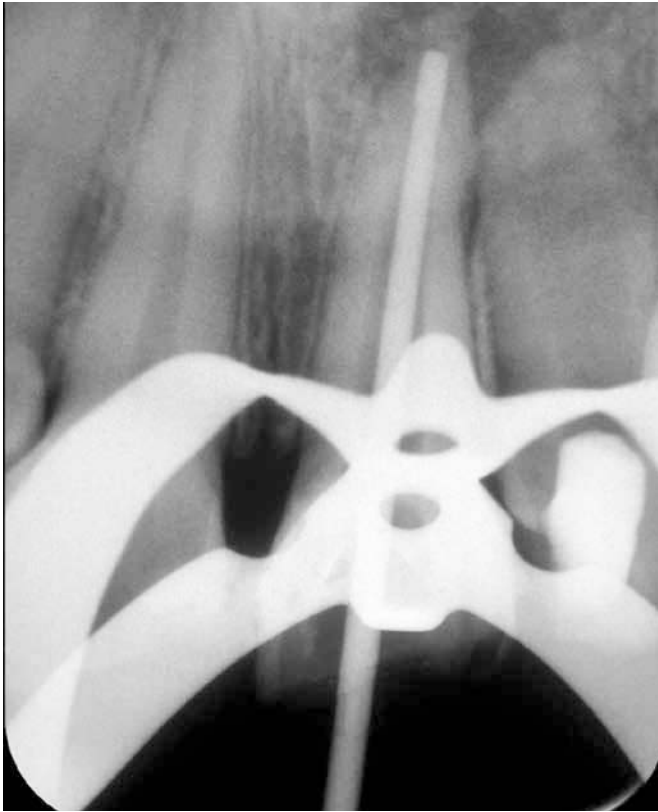
of EDTA, another drying was carried out. Calcium hydroxide paste P. A with propyleneglycol was inserted into the root canal, which is replaced when it appeared radiographically that the intra-canal medication had been partially resorbed. This was done to induce apicification or formation of a barrier mineralized in the apical foramen, as well as stabilization of root resorption. After four exchanges of intracanal dressing over a period of nine months, regression of the periapical lesion was observed radiographically, stabilization of resorptions and root closure (Fig 4).

In 20/03/1999, one and two months after the beginning of root canal treatment, was performed the final filling of the root canal with gutta-percha (Figs 5 and 6) and sealer with zinc oxide and eugenol (Endofill-Dentsply) by lateral condensation followed by vertical condensation (Fig 7).

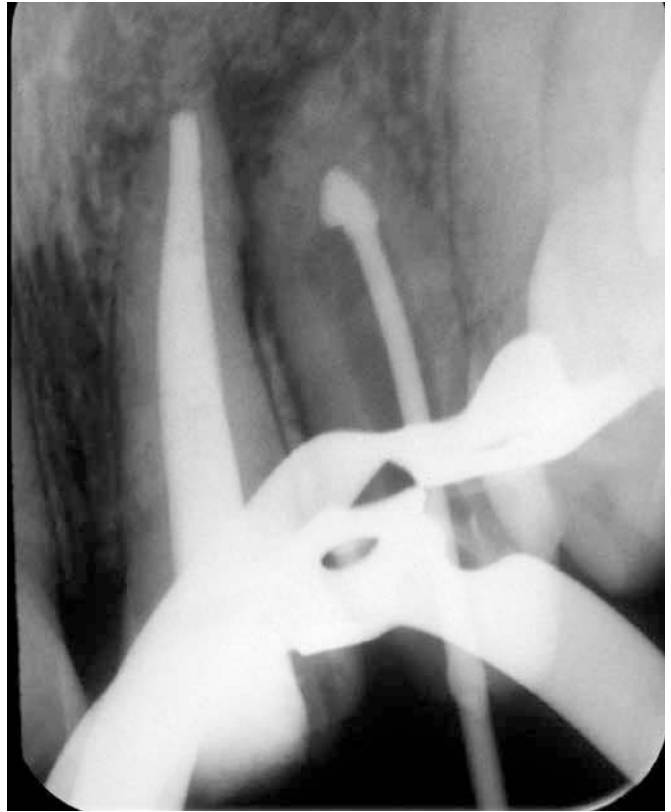
After three years of completion of treatment the patient was called for the first radiographic control, when radiographically it was observed repair of the periapical lesion with absence of root formation and root resorption. In element 21 in the third apical was possible to observe slight thickening of the periodontal ligament (Fig 8).



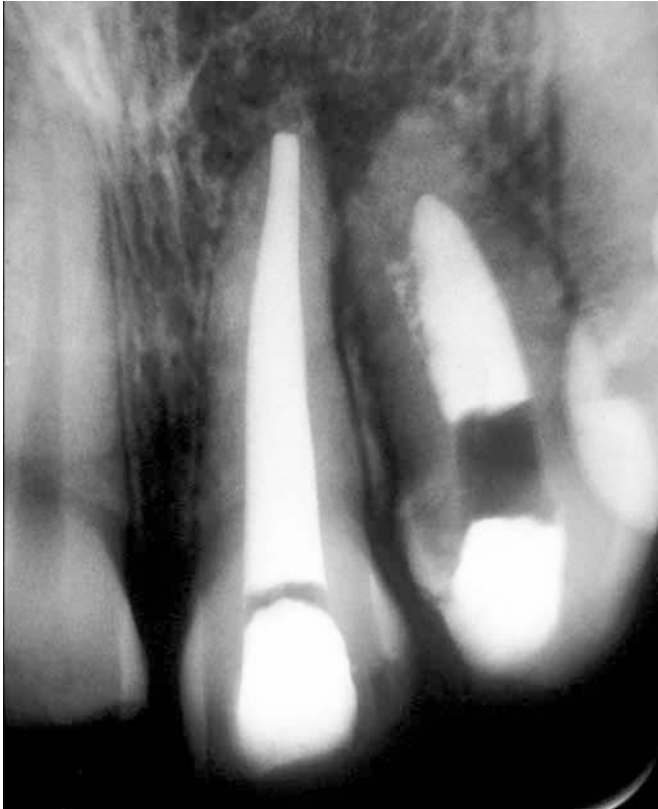**Figure 4.** Teeth with intracanal dressing after a period of nine months, showing regression of the periapical lesion, stabilization of the beginning of resorptions and root closure.



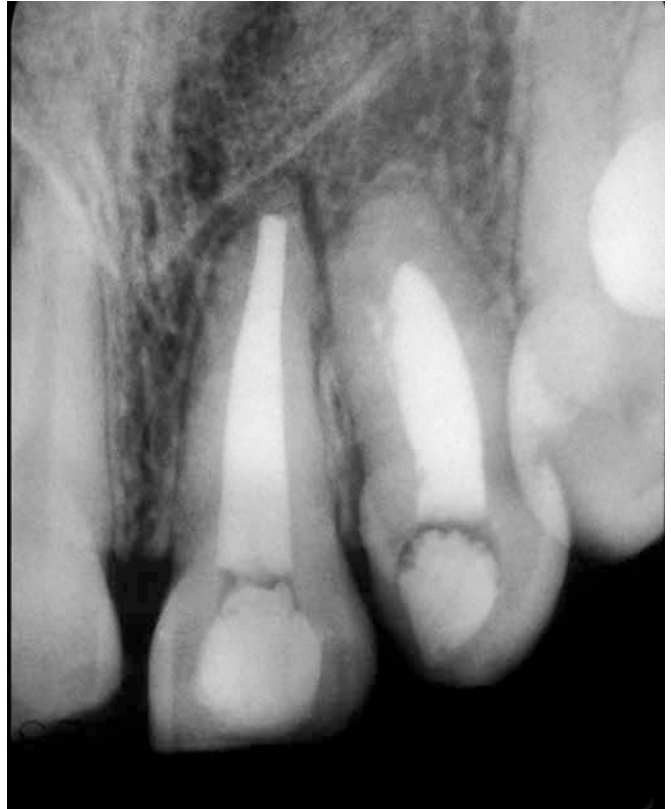**Figure 5.** Proof of the master cone, tooth 21.



**Figure 6.** Proof of the master cone, tooth 22.



**Figure 7.** Final root canal fillings after one year and two months of the beginning of the endodontic treatment.



**Figure 8.** Radiography of preservation after three years of root canal filling showing periapical lesion repair and absence of root formation and root resorption.

## Discussion

Young patients present as most frequent cause of pulp involvement besides caries, dental trauma due to accidents that may suffer.<sup>5</sup> Crona-Larsson and Noren<sup>6</sup> assessed the etiology, incidence, predisposition and occurrence of dental trauma. The authors report regarding gender was two boys for every girl and argued that the large number of traumatic injuries occurred between eight and eleven years old, and 40% of traumatized children suffer more than once dental trauma. Most cases involved the maxillary central incisors being responsible for 70% of traumatized teeth and a third of these teeth had the root partially developed at the time of the accident. Our work agrees with those reported in the literature since the injury occurred in this case report was when it was six years old and the roots of the teeth 21 and 22 had not reached the stage ten of Nolla, and was not acting the complete root development, with the pulp involvement with subsequent necrosis and periapical lesion development. The teeth of the reported case are carriers of chronic periapical lesions and incompletely formed apices. Accordingly, the endodontic therapy is faced with a complex root anatomy makes it difficult endodontic treatment, which is why we chose to start with sanitation removal of necrotic tissue and combat the bacterial infection through copious irrigation with sodium hypochlorite solution, due to its solvent properties of organic matter and antimicrobial.<sup>7,8</sup> The E.D.T.A. was used prior to application of the medication in every session and before the final filling of the root canal in order to increase the permeability of dentin and facilitate the diffusion of ions of calcium hydroxide on dentin, it is justified because it is large in literature the number of studies that use of EDTA at different concentrations and associations in order to promote a greater cleaning of the root canal walls, with the removal of the residual layer of magma dentinário.<sup>9,10</sup> The use of intracanal dressing with calcium hydroxide paste between sessions to complete disinfection and stimulate apical closure and / or deposition of mineralized tissue resorption and stabilize, corroborate with the study of Holland et al;<sup>11</sup> Holland et al;<sup>12</sup> Hulsmann;<sup>13</sup> Holland et al;<sup>14</sup> Nedley and Powers<sup>15</sup> and contrasts Felipe et al<sup>16</sup> who argued that there advantages to make exchanges of calcium hydroxide paste during treatment of teeth with

incomplete root formation and pulped canals contaminated. The choice of propyleneglycol as a carrier for the calcium hydroxide is based on studies of O'Neil<sup>17</sup> Lide,<sup>18</sup> which has a great capacity to solubilize organic materials and also because Seidenfeld Hanzlik,<sup>19</sup> propyleneglycol has approximately the same density as water and when used as solvent and vehicle is less toxic than ethyleneglycol with no demonstrable cumulative effect. The antimicrobial activity of the propyleneglycol for systemic use has been studied by Olitzky<sup>20</sup> who reported that concentrated solutions of this compound have a proven efficiency germicide and its use as a vehicle can provide a potential for the prevention or treatment of microbial infections. Thomas, Bath and Kotian<sup>21</sup> reported that addition of propyleneglycol as a vehicle is well recognized for pharmaceutical, it has also been shown to be less cytotoxic than other vehicles commonly used to intracanal dressing and has antibacterial properties highly beneficial in endodontic treatment. Cruz et al<sup>22</sup> reported that propyleneglycol has the ability to spread through the root dentin and cementum possibly even in the presence of anatomical abnormalities such as calcifications and istms. The authors also reported that propyleneglycol has been used in endodontics almost exclusively as a vehicle for cálcio hydroxide.<sup>23</sup> The authors concluded that propyleneglycol is an excellent vehicle for intracanal dressing. It opposes the results found by Safavi and Nakayama<sup>24</sup> who found that calcium hydroxide does not dissociate when in contact propyleneglycol because calcium hydroxide needs water to dissociate. The time to achieve the beginning of apical closure after initiation of treatment in this case was from nine months to a year and two months approximately. Yates<sup>25</sup> considers the apical aperture size prior to initiation of treatment influences the apical closure. Ghose, Baghdady and Hikmat,<sup>26</sup> sad 78% of apical closure was obtained from five or six months after completing treatment sessions and two intracanal dressing with calcium hydroxide. Mackie, Bentley and Worthington<sup>27</sup> obtained a median time of 10.3 months, whereas Yates<sup>25</sup> nine months. According Shabahang et al<sup>28</sup> and White,<sup>29</sup> the apexification with calcium hydroxide has several disadvantages, including the variability of treatment time for the patient preservation (to meet the calls) and an increased risk

of fracture healing after tooth material by extended periods. Ding et al,<sup>30</sup> say the open apex can be “closed” by a calcified barrier, the apexification does not promote the further development of the tooth. The authors are not unanimous as to the time when a tooth with incomplete root formation to be treated with a slurry of calcium hydroxide or where the time interval in which the tooth should have changed the dressing. On average, the authors suggest the exchange of medication every thirty days to three months, during apexification it takes twelve to eighteen months, in the absence of infecção.<sup>2,25,31,32,33</sup> In view of this it is necessary to use substances which induce the formation of an apical barrier which prevents leakage of the filling material as well as its perfect accommodation, being the calcium hydroxide and mineral trioxide aggregate (MTA) substances of choice due to its biocompatibility, antibacterial properties and induce mineralization, which agrees with the Estrela.<sup>34</sup> Regarding the MTA, Ruiz et al<sup>35</sup> demonstrated that it is a biocompatible material with osteo-inductive capacity that promotes an appropriate marginal seal, preventing leakage, besides presenting antimicrobial effect. Demonstrated that in treatment of immature pulped teeth, the more favorable prognosis has been achieved with the procedure apexification with MTA, which showed greatest resistance to displacement in a thickness of 4mm compared to 1mm. According Dotto et al.<sup>36</sup>, MTA is used for making apical stop by the excellent results obtained in different studies as well as with the aim to reduce the number of sessions since it is unnecessary successive exchange material as occurs when employing calcium hydroxide, and also conclude that the apical closure in teeth with open apices and necrotic pulps can be obtained with sanitizing system canal obtained from the canal preparation and use of pastes containing calcium hydroxide for two months followed by placement of MTA for sealing and forming the apical barrier. But it is a global consensus that calcium hydroxide has shown satisfactory results regardless of the apexification whatever the technique used.<sup>16,37,38</sup> Recent studies<sup>30, 39,40</sup> report the effect of a revascularization procedure on teeth with necrosis and incomplete root formation and apical periodontitis by the use of poly-folder antibiotic or stimulation of blood clot, as a viable alternative for the treatment of teeth with incomplete rhizogenesis. These studies showed root development complete with a positive response to pulp testing. Another challenging situation for the clinician today is the decision between

evaluated key factors allowing the clinician to make decisions based on the best evidence and the best interests of the patient. Endodontic treatment is a viable way, practical and economical to preserve function in a wide range of cases and implants serve as a good alternative in selected indications in which the prognosis is poor. Hannahan and Eleazer<sup>42</sup> compared the success of implants and root canal treatment. One hundred and twenty-nine implants with median follow-up of 36 months showed a success rate of 98.4%. One hundred and forty three endodontically treated teeth were followed for an average of 22 months with a success rate of 99.3%. In this study, the success of the implant and endodontically treated teeth was essentially identical, but implants required more postoperative treatments to keep them. Root canal therapy is a highly predictable way to save the tooth, the implant natural. The excellence of endodontic treatment followed by immediate restoration of equal quality promises to give to patients service and function while maintaining aesthetic for years. The decision aimed at planning and endodontic treatment with high survival rate leads the clinician to consider additional factors including local and systemic conditions of the case, economic, desires and needs of the patient, aesthetics, potential adverse outcomes and ethical factors. Thus, endodontic treatment is always safe and feasible and based on the best interests of the patient and sensitive to the quality of life in long term<sup>43</sup>. Taking into consideration that the treatment of teeth with incomplete root formation in most affects individuals in bone development and that this treatment has achieved high success rates, it seems reasonable to suggest that endodontic treatment is the option to conduct the election and to achieve the ultimate goal which is the root development may be through of calcium hydroxide paste as intracanal dressing or, by revascularization.

## Conclusion

Endodontic treatment of teeth with incompletely formed apex are difficult to be performed. However, in our case we can conclude that the technique for apexification in teeth with incompletely formed apex and necrosis, using the calcium hydroxide paste as intracanal dressing is effective and the time required for the occurrence of the apical closure can occur between five months to one year and six months. And that the resorption can be stabilized when this technique of apexification was used. As the apexifica-

## References

1. Torneck CD. Effects and clinical significance of trauma to the developing permanent dentition. *Dent. clin. N. Amer.* 1982 July;26(30):481-554.
2. Andreasen JO. Traumatic injuries of the teeth. 3. ed. Copenhagen: Munksgaard;1984. 478p.
3. Heithersay GS. Calcium hydroxide in the treatment of pulpless teeth with associated pathology. *J Br End Soc.* 1975;8:74-93.
4. Estrela C, Sydney GB. EDTA effect at root dentin pH then exchange of calcium hydroxide paste. *Braz Endod J.* 1997;12-7.
5. Davidowicz H, Prokopowitsch I, Moura AAM, Santos M. Method of preparing intermouth as a means of preventing dental trauma. *Braz. dental J.* 1992;3(1):43-51.
6. Crona-Larsson G, Noren JG. Luxation injuries to permanent teeth. A retrospective study of etiological factors. *Endod. dent. Traumat.* 1989 Aug;5(4):176-91.
7. Estrela C, Estrela CRA, Barbin EL, Spano JCE, Marchesan MA, Pécora JD. Mechanism of action of sodium hypochlorite. *Braz. dent. J.* 2002;13(2): 113-7.
8. Abou-Rass M, Oglesby SW. The effects of temperature, concentration and type on the solvent ability of sodium hypochlorite. *J Endod.* 1981;7(8):376-7.
9. McComb D, Smith DC, Beagrie GS. The results of "in vivo" endodontic chemomechanical instrumentation. A scanning electron microscopy study. *J. Brit. endodont. Soc.* 1976 Jan;9(1):11-8.
10. Foster K, Kulild J, Weller N. Effect of smear layer removal on the diffusion of calcium hydroxide through radicular dentin. *J. Endodont.* 1993 Mar;19(3):136-40.
11. Holland R, Souza V, Tagliavini RL, Milanezi LA. Healing process of teeth with open apices. *Histological study. Bull Tokyo Dent Coll.* 1971;12(4):333-8.
12. Holland R, Souza V, Nery MJ, Mello W, Bernabé PFE, Otoboni Filho JA. Effect of the dressing in root canal treatment with calcium hydroxide. *Rev Fac Odontol. Araçatuba.* 1978;7(1):39-45.
13. Hulsman M. Dens invaginatus: a etiology, classification, prevalence, diagnosis, and treatment considerations. *Int. Endod. J. London.* 1997;30(2):79-90.
14. Holland R, Otoboni Filho JA, Souza V, Nery MJ, Bernabé PFE, Dezan JR E. Reparação dos tecidos periapicais com diferentes formulações de Ca(OH)<sub>2</sub>. *Estudo em cães. Rev Assoc Paul Cir Dent.* 1999;53:327-31.
15. Nedley MP, Powers GK. Intentional extraction and reimplantation of an immature invaginated central incisor. *ASDC J. Dent. Child.* Chicago; 1997 Nov./ Dec;64(6):417-20.
16. Felipe MCS, Felipe WT, Marques MM, Antoniazzi JH. The effect of renewal of calcium hydroxide paste on the apexification and periapical healing of teeth with incomplete root formation. *Int Endod J.* 2005;38(7):436-42.
17. O'Neil MJ (Ed.). *The Merck index: an encyclopedia of chemicals, drugs and biologicals.* 13. ed. New Jersey: Merck & Co., Inc.; 2001.
18. Lide DR (Edit.). *CRC handbook of chemistry and physics: a ready-reference book of chemical and a physical data.* 77. ed. London: CRC Press; 1996/1997.
19. Oltzky I. Antimicrobial properties of a propylene glycol based topical therapeutic
20. Thomas PA, Bath KS, Kotian KM. Antibacterial properties of dilute formocresol and eugenol and propylene glycol. *Oral Surg. St. Louis.* 1980 Feb;49(2):166-70.
21. Seidenfeld MA, Hanzlik PJ. The general properties, actions and toxicity of propylene glycol. *J Pharmacol. São Francisco,* 1932;44:109-21.
22. Cruz EV, et al. Penetration of propylene glycol into dentine. *Int Endod J. Oxford.* 2002 Apr;35(4):330-6.
23. Safavi K, Nakayama TA. Influence of mixing vehicle on dissociation of calcium hydroxide in solution. *J Endod. Baltimore.* 2000 Nov;26(11):649-51
24. Yates JA. Barrier formation time in non-vital teeth with open apices. *Int. Endodont. J.* 1988 Sept;21(5):313-9.
25. Ghose LJ, Baghdady YS, Hikmat YM. Apexification of immature apices of pulpless permanent anterior teeth with calcium hydroxide. *J Endod.* 1987;13:285-90.
26. Mackie IC, Bentley EM, Worthington HV. The closure of open apices in non-vital
27. Yates JA. Barrier formation time in non-vital teeth with open apices. *Int. Endodont. J.* 1988 Sept;21(5):313-9.
28. Shabahang S, Torabinejad M, Boyne PP, et al. A comparative study of root-end induction using osteogenic protein-1, calcium hydroxide, and mineral trioxide aggregate in dogs. *J Endod.* 1999;25:1-5.
29. White JD, Laceyfield WR, Chavers LS, et al. The effect of three commonly used endodontic materials on the strength and hardness of root dentin. *J Endod.* 2002;28:828-30.
30. Holland R, Souza V, Nery MJ, Mello W, Bernabé PFE. Root canal treatment with calcium hydroxide effect of an oily or a water soluble vehicle. *Rev. Odont. UNESP.* 1983;12(1/2):1-6.
31. Webber RT. Apexogenesis versus apexification. *Dent. clin. N. Amer.* 1984 Oct;28(4):669-97.
32. Leonardo MR, Silva LAB, Utrilla LS, Leonardo RT, Consolaro A. Effect of intracanal dressings on repair and apical bridging of teeth with incomplete root formation. *Endodont. dent. Traumat.* 1996 Feb;9(1):25-30.
33. Estrela C. *Ciência Endodôntica.* São Paulo: Artes Médicas; 2004.
34. Ruiz PA, et al. Agregado de trióxido mineral (MTA): uma nova perspectiva em endodontia. *Rev. Bras. Odontol.* 2003 jan./ fev;60(1):33-5.
35. Dotto SR, Travassos RMC, Santos R, Santos KSA, Melo WRA. Treatment endodontic in teeth permanent nonvital and incomplete root formation – case report. *Revista de Endodontia Pesquisa e Ensino OnLine.* 2006;3(2). [Acesso 22 set 2011]. Disponível em: [www.ufsm.br/endodontiaonline](http://www.ufsm.br/endodontiaonline).
36. Queiroz AM, Assed S, Leonardo MR. MTA and calcium hydroxide for pulpcapping. *J Appl Oral Sci.* 2005;13(2):126-30.
37. Pécora JD, Estrela C, Estrela CRA. A study of the time necessary for calcium hydroxide to eliminate microorganisms in infected canals. *J Appl Oral Sci.* 2003;11(2):133-7.
38. Torabinejad M, Turman M. Revitalization of Tooth with Necrotic Pulp and Open Apex by Using Platelet-rich Plasma: a Case Report. *JOE.* 2011;37(2):265-8.
39. Nosrat A, Seifi A, Asgary S. Regenerative Endodontic Treatment (Revascularization) for Necrotic Immature Permanent Molars: a Review and Report of Two Cases with a New Biomaterial. *JOE.* 2011;37(4):562-7.