

# Assessment of apical third morphology in root canals after biomechanical preparation: Alternate and continual rotations (Easy RaCe system)

Artur Fernandes de **PAIVA NETO**<sup>1</sup>

## ABSTRACT

**Objective:** This study aimed to analyze the presence of apical deviation according to the instrumentation technique and instruments used during mechanical preparation of root canals. **Methods:** It was carried out *in vitro* tests with the two types of preparation in root canals, in a total of 24 dental units divided into two groups according to the types of mechanical preparations made. **Conclusion:** At the end of the experiment it was observed that there was

no significative difference between the two types of instrumental techniques. This suggests a greater attention to the alternate preparation due to its low cost, being possible to include it in CEOs (specialized dental clinics) of Ministry of Health - Brazil.

**Keywords:** Dental Apex. Root Canal Preparation. Endodontics.

**How to cite this article:** Paiva Neto AF. Assessment of apical third morphology in root canals after biomechanical preparation: Alternate and continual rotations (Easy RaCe system). *Dental Press Endod.* 2012 July-Sept;2(3):54-60.

» The author reports no commercial, proprietary or financial interest in the products or companies described in this article.

Submitted: June 07, 2012 / Accepted: October 10, 2012.

Contact address: Artur Fernandes de Paiva Neto  
Av. Dois de Julho, 557 – Centro – Senhor do Bonfim/BA  
CEP: 48970-000 – E-mail: arturpaivaneto@hotmail.com

<sup>1</sup>Specialist in Endodontics, ABO.

## Introduction

Among the problems faced to achieve the prevention of dental units, there is the caries disease, which is the main pathological change responsible for the loss of dental units before the natural chronology.

Endodontics is the science and art involving etiology, prevention, diagnosis and treatment of pathological changes of the dental pulp and its impact on the periapical region and, therefore, in the body.<sup>11</sup>

To perform endodontic treatment, whatever is the nature, there are various techniques, medicines and tools to prepare and / or treat periapical pathophysiological changes.

The instrumentation or chemi-mechanical preparation is still for many the most important stage of endodontic treatment. For its special significance and relevance this step was chosen as the basis of this study, which focused on one of the major problems that happens during biomechanical preparation — the apical deviation — along with two forms of instrumentation and their respective instruments. Thus, it will be assessed more than one face of endodontic instrumentation. The study is based on analysis of the apical third morphology in root canals after biomechanical preparation performed with alternating or continual rotation, considering the instruments used. So, it will be highlighted the instrumentation technique and endodontic instrument that does not allow the occurrence of apical deviation after biomechanical preparation. This will be clarified by means of radiographic double exposure to presence or absence of apical deviation after alternated or continual rotating instrumentation.

## Development

According to classical literature, it is observed that the biomechanical preparation aims at emptying, sanitizing and expansion of root canals, in conical shape and continuously. This requires hand skills, patience, mastery of technique and anatomical knowledge, and respect for the principles present in the biological treatment process.

The final shape must be a replica of the original configuration of the root canal, in shape and conicity, but with larger diameter, allowing for proper cleaning and filling. The greatest difficulty in achieving these goals is related to the preparation of curved and / or atretic canals. These ideals can be achieved using both the

manual and automated preparation. However, we must remember that hand tools, in some cases, do not reach these goals, because they have physical limitations.

The most common change is the apical deviation by the action of endodontic instruments during biomechanical preparation of the apical third of root canals.

To decrease its occurrence, as well as other changes, other methods have been proposed and new instruments for root canal preparation, highlighting the instruments of nickel-titanium (NiTi or Nitinol) with composition of 55 to 60% of nickel and 40 to 45% titanium. The instruments are fabricated by machining from a conical metal rod of circular section.

These NiTi instruments have the following physical properties: They are anticorrosive, antimagnetic, have low elastic modulus, superelasticity and shape memory effect, which enables the NiTi alloy to return to its original shape after deformation. These qualities allow the instruments to monitor the anatomy of the channels more easily, preventing the apical displacement and maintaining its original form.

Some changes are observed when these systems are compared to conventional instruments, such as different conicity and modifications in radial surfaces, incidence angles of the cutting blade, helicoidal angles, tip morphology (penetration guide) and cross-section.

There is a range of options of NiTi systems for continual rotation and each manufacturer has its own characteristics with instruments. However, it is observed that such instruments do not follow the identification and / or setting of ISO / IDF. These instruments were designed to be activated and placed inside the root canal spinning clockwise at a constant speed. The preparation has the crown-apex sense, promoting the cleansing and modeling of channels simultaneously.

The use of rotatory instrumentation with NiTi instruments has been proposed in order to overcome bends and avoid possible distortions generated by the deficiency of conventional stainless steel instruments, trying to get an ideal preparation, without promoting changes in apical foramen, while minimizing the transporting material to periapex. Following the study line of the present work, some works which have studied the anatomical accidents can be observed. The work of Aguiar et al,<sup>7</sup> in 2006, can be cited, which had as its theme the radiographic assessment of apical deviation in canals instrumented with NiTi system. In this study it was observed

that after instrumentation, the images obtained by radiographic superimposition showed greater efficiency in the canals prepared with NiTi systems compared to conventional NiTi files. However, the differences were not statistically significant.

Pereira et al,<sup>6</sup> in 2007, compared qualitatively areas reached by instruments using stainless steel instruments and NiTi system. Thirty-two mesiovestibular roots of maxillary molars were used *in vitro*. After laboratory procedures, the moldings were examined and separated, as in the preparations of faces and thirds, based on the classification presented in similar jobs. According to the results, no significant differences were found between preparations with both techniques.

### Material and Methods

This study was based on the following methodology: An experimental study in laboratory type, with 24 human posterior teeth, with mesiovestibular canals on lower molars as experimental units.

The samples were provided by the Center for Dental Specialties (CEO) Senhor do Bonfim, in accordance with Federal Law 10.211.23, March 2001, the declaration of donations to ethical and legal research and Resolution 196/96 of the National Health Council upon the importance of the scientific work carried out in relation to oral health promotion. It was used in the research a sample of 24 molar teeth with curved roots, being randomly distributed 12 teeth in each experimental group: Group I and Group II. Each specimen had identification

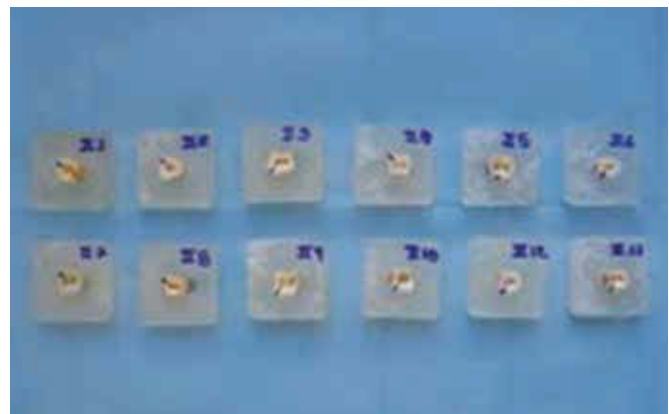

number (Fig. 1).

In order to obtain minimal interference from cervical third of the samples in instrumentation process or mechanical preparation, surgery was performed to access the units using a round burr (cutter) #2 and a Endo-type Z (Dentsply Maillefer®) to get a better view of the cutting line of the crowns on the cervical third. Following, it was carried the crown section of the 24 teeth, in the cervical third, near the cemento-enamel junction, with a carborundum disk.

In all units of the two groups was performed cervical preparation with Drill Gates I and II, and CP Drill (injec-ta). CP Drill drills were used in the following sequence: Red (D1 = 0.25 mm and 0.14 mm/mm conicity ) Blue (D1 = 0.30 and 0.18 mm/mm conicity) and Black (D1 = 0.40 and 0,22 mm/mm conicity).

In all samples, the working length was established by introducing, in each root, a file type Flexofile #10 or #08, until its tip appeared in foramen; then it was reduced about 1.5 mm, confirming the apical limit of work. It was considered the first instrument the one that would fit in the working length. According to the adjustment of the first instrument, the root apex was protected by utility wax light blue, preventing the obliteration of the apex by acrylic resin at the time of formation of the cubes for the experiment. Then we proceeded to identify the unit by its number.

This cubes were made from colorless acrylic resin, following the “cell” plastic mold having the same dimensions of the “cell” which would be attached to the



**Figure 1.** Samples properly divided into two groups at random: Observe the indication in mid-buccal root.

radiographic positioner in order to achieve a standardized radiograph.

The first radiograph was performed with a file that would fit to the channel in its working length. This first radiograph taken was performed for all units, regardless of group.

Keeping the radiographic standard, after preparation of the apical third with the last file, the second radiograph was made. For no movement of the film and change of radiograph position, and therefore some kind of alteration in the tooth positioning in the second radiograph, the film was kept in a radiographic positioner (Sydney ®) during endodontic treatment of the respective tooth – remembering that there were two radiographs taken on the same film, one with the first file (the one that fits) and one with the last file.

The alternate system is just a contra-angle presenting difference from the conventional contra angle, regarding the reduction in the frequency of rotation per minute, with a Push-Button head type for engagement of stainless-steel tools that can be connected to the electric motor or the micromotor of the dental equipo. In this study, the contra angle was connected to the equipo and worked by air pressure. When the handpiece was used coupled to equipo, working by air, there was no control of the speed, i.e. the r.p.m. - which is a disadvantage in the preparation of root canals, for not having greater control of the movement of the instruments. Thus, one should have greater sensitivity with regard to the preparation of the conduits, especially in atretic channels and with accentuated curvatures.

The handpiece used in this study was the NSK - Tep E16R, with degree of oscillation of 45 ° and a reduction of 16:1. The micromotor used is capable of 5,000 to 20,000 rpm. Thus, there was obtained, with the reduction 1.250 rpm. This reduction makes the instruments acquire a certain torque which facilitates instrumentation (Fig. 2). The channels of the units of Group I were prepared with Flexofile type files (Dentsply Maillefer ®), up to #30 taper from 0.2 mm / mm. In Group II, the instrumentation of the channels was performed using the RACE system FKG ® - Dentaire ® instrument until the #30 taper from 0.2 mm / mm. Thus a pattern was maintained for both groups.

To maintain the standard instrumentation in Group I, each set of files was used four times, and during the mechanical preparation, the patency of the foramen

maintained with file #10. In Group II, each set RaCe system was used five times, following the patency of the foramen, as Group I. Throughout the preparation, the channels were irrigated with sodium hypochlorite at a concentration of 2 to 2.5% (Q-good ®). At each change of instrument, the irrigation was performed with 20:5 Luer syringe, taking care to enter, without exerting any pressure, with the needle of .019 “type Capillary Tips (Ultradent) around 2mm beyond the channel inlet . Always followed with the recapitulation to remove debris from dentin, with a conicity lower tool between the exchange.

### Biomechanical preparation

» Group I: In this group were used files Flexofile type (Dentsply Maillefer ®), which are instruments made from a special stainless steel rod of triangular section and, after going through a process of twisting around its own axis, acquire a spiral shape. By owning the angle of the cutting blade at 45 ° or 60 ° acquire greater flexibility than the files type K. These instruments are identified by the symbol of a triangle on its handle. The instrumentation technique called sequential inversion was chosen in the use of stainless steel instruments (files type Flexofile). This technique was described by Souza,<sup>10</sup> in 2003.

The next step in the sequential inversion technique would be to use Batt bur #12. However, this study was chosen the CP Drill, following the sequence for use in accordance with the manufacturer.

With the completion of the preparation with CP Drill it was obtained the preparation of the cervical third of the root canal. Then, it was the preparation of the middle and apical third, the latter being the main focus of the study.

It is important to remember that the sequence of instruments should follow the instrumentation in crown-apex orientation until the instrument chosen as final, which was the file #30. To achieve the preparation of these two-thirds it was used the alternate system coupled to the micromotor dental unit. After instrumentation of root canals, went up to the second radiography, with the last instrument in working length - in this case, a file #30.

» Group II: To prepare this group were chosen instruments from FKG industry, RaCe™ system, also linked to the same handpiece of Group I, but with the head adaptation of NiTi instruments and continual rotation. RaCe

radiographs of the apical third morphology in root canals after biomechanical preparation: Alternate and continual rotation (Easy RaCe system)

instruments have a triangular section, alternate cutting blades and inactive tip. Its design has two functions: To eliminate the screw effect and locking. Five different pre-rotate and eleven RaCe instruments are available. However, in this study the following instruments were used for biomechanical preparation: PRE-RaCe: 40/10 and 35/08; Easy RaCe: 25/06; 25/04; 25/02 and 30/02. After biomechanical preparation with this system, it was placed a file type Flexofile #30 for the completion of the second radiography.

The samples were divided into two groups of 24 teeth each:

- Group I: Alternating technique – sequential inversion
- Group II: Continual technique – Easy RaCe® system.

To evaluate the presence of apical deviation, radiographs of Groups I and II were separately placed on the negatoscope and analyzed by two dentists, with the aid of magnifying loupe with 2X, recording on the form the presence or absence of apical deviation. Once completed, the forms were referred for evaluation and processing of results.

## Results

After assessment of the radiographs of the negatoscope and filling the sheet containing markings for the presence/absence of apical deviation in each unit, it can be observed the following:

» In Group I, from the 12 canals of instrumentation,

3 presented and 9 did not presented apical deviations (25% with apical deviation and 75% without deviation).

- » In Group II, none of the 12 instrumented canals suffered apical deviation (100% without apical deviation).
- » Deviations present in Group I were not severe, but were approximately of 0.5 mm between the first instrument (first radiograph) and the last instrument (last radiograph) (Figs. 3, 4, 5).

## Discussion and Conclusion

According to the results, we can conclude that the biomechanical preparation by the two techniques presented is of fundamental importance for the evolution of endodontic treatment.

Because of the study conducted in clinic/laboratory, there are some points to be considered:

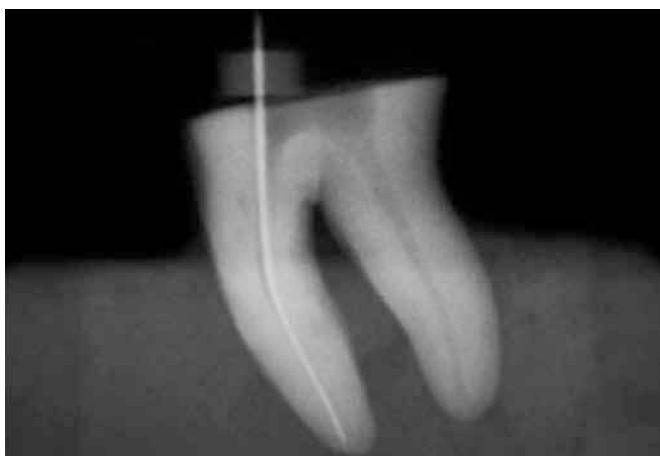- 1) The specimens did not present a single configuration, being the anatomy of the roots the main condition for the success of endodontic treatment.
- 2) The mechanical preparation was carried out without a fixed support, i.e. with the block supported on a bench and fixed only by the operator's hand. This interferes the surgery.
- 3) The study, being conducted *in vitro*, with the sectioned units and the previous preparation with Gates Glidden drills and CP Drill facilitated instrumentation up to file #30.



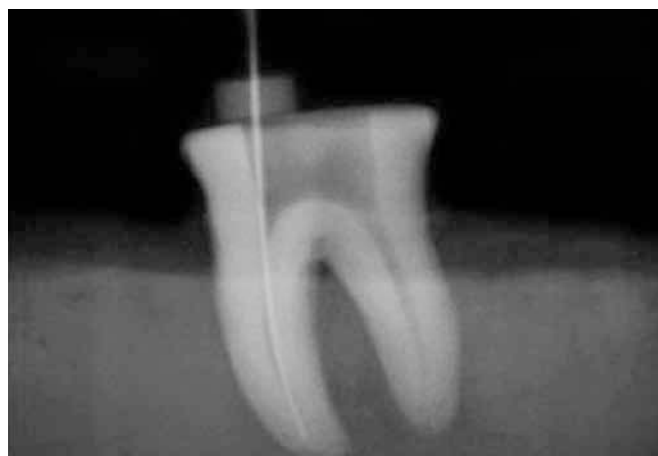
**Figure 2.** Handpiece Tep E10R 16:1 with head rotation alternating linked to conventional pneumatic micro-motor.



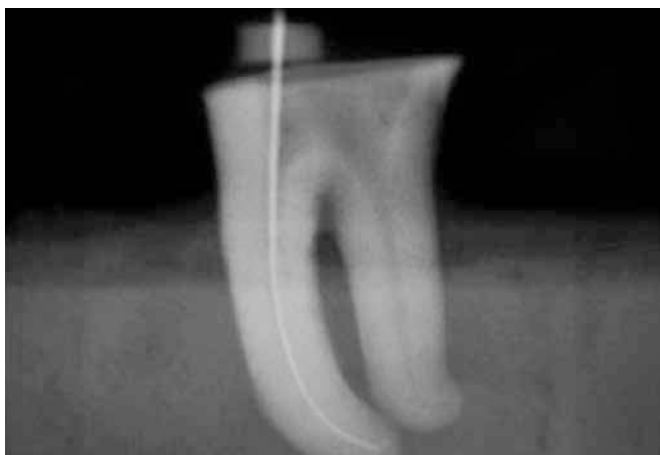
**Figure 3.** Handpiece Tep NSK E16R 16:1, with continual head rotation, linked to conventional pneumatic micro-motor.



**Figure 4.** Radiographic image analysis for Group I: Observe the preservation of the internal anatomy of the root canal.



**Figure 5.** Radiographic image analysis for Group I: Observe the preservation of transport, i.e., apical deviation.



**Figure 6.** Radiographic image analysis for Group II. Note the preservation of the internal morphology of the conduit, without the occurrence of apical deviation.

- 4) In Group I, the performance of instrumentation was with recapitulation in most cases. For a better preparation, it is suggested instrumentation with the aid of intermediate files, such as files Golden Medium (Dentsply Maillefer®). It is suggested to carry out a study analyzing instrumentation with and without these files mentioned.

The most important in choosing the equipment to perform the automated preparation - whether for continual or alternating movements - is the master of scientific and technical operative steps, a thorough knowledge of the instruments and the dynamics of its use. Over time, the clinician will realize that the equipment is “adapting” to their treatment philosophy, thus having total control over it. As reported in the presentation of this work, it is suggested the inclusion of alternating rotation systems in specialized dental clinics, the Ministry of Health, the public health system, once they are low cost, beyond all qualities reported during this study.

## References

1. Limongi O, Ramos IFA, Troian CH, Vanni JR, Albuquerque DS, Baratto Filho F. Análise in vitro do desvio apical, observado no sentido proximal, produzido por dois sistemas de rotação alternada: endogriper e M4. *JBE J Bras Endod.* 2004;5(16):67-72.
2. Spazzin VO, Spazzin AO, Cecchin D, Mesquita MF, Magro ML, Barbizan JVB. Efeitos do preparo cervical com brocas Gates-Glidden e LA Axxess no desvio apical após preparo biomecânico de canais radiculares. *Rev Fac Odont.* 2008;13(1):39-42.
3. Alves DF, Salgado AAM. Avaliação da ocorrência de desvio apical após o preparo biomecânico, utilizando limas flexo-R e o sistema quantec serie 2000. *J Bras Endo/Perio.* 2000;1(3):41-4.
4. Aguiar CM, Câmara AC. Avaliação das alterações morfológicas do terço apical em canais instrumentados com Pro Taper Manual, Pro Taper e RaCe. *Odontol Clin Cient.* 2006;5(3):211-5.
5. Pesce HF, Carrascosa A, Medeiros JMF, Pabla F. Análise morfológica da região apical de canais radiculares curvos após o preparo químico-mecânico em função do tipo e número do último instrumento. *Odontologia USF.* 1992;10(1-2):79-84.
6. Pereira KFS, Yoshinari GH, Insaurralde AF, Silva PGS, Biffi JCG. Análise qualitativa pós instrumentação utilizando instrumentos manuais de aço inoxidável e rotatórios de níquel-titânio. *Pesq Bras Odontopediatria Clin Integr.* 2007;7(3):247-52.
7. Aguiar CM, Câmara AC, Moraes AC. Avaliação radiográfica do desvio apical em canais instrumentados com o Sistema Pro-Taper. *Rev Assoc Paul Cir Dent.* 2006;60(1):67-71.
8. Mamede Neto I, Rangel AL, Estrela C. Influência de instrumentos de níquel-titânio na qualidade tridimensional da modelagem radicular em molares superiores e inferiores. *Rev Odont Brasil Central.* 2006;15(39):62-72.
9. Carvalho MGP, Pagliarin CL, Corrêa CM Santos AI, Coutinho FS, Borges RM. Preparo químico mecânico dos condutos radiculares: análise comparativa da formação do desvio apical "zip" em canais curvos produzido "in vitro" por técnicas de instrumentação. *Saúde.* 2004;30(1-2):21-32.
10. Souza RA. *Endodontia clínica.* São Paulo: Ed. Santos; 2003.
11. Leonardo MR. *Endodontia: tratamento de canais radiculares. Princípios técnicos e biológicos.* São Paulo: Artes Médicas; 2005.
12. Estrela C. *Ciência endodôntica.* São Paulo: Artes Médicas; 2004.