

In vitro evaluation of two techniques to determine working length with an electronic apex locator

Etevaldo Matos **MAIA FILHO**¹

Cláudia de Castro **RIZZI**²

Erick Miranda **SOUZA**³

Kléber Cortês **BONIFÁCIO**³

Maués Teles de **ARAÚJO JÚNIOR**⁵

ABSTRACT

Objective: To verify *in vitro* whether an electronic apical location using a non-foramen by-pass technique influences the accuracy of the procedure. **Methods:** Fifteen incisors and canines human teeth with complete apical formation were used. Teeth were fixed to a resin-based model and embeded into alginate to serve as a conduction medium for the eletronical readings. Using a K-flexo-file #20 coupled to the apical locator device (Root ZX II, J Morita, Kyoto, Japan), root canals were electronically measured at two different time-points. Firstly, it has been registered before passing through the apical foramen (alternative technique) and, thereafter with the file bypassing the apical foramen (recomended technique). On both techniques the readings were performed whenever the

display was stabilized at level 0.5. After each electronic determination, the tooth was radiographed with the file in position. To measure the agreement between the two techniques, the interclass correlation statistical procedure was used. **Results:** The difference between the two techniques at the radiographic evaluation was 0.118 mm (\pm 0.170) and for the electronic reading 0.086 mm (\pm 0.398). The two techniques were significantly correlated both for the electronic reading and for the radiographic evaluation (ICC = 0.98; $p < 0.001$, ICC = 0.97; $p < 0.001$, respectively). **Conclusion:** The alternative technique for electronic apical location, without passing the foramen, has shown similar accuracy as the standard technique, sugested by the manufacturer.

Keywords: Endodontics. Tooth Apex. Odontometry.

How to cite this article: Maia Filho EM, Rizzi CC, Souza EM, Bonifácio KC, Araújo Júnior MT. *In vitro* evaluation of two techniques to determine working length with an electronic apex locator. Dental Press Endod. 2012 July-Sept;2(3):27-31.

» The authors report no commercial, proprietary or financial interest in the products or companies described in this article.

¹PhD in Endodontics, UNESP-Araraquara. Professor of Endodontics, UNICEUMA.

²PhD student in Pediatric Dentistry, FORP-USP. Professor of Endodontics, UNICEUMA.

³PhD student in Pediatric Dentistry, FORP-USP.

⁴Graduated in Dentistry, UNICEUMA.

Submitted: August 19, 2012. / Accepted: August 23, 2012.

Contact address: Etevaldo Matos Maia Filho
Rua Duque Bacelar, 11 – Altos do Calhau – São Luiz/MA
CEP: 65.071-785 – E-mail: rizzimaia@yahoo.com.br

Introduction

Odontometry is an indispensable step in endodontic therapy, in which the objective is to determine with the greatest possible accuracy, the working length (WL). However, the ideal WL for treatment of root canals has always been a much discussed and controversial topic. Sjogren et al¹ in an epidemiological study found that when the apical limit of obturation was at 2 mm from the radiographic apex, endodontic treatment had a better prognosis. These results were best explained by Ricucci and Langeland,² which in a histological study found the best repair conditions when the instrumentation and obturation remained near the apical constriction, and when there was cement or gutta percha extrusion a severe inflammation was evidenced. Thus, the instrumentation and obturation must remain, preferably, in the narrower part of the root canal, i.e., the apical constriction, for the preparation in this point provides a smaller diameter wound, providing better conditions for repair.²

The most popular method for establishing the working length is the radiographic method, which is based on the premise that the apical constriction is located between 0.5 and 1 mm from the radiographic apex.^{3,4} However, this radiographic estimate can lead to over- or under-instrumentation/obturation. Moreover, the determination by radiographic means has several limitations such as distortion, shortening and lengthening of the image, interpretation variability, besides representing an image in three dimensional structures in two dimensions.

Currently, the odontometry method considered more accurate is the electronic one, using electronic apex locators (EAL).⁵ The desire to establish the limit of electronic instrumentation is quite old. Suzuki⁶ proved that the electrical resistance between an instrument inside the canal and an electrode present in the oral mucosa showed consistent values. Sunada⁷ considering this information made a clinical application, developing a device that indicated constant electrical resistance when the tip of an instrument inserted into the root canal reached the periodontal membrane, through the apical foramen. Later, Ushiyama et al⁸ reported that the lowest intensity of the electrical impedance was obtained when the electrode reached the apical constriction, changing the foramen location concept (location of periodontal membrane) from

biological to physical, ie, in dependence of determining the apical constriction.

In recent years, the EALs have become popular, however, according to the manufacturers, in order to ensure that the narrowest point in the root canal detected by the locator is in fact the apical constriction, it is necessary to surpass the apical foramen and regress the instrument to the point of constriction. However, this standard method recommended by the manufacturer can possibly cause injuries to the apical tissues, in cases of teeth with vital pulp, and in cases with necrotic pulp result in extrusion of necrotic material. Thus, from a biological standpoint, during the electronic measurement of the WL, ideally, the instrument should not exceed the apical foramen, reaching the periapical tissues. However, the use of this alternative approach without passing through the apical foramen may result in lower accuracy or inaccuracy in apical location. Still, this hypothesis has not been tested yet.

Thus, this *in vitro* study was designed with the objective of determining whether the technique of electron odontometry not exceeding the apical foramen influences the accuracy of the measurement. The null hypothesis tested is that the measurements obtained with the alternative technique does not correlate with the standard technique.

Materials and methods

Selection and preparation of samples

This study was approved by the Research Ethics Committee of the University CEUMA (protocol number 00519/11). Fifteen human extracted teeth, upper and lower, single rooted (incisors, canines, and premolars) and with completely formed apices were selected. The teeth were stored in sodium hypochlorite 2.5% for six hours and then stored in sterile saline solution. The crowns of the teeth were horizontally sectioned at the cemento-enamel junction in order to simplify the access to the root canal and get an occlusal reference point reliable and stable. Gates-Glidden drills 4 and 3 were used to expand the coronary third. The canals were irrigated with saline solution and patency was assessed with the aid of a file #10 (Flexofile).

The teeth were fixed in a resin model and soaked up to 2 mm below the cemento-enamel junction in alginate molding (Jeltrate II, Dentsply, Petrópolis Brazil)⁹ which was used as a conducting medium for electronic

apical locations. The alginate was prepared according to the recommendations of the manufacturer. A steel wire, 0.5 mm thickness, was set in the resin model to serve as a dimensional reference for the measurements performed on radiographs.

Electronic and Radiographic Odontometry

For electronic measuring the root canals were put in a sodium hypochlorite 1% solution and labial connector of the appliance remained immersed in wet alginate. A Flexofile #20 was attached to the connector on the device Root ZX II (J Morita, Kyoto, Japan).

The root canal of each tooth was measured by two techniques which presuppose or not the file passing by the apical foramen to perform the measurements. In the first measurement, named alternative technique, the file was gently introduced into the root canal watching on the device display the progress that occurred until the value 0.5 remained stable. At this time, the course of silicone was adjusted in the reference and a radiographic technique of parallelism was performed using a digital X-ray sensor (Schick Technologies, Inc., Long Island City, NY) and X-ray Seletronic model (Dabi Atlante, Ind. Dental Medicine, Ribeirão Preto) set to 70kV and 8 mA. After radiography, the file was removed from the root canal and the distance from the tip of the instrument until the cursor was recorded using an electronic caliper with zoom at 0.01mm (Mitutoyo Digimatic).

In the second measurement, performed by the standard technique recommended by the manufacturer, the file was again gently inserted into the root canal until the buzzer emitting a continuous beep and the word "APEX" flashed on the LCD screen of the device. Then the file was retracted to the position indicated on the display stabilized at 0.5. The cursor was again adjusted and another radiograph was performed under the same conditions of the first. The file was removed from the root canal and the distance from the tip of the cursor to the file was recorded with a digital caliper.

All measurements were performed at an interval of 1 hour, remaining the alginate sufficiently wet during this time. Measurements were performed after the canals were irrigated with 2 mL of sodium hypochlorite (Biodynamics, São Paulo, Brazil). A single experienced operator in the use of electronic apex locator conducted electronic and radiographic measurements.

Radiographic images reading, data tabulation and statistical analysis

Radiographs obtained after each electronic measurement technique were analyzed by an independent evaluator, with the aid of the computer program Image J (National Institute of Health, USA). The distances were measured between the tip of the instrument and the radiographic apex taking as dimensional reference the 0.5 mm steel wire image incorporated in the resin model and visible on radiographs.

The results (in mm) obtained were tabulated for both methods, radiographic and electronic. The intraclass correlation coefficient (ICC) was used to measure the degree of agreement between the two techniques (standard and alternative) for each of the methods (electronic and radiographic).

In all tests the significance level was 0.05 and the statistical program used was SPSS version 17.00 (SPSS Inc. Chicago, IL, USA).

Results

The data obtained in electronic and radiographic measurements for standard and alternative techniques are shown in Table 1.

The result of the intraclass correlation to the measurements obtained in electronic measurement was highly significant (ICC = 0.97, $p < 0.001$), indicating high concordance between the two techniques.

For the radiographic method, the intraclass correlation was also significant (ICC = 0.98, $p < 0.001$), indicating a good agreement between the two radiographic techniques observed.

Table 1. Mean and standard deviation of measurements by standard and alternative techniques of WL and the difference [modulus] between techniques in each method assessed.

Electronic Measurement (mm)			Radiographic Measurement (mm)		
Standard	Alternative	Difference Standard / Alternative	Standard	Alternative	Difference Standard / Alternative
14,328 ± 1,582	14,414 ± 1,540	0,086 ± 0,398	0,604 ± 0,471	0,722 ± 0,531	0,118 ± 0,170

Discussion

To establish WL using the EALs it is recommended to use the apical indentation technique, which consists in the introduction of the file to the foramen (where the locators indicates 0.0 or APEX) and shortly after is carried the retreat to the electronic location of the apical constriction. With this method it is possible to identify the first constriction in the crown-apex direction. However, such a procedure, specially in teeth with pulp necrosis may eventually force the extrusion of necrotic material to the periapical region with the possibility of originating a bacteremia as shown by Debelian et al.¹⁰ In this study it was tested the hypothesis of no difference between this standard technique and an alternative one in which the reading is performed when the AL indicates the point of apical constriction, crown-apex direction, without the need to go through the apical foramen.

The results observed with the alternative technique significantly correlated with the data from the standard technique, indicating that not going through the apical foramen did not alter the apical electronic localization accuracy of the device used (Fig 1). This correlation between the two techniques was also confirmed in radiographic evaluation (Fig 2). Thus, the null hypothesis suggested in this work was rejected.

The Root ZX device uses the “ratio method” to locate the apical constriction⁵ measuring impedance using two frequencies simultaneously. This device has

demonstrated, in *in vivo* and *in vitro* studies, when used according to the manufacturer’s recommendations and with apical transposition, an accuracy ranging from 85% to 97.37%.¹¹⁻¹⁴ In the present study, the alternative technique was used before the standard technique, once it was aimed in the alternative technique to determine the first apical constriction without any prior foramen transposition. It is also known that the pre-expansion of root canals increases the accuracy of the apical location with the Root ZX,^{15,16} and therefore Gates Glidden drills were used in the cervical preparation of root canals.

Tinaz et al¹⁷ and Meares and Steiman¹⁸ showed that different concentrations of sodium hypochlorite solution did not influence the reading of EALs. Due to hypochlorite being used as irrigant in clinical situations, it was used hypochlorite 1% during the reading of WL in this study.

In vitro studies of EAL should use material allowing the simulation of the periodontal ligament and it must conduct electricity. The most commonly used materials for this purpose are agar,¹⁹ gelatine,²⁰ saline solution¹⁸ and alginate,²¹ however, a study conducted by Baldi et al⁹ showed that the alginate was the way providing more consistent results with the real working length, and for this reason it has been used as a means of electrical conduction in this research. During this study, measures and radiographs were performed only when the display of the device indicated, without any

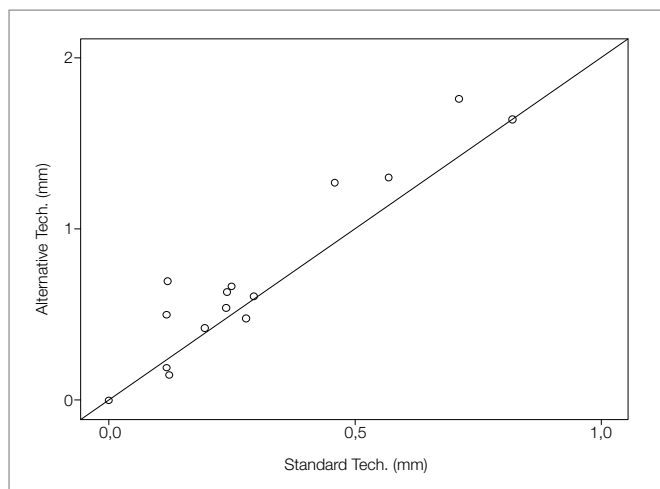


Figure 1. Correlation between the measurements obtained by the standard technique and alternative one, evaluated by radiographic method (ICC = 0,97, IC95% = 0,912-0,990, $p < 0,001$).

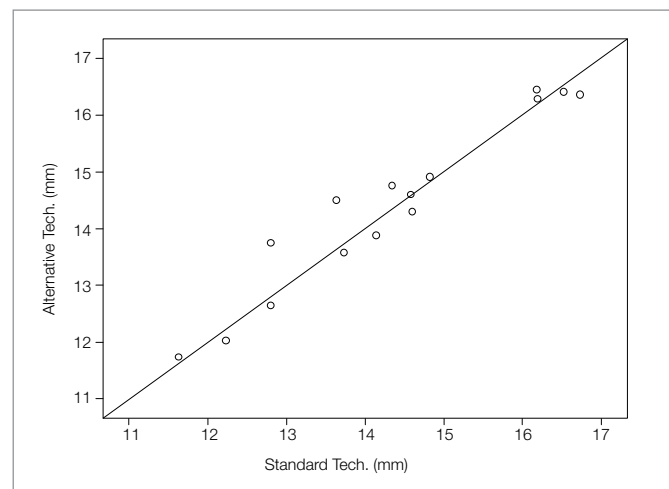


Figure 2. Correlation between the measurements obtained by the standard technique and alternative one, evaluated by clinical method (ICC = 0,983, IC 95% = 0,951-0,994, $p < 0,001$).

oscillation, the position 0.5. According to the manufacturer, this data indicates that the file tip is positioned exactly at the apical constriction or very close to it.

Considering that the objective of the study was to determine the accuracy of the alternative method of locating the apical constriction with and without apical transposition, the 0.5 indicator was used as reference in this study. This data was also used in other studies.^{22,23}

The result of this *in vitro* study suggests that the AL technique using alternative method as described in this study have accuracy similar to the technique

recommended by the manufacturer. However, there it is necessary further studies using other EALs and other dental groups to prove that this principle applies regardless of these other variables, as well as *in vivo* trials to determine the same pattern observed in this *in vitro* study.

Conclusion

The alternative technique without exceeding the apical foramen showed similar accuracy to the standard technique with foramen transposition, both in radiographic and electronically measurements obtained.

References

1. Sjogren U, Hagglund B, Sundqvist G, Wing K. Factors affecting the long-term results of endodontic treatment. *J Endod.* 1990;16(10):498-504.
2. Ricucci D, Langeland K. Apical limit of root canal instrumentation and obturation, part 2. A histological study. *Int Endod J.* 1998;31:394-409.
3. Katz A, Mass E, Kaufman AY. Electronic apex locator: a useful tool for root canal treatment in the primary dentition. *ASDC J Dent Child.* 1996;63(6):414-7.
4. Morfis A, Sylaras SN, Georgopoulou M, Kernani M, Proutzos F. Study of the apices of human permanent teeth with the use of a scanning electron microscope. *Oral Surg Oral Med Oral Pathol.* 1994;77(2):172-6.
5. Nekoofar MH, Ghandi MM, Hayes SJ, Dummer PM. The fundamental operating principles of electronic root canal length measurement devices. *Int Endod J.* 2006;39(8):595-609.
6. Suzuki K. Experimental study on ionphoresis. *J Jap Stomatol.* 1942;16:411-29.
7. Sunada I. New method for measuring the length of the root canal. *J Dent Res.* 1962;41(1):375-87.
8. Ushiyama J, Nakamura M, Nakamura Y. A clinical evaluation of the voltage gradient method of measuring the root canal length. *J Endod.* 1988;14:283-7.
9. Baldi JV, Victorino FR, Bernardes RA, Moraes IG, Bramante CM, Garcia RB, et al. Influence of embedding media on the assessment of electronic apex locators. *J Endod.* 2007;33(4):476-9.
10. Debelian GJ, Olsen I, Tronstad L. Bacteremia in conjunction with endodontic therapy. *Endod Dent Traumatol.* 1995;11(3):142-9.
11. Goldberg F, Marroquin BB, Frajlich S, Dreyer C. In vitro evaluation of the ability of three apex locators to determine the working length during retreatment. *J Endod.* 2005;31(9):676-8.
12. Lucena-Martin C, Robles-Gijon V, Ferrer-Luque CM, Mondelo JM. In vitro evaluation of the accuracy of three electronic apex locators. *J Endod.* 2004;30(4):231-3.
13. Plotino G, Grande NM, Brigante L, Lesti B, Somma F. Ex vivo accuracy of three electronic apex locators: Root ZX, Elements Diagnostic Unit and Apex Locator and ProPex. *Int Endod J.* 2006;39(5):408-14.
14. Vieyra JP, Acosta J. Comparison of working length determination with radiographs and four electronic apex locators. *Int Endod J.* 2011;44:510-8.
15. Ibarrola JL, Chapman BL, Howard JH, Knowles KI, Ludlow MO. Effect of preflaring on Root ZX apex locators. *J Endod.* 1999;25:625-6.
16. Camargo EJ, Zapata RO, Medeiros PL, Bramante CM, Bernardini N, Garcia RB, et al. Influence of preflaring on the accuracy of length determination with four electronic apex locators. *J Endod.* 2009;35(9):1300-2.
17. Tinaz AC, Sevimli LS, Gorgul G, Turkoz EG. The effects of sodium hypochlorite concentrations on the accuracy of an apex locating device. *J Endod.* 2002;28(3):160-2.
18. Meares WA, Steiman HR. The influence of sodium hypochlorite irrigation on the accuracy of the Root ZX electronic apex locator. *J Endod.* 2002;28(8):595-8.
19. Fouad AF, Krell KV. An in vitro comparison of five root canal length measuring instruments. *J Endod.* 1989;15(12):573-7.
20. Czerw RJ, Fulkerson MS, Donnelly JC. An in vitro test of a simplified model to demonstrate the operation of electronic root canal measuring devices. *J Endod.* 1994;20(12):605-6.
21. Nguyen HQ, Kaufman AY, Komorowski RC, Friedman S. Electronic length measurement using small and large files in enlarged canals. *Int Endod J.* 1996;29(6):359-64.
22. Tinaz AC, Maden M, Aydin C, Turkoz E. The accuracy of three different electronic root canal measuring devices: an in vitro evaluation. *J Oral Sci.* 2002;44(2):91-5.
23. Welk AR, Baumgartner JC, Marshall JG. An in vivo comparison of two frequency-based electronic apex locators. *J Endod.* 2003;29(8):497-500.