

# Clinical and imaginologic diagnosis of occlusal trauma

Alberto **CONSOLARO**<sup>1</sup>

## ABSTRACT

A more refined diagnosis tends to be based on subtle signs and symptoms, requiring the specialist to be extremely judicious and knowledgeable. Occlusal trauma should be included in the differential diagnosis of apical periodontitis and dental trauma. Ideally, when a tooth presents with pulp necrosis and signs of occlusal trauma, one should conduct the interview and diagnostic tests in search of a superimposed dental trauma, even in posterior teeth. No scientific rationale is strong enough as to allow one to state that occlusal interference or occlusal overloads produce a necrotic pulp. Interferences and occlusal overloads take months or even years to induce the

classic signs and symptoms of occlusal trauma as a clinical entity. It is still common to compare the effects of occlusal trauma to those resulting from orthodontic movement and dental injuries. The mechanisms underlying tissue changes induced by occlusal trauma are in no way comparable to those induced by orthodontic movement or dental trauma. In these three events the primary cause is of a physical nature, but the forces applied to dental tissues exhibit completely different characteristics of intensity, duration, direction, distribution, frequency and form of uptake by periodontal tissues.

**Keywords:** Occlusal trauma. Occlusion. Gingival recession. Dental trauma. Abfraction.

<sup>1</sup> Full Professor, School of Dentistry, Bauru, São Paulo State; Full Professor, Graduate School of Dentistry, Ribeirão Preto - University of São Paulo.

**How to cite this article:** Consolaro A. Clinical and imaginologic diagnosis of occlusal trauma. Dental Press Endod. 2012 July-Sept;2(3):10-20.

» The authors report no commercial, proprietary or financial interest in the products or companies described in this article.

The clinical condition that characterizes occlusal trauma and the variables of these clinical and imaging characteristics are greatly undervalued in undergraduate and specialist training programs. Consequently, an accurate diagnosis and its clinical implications end up being ignored in the planning and follow-up of some clinical cases.

Many experts, however, believe that the causes and potential developments of occlusal trauma resemble dental trauma and orthodontic movement, although these are completely distinct conditions. The injuries induced in the tissues by these three situations are considerably diverse.<sup>1</sup>

Orthodontic movement cannot be likened to occlusal trauma.<sup>1</sup> The cellular and tissue changes promoted by occlusal trauma in periodontal tissues are completely different from those induced by orthodontic movement.

In dental trauma, forces are abrupt, intense and short-lived. Damage comprises breakage of periodontal components, with the teeth touching or driving their roots through the alveolar bone structures, causing bleeding and necrosis in support tissues.

The only feature shared by these three conditions – occlusal trauma, orthodontic movement and dental trauma - is the physical nature of their causes translated into forces, but these forces exhibit unique characteristics to such an extent that comparisons between the injuries induced in the tissues are not possible.

The authors sought to publish a series of articles on occlusal trauma in journals geared to the various clinical specialties with a view to contribute to the clarification and understanding - in an applied and specific fashion - of the clinical and imaging signs of occlusal trauma in each area. Given the same topics, many parts of the content, text and figures of these articles inevitably recur.<sup>4,5,6</sup>

### **Occlusal trauma as a clinical condition or clinical entity**

The condition, or clinical entity known as occlusal trauma is synonymous with occlusion trauma, traumatic occlusion, traumatogenic occlusion, periodontal traumatism, occlusal overload, among others.

The name of a given clinical condition seeks to identify the type of injury or set of changes induced in the affected tissues. Terminological precision and standardization facilitate a more comprehensive

search for information in databases as well as communication between scholars and researchers.

The term injury means any structural change, irrespective of its nature, which can be transient or permanent. Injuries induced in periodontal tissue, which characterize the clinical condition called occlusal trauma, may be caused by traumatic occlusion or overload of occlusal forces in single or multiple teeth simultaneously, depending on the clinical situation.

The induced injury known as occlusal trauma was classically defined:

- 1) By Stillman,<sup>10</sup> in 1917, as resulting from a situation in which the act of occluding the jaws damages the supporting tissues of teeth.<sup>11,12</sup>
- 2) In 1978, the World Health Organization (WHO) described it as periodontium damage induced by pressure on the teeth produced directly or indirectly by antagonist teeth.<sup>11,12</sup>
- 3) The American Association of Periodontology defines it as an injury in the dental support apparatus, resulting from excessive occlusal force.<sup>8,9</sup>

The three definitions of occlusal trauma given above share the concept that damage is necessarily produced by overload induced by the teeth in occlusion and by antagonist teeth.

Occlusal trauma in one or more teeth may be associated with parafunctional responses such as clenching and bruxism. The causes of occlusal trauma in orthodontic practice may be related to premature contacts arising from the position of teeth, inappropriate occlusal morphology between antagonist teeth, overload on lateral incisors when these teeth are laterally involved in canine guidances, and postoperative periods following orthognathic surgeries.

One should not mistake an occlusal interference, such as premature contact, for occlusal trauma. Occlusal trauma is a clinical entity or a specific condition. Occlusal interference may prove to be the cause, but the term occlusal trauma should be used to identify the clinical entity along with its clinical signs and symptoms. An occlusion may be traumatic, and yet not lead to the injury or disease called occlusal trauma.

### **Occlusal trauma should not be likened to the effects of orthodontic movement**

Human teeth are capable of enduring heavy occlusal loads that produce intrusive movements in the alveoli,

mainly during mastication. Injuries to this apparatus are caused by very strong, persistent, or repetitive forces. Even in this situation, the periodontal ligament — with an average thickness of 0.25 mm, or 250  $\mu\text{m}$  - will not allow the teeth to touch the apical alveolar cortical surface. This underscores a structural organization that comprises a perfect physiological apparatus, which enables the insertion of the tooth in the socket.

The periodontal ligament is a delicate membrane overlying the root surface and connecting the latter to the alveolar bone. Fifty percent of its structure is composed of vessels (Fig 1). It is efficient for intrusive forces, but not for lateral forces, so that when one intends to move teeth orthodontically,<sup>1</sup> forces are often lighter, with inclination or bodily movements, and such forces are by far lighter than in occlusal trauma. These forces are delivered slowly and eventually dissipate.

After each period of appliance activation, the periodontal tissues return to normal, allowing new forces to be applied with the same characteristics: Light and in one single moment, while forces dissipate.<sup>1</sup> This differs in almost everything if one tries to compare the effects of orthodontic movement to occlusal trauma, especially in regard to induced cellular and tissue reactions and their consequences.

One of the major objectives of clinical orthodontic practice is to correct occlusion disorders, especially those involved in the relationships between the jaws and dental arches. Professional orthodontic training, however, is usually not thorough enough or suitable for detecting more subtle occlusal interferences. In Brazilian Dentistry, within the scope of clinical specialties, there are professionals who specialize in the examination, diagnosis and correction of occlusion and temporomandibular disorders.

Orthodontic movement induces some occlusal interference, but these are temporary and generally do not last long enough to injure the periodontal support structures significantly. The changes inherent in occlusal trauma require prolonged action by the damaging forces, affecting one and the same site.

At the end of orthodontic treatment, it is not a widespread conduct to perform a thorough occlusal analysis on discharging the patient, thereby allowing a natural “accommodation” to settle over the subsequent months.<sup>3</sup> However, in many cases the patient complains and exhibits changes that are typical of occlusal trauma in specific teeth.

## **Occlusal trauma and orthodontic movement do not induce pulp necrosis: But dental trauma does!**

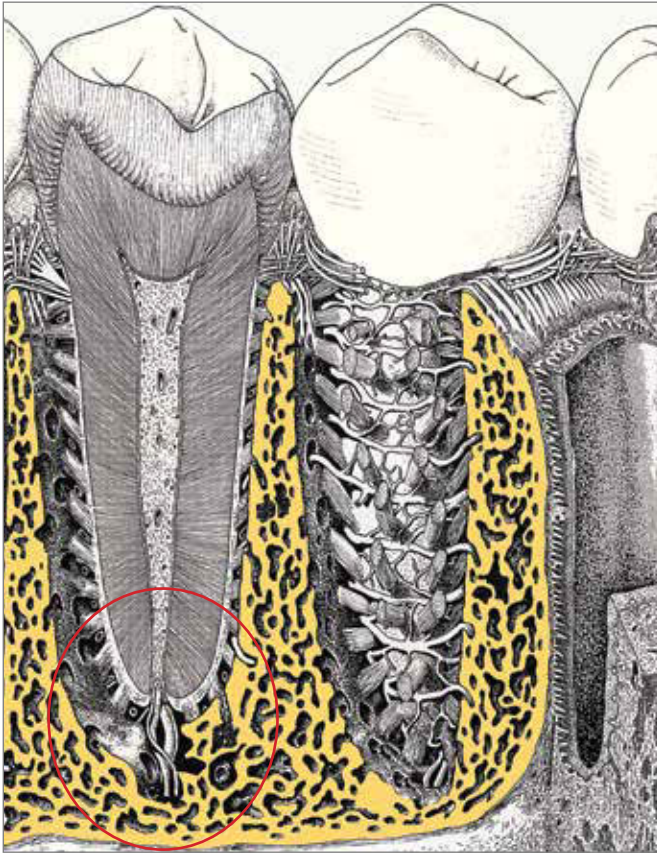
Occlusal trauma promotes cellular and tissue changes which are totally distinct from phenomena induced by orthodontic movement.<sup>1</sup> Occlusal trauma is characterized by repeated, intense forces, whereas orthodontic forces are much lighter and although applied in one go, are delivered slowly and progressively: Within 3 to 6 days these forces dissipate gradually, fading completely within 7 to 10 days in humans.<sup>1</sup> In both cases the vascular bundle does not undergo breakage or partial injury. Despite the periodontal ligament's average thickness of 0.25 mm or 250  $\mu\text{m}$ , its organization and function do not allow the teeth to touch the apical alveolar cortical surface during heavy chewing, which could damage the vascular bundle at the entrance of the apical foramen (Fig 1).

Abrupt, intense and short-lived forces typical of dental trauma can cause breakage of periodontal components as the teeth touch or drive their roots through the alveolar bone structures, resulting in bleeding and necrosis in the supporting tissues. Sudden displacement by strong, transient forces disrupts the vascular bundle at the entrance of the root canal at the level of the apical foramen. Dental trauma by concussion often occurs without the patient exhibiting clinical signs of discomfort or pain syndrome.

In orthodontic movement forces are much lighter than in dental trauma, as they are applied slowly until dissipation and, despite the fact that the orthodontic appliance is activated periodically in one go. These characteristics of forces delivered in orthodontic treatment have justified the results of many studies about the absence of significant changes in the dental pulp.

There is absolutely no rationale to substantiate claims that orthodontic movement induces pulp necrosis. Moreover, the greater the forces delivered orthodontically, the less effectively these forces are likely to induce tooth displacement, and therefore, the less likely they are to cause pulp necrosis. Similarly, there is no rationale to explain pulp necrosis induced by occlusal trauma. When such suspicious cases are identified, it would be more advisable to blame dental trauma.

In occlusal trauma, forces are repetitive and intense, but nothing comparable to that of dental trauma, where forces occur in one go, suddenly and intensely.



**Figure 1.** Two and three dimensional aspects of the periodontal ligament and other structures. Note the shape and extreme organization in the distribution of collagen fibrous bundles that prevent, even under overload conditions, the apex from touching the bottom of the socket (modified, from Krstic, RV, 1991).

Occlusal forces, even in overload, cannot put the tooth apex in contact with the bottom of alveolar bone and crush, or otherwise damage the vascular bundle. The human periodontal ligament was designed to absorb and dissipate the intrusive forces that predominate in chewing and swallowing movements.

### Occlusal trauma in mineralized structures and abfraction

In areas of occlusal interference, occlusal trauma determines the presence of wear facets produced by friction.<sup>8,9</sup> At the same time, excessive pressure or eccentric forces produce three-dimensional deformations in the mineralized tooth structure. These deformations are called temporary and repetitive deflections.

Deflection is the act or effect of deflecting, a verb that indicates a movement that deviates from a given

line in order to follow another direction — this line can be referred to as the long axis of the tooth. A deflection on the tooth, when deviating from the long axis, can create traction on one side and compression of mineralized structures on the other side.

Cementum and dentin are deformable, but enamel is not. Dentine is comprised on average of 60% inorganic component, and 40% organic component, predominantly proteins and water. On the other hand, 50% of the cementum structure consists of organic matter, and 50% inorganic. Dentin and cementum together form a structure with relative flexibility, and not prone to structural changes.

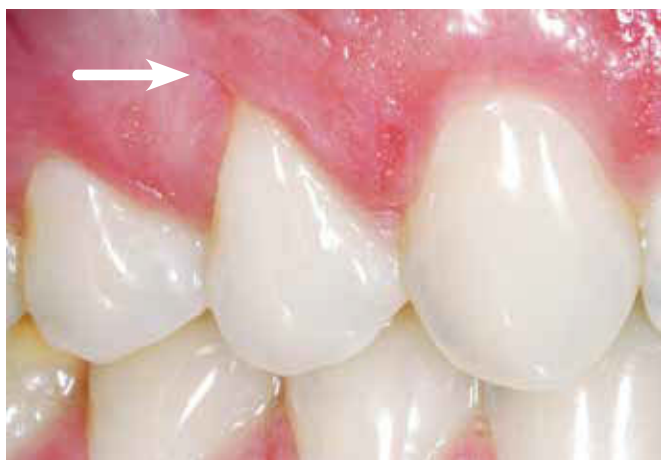Enamel, with its 96% of mineral component, has a minimum, negligible deflection capacity. On the compression side — during a deflection of the tooth as a whole, by occlusal trauma, for example - the enamel resists its effect, but on the traction side, enamel cannot resist, and presents with early fractures and/or cracks in its delicate cervical portion. This process, if repetitive, can lead to fragmentation and loss of enamel structure, which is medically known as abfraction (Figs 2 and 3). Abfraction is very common, especially in youths and in premolars.<sup>2,4,7</sup>

The cracks cannot be seen in the cervical enamel of premolars experiencing this condition. The patient, however, may complain of intense sensitivity to thermal variations in these “healthy” teeth when eating. If the tooth displays wear facets and V-shaped recession (Figures 2 and 3), one may suspect the presence of abfraction, even if only initial, albeit not observable, which would explain this enhanced sensitivity.

### How to spot radiographic signs of occlusal trauma in periodontal tissues

When the periodontal ligament is under compression in primary occlusal trauma a reduction occurs in the diameter of the vessels, with consequent disorganization of fibers and cells. This situation induces cellular stress, with release and greater accumulation of mediators in the periodontal ligament, especially those mediators that can locally influence the constancy rate of bone remodeling.

The local mediators of bone remodeling have a biphasic effect: When accumulated at very high levels, they stimulate bone resorption, while at slightly increased levels they induce new bone formation.



**Figure 2.** V-shaped gingival recession with a minor crack at its end (arrow), related to occlusal trauma.

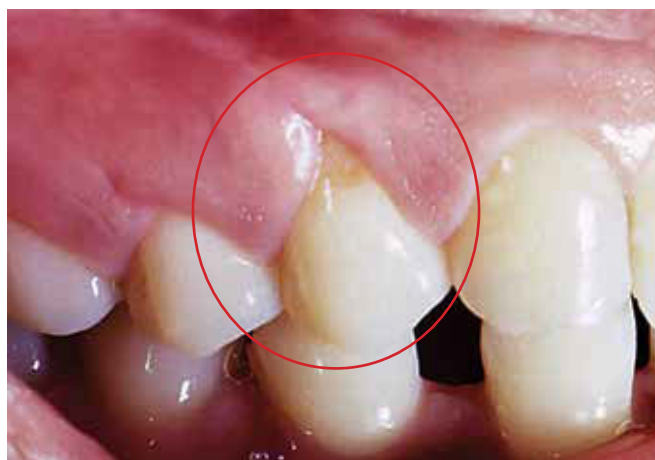Forces delivered to the tooth act as a lever with intra-alveolar rotation and the fulcrum located between the apical and middle thirds of the tooth root. In occlusal trauma, forces tend to be well distributed in the periodontal ligament and overload promotes slightly increased levels of bone remodeling mediators.

This tissue dynamic in occlusal trauma allows one to visualize radiographically the thickening of the lamina dura (Figs 4 and 5) by increasing alveolar cortical bone deposition, reinforcing this structure and elongating the collagen fibers. In other words, the periodontal structures will conform better in order to absorb the increased occlusal forces.

In primary occlusal trauma, collagen fibers must be renewed faster, and the longer and the better organized its bundles, the greater their absorption capacity, and the more effectively excessively repetitive forces are suppressed. Radiographically, one can notice an irregular widening of the periodontal space, since the ligament is constantly undergoing structural reorganization (Figs 4, 5, 6 and 7).

In occlusal trauma, forces are excessive and eccentric, but the periodontal tissues adapt by thickening the alveolar cortical bone, increasing the density of adjacent trabeculate, and irregularly widening the periodontal space. This happens throughout the length and width of tooth root and surrounding tissues (Figs 7, 8, and 9).

In the cervical region of periodontal tissues - given the lever effect produced by the tooth - if occlusal trauma grows too intense and persistent it can cause stretching/traction and/or excessive compression of



**Figure 3.** V-shaped gingival recession in a tooth with abfraction: Two clinical signs of occlusal trauma.

the periodontal ligament. In the cervical region, the accumulation of mediators may rise to the point of stimulating predominantly the activity of bone resorption. The plane parallel to the tooth surface of the lamina dura in this region may undergo some angulation, implying V-shaped bone loss (Figs 4, 7, 9).

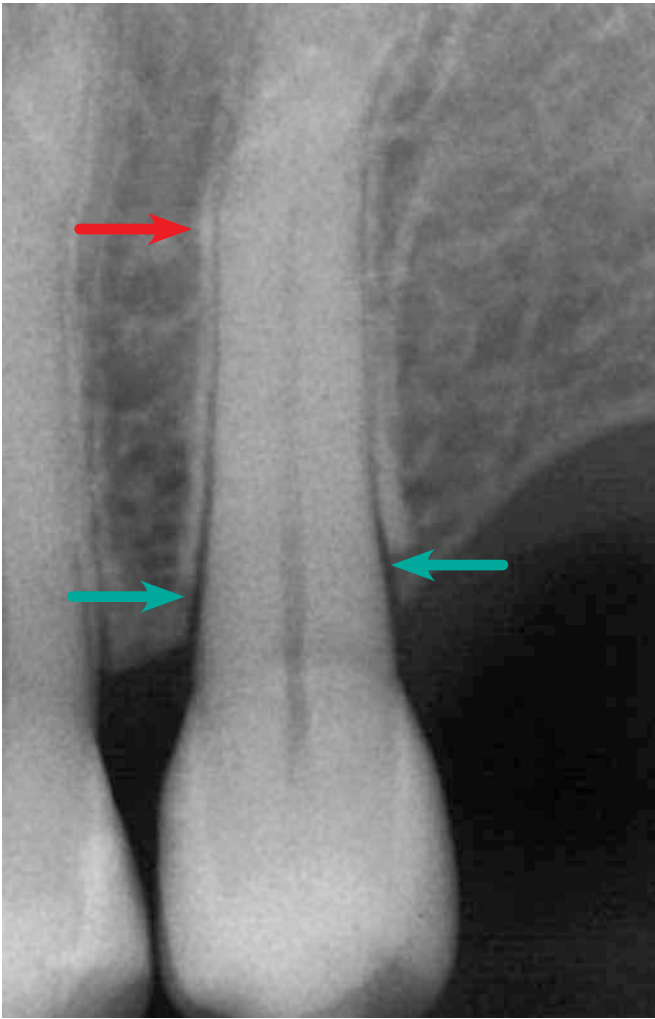
The imaging of this V-shaped bone loss shows some vertical bone loss with no periodontal pocket on probing thoroughly and appropriately. By simply removing the primary cause, i.e., the occlusal trauma, one can restore the original bone level.

Occlusal trauma can thus show its first radiographic signs, i.e., vertical cervical V-shaped bone loss, thickening of the lamina dura, irregular widening of periodontal space, and increases in density or apical bone sclerosis, or in the bone crest (Figs 4 and 9). These signs reflect an attempt by the periodontal tissues to adapt to a new functional demand. Much later, areas of inflammatory root resorption may arise (Figs 10 and 11).

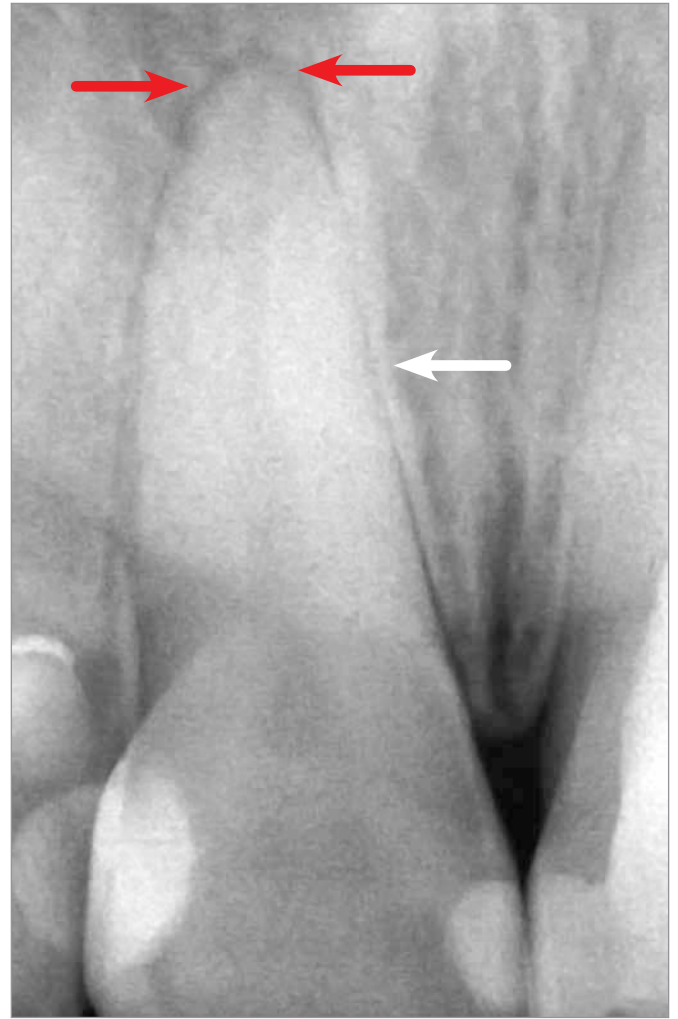
### Effects of occlusal trauma on the buccal free surface of the periodontal ligament and alveolar cortical bone

The same cellular and tissue phenomena that occlusal trauma can induce in the periodontal surface of the ligament facing the alveolar bone crest when subjected to the same type of load and consequent deflection, can also be induced in the free buccal surface.

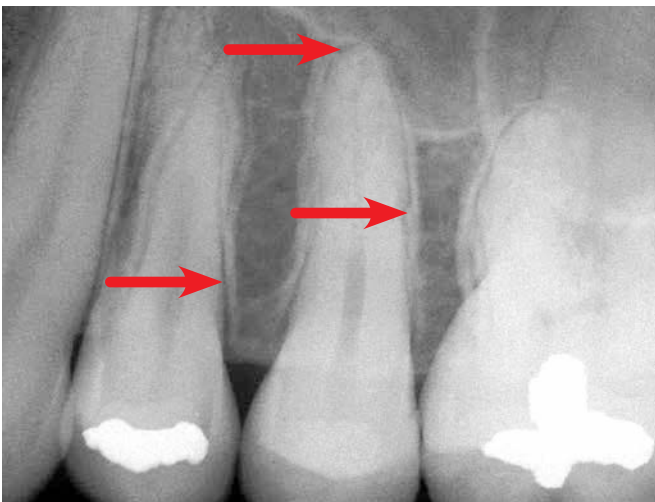
However, the structure of the buccal cortical bone tends to be very thin, and any slight resorption in its periodontal surface can lead to decreased cervical



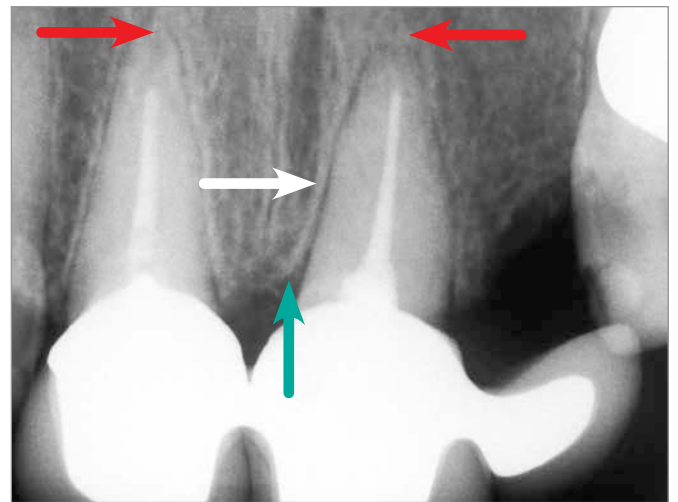
**Figure 4.** Thickening of the lamina dura and widening of the periodontal space (red arrow). Note the V-shaped bone resorption in the cervical region of the alveolar bone crest (green arrows): Initial aspects of occlusal trauma.



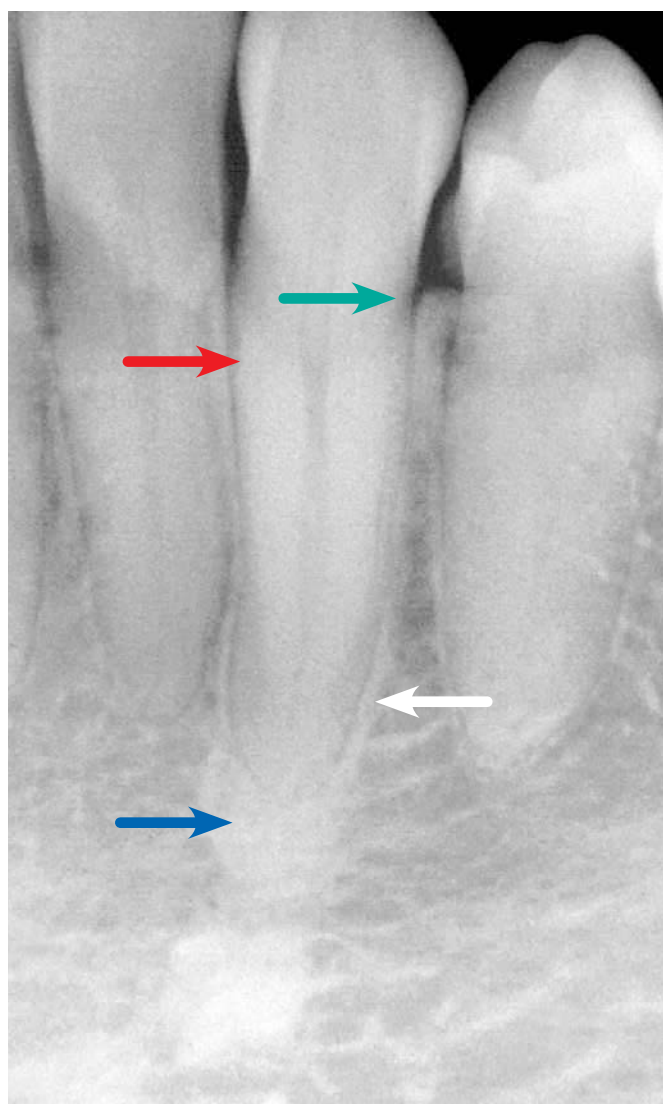
**Figure 6.** Occlusal Trauma with thickening of the lamina dura (white arrow) and widening of the periodontal space with increased diffuse periodontal bone density (red arrows).



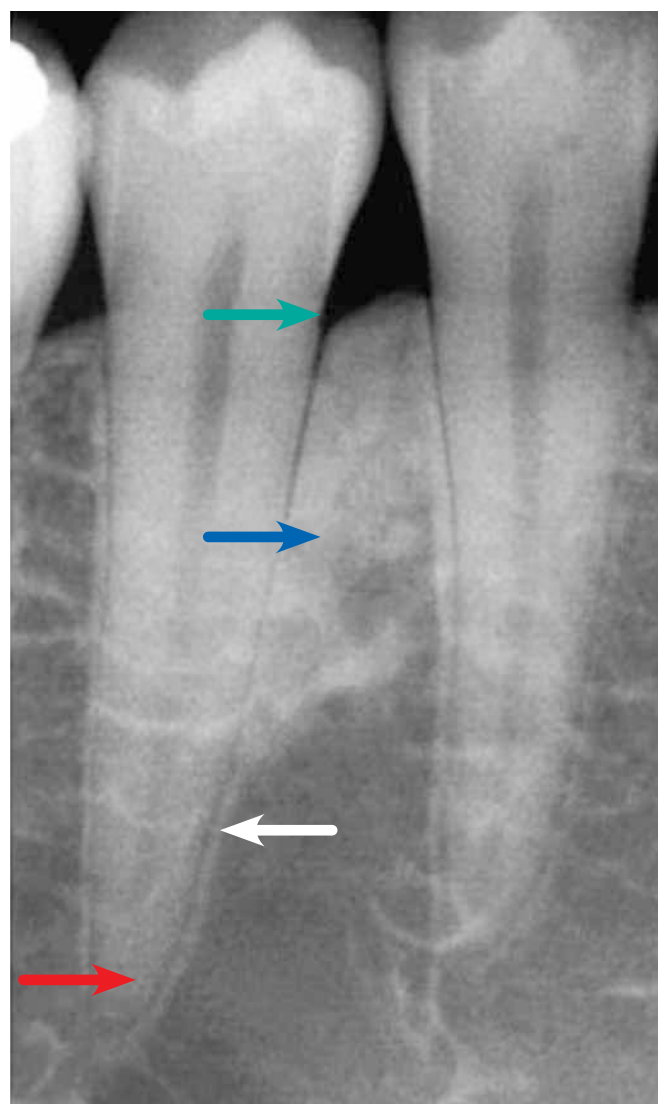
**Figure 5.** Thickening of the lamina dura and widening of the periodontal space (red arrows). Note a slight increase in the density of the alveolar bone crest.



**Figure 7.** Occlusal Trauma with thickening of the lamina dura (white arrow), widening of the periodontal space, increased diffuse periodontal bone density (red arrows), and vertical bone loss (green arrow).



**Figure 8.** Occlusal Trauma with thickening of the lamina dura (white arrow), widening of the periodontal space (red arrows) with increased diffuse periodontal bone density on the bone crest (blue arrow), and vertical bone loss (green arrow).



**Figure 9.** Occlusal Trauma with thickening of the lamina dura (white arrow), widening of the periodontal space (red arrows) with increased periapical periodontal bone density (blue arrow), and V-shaped vertical bone loss (green arrow).

height and V-shaped bone dehiscence on the buccal surface of the affected root (Fig 12).

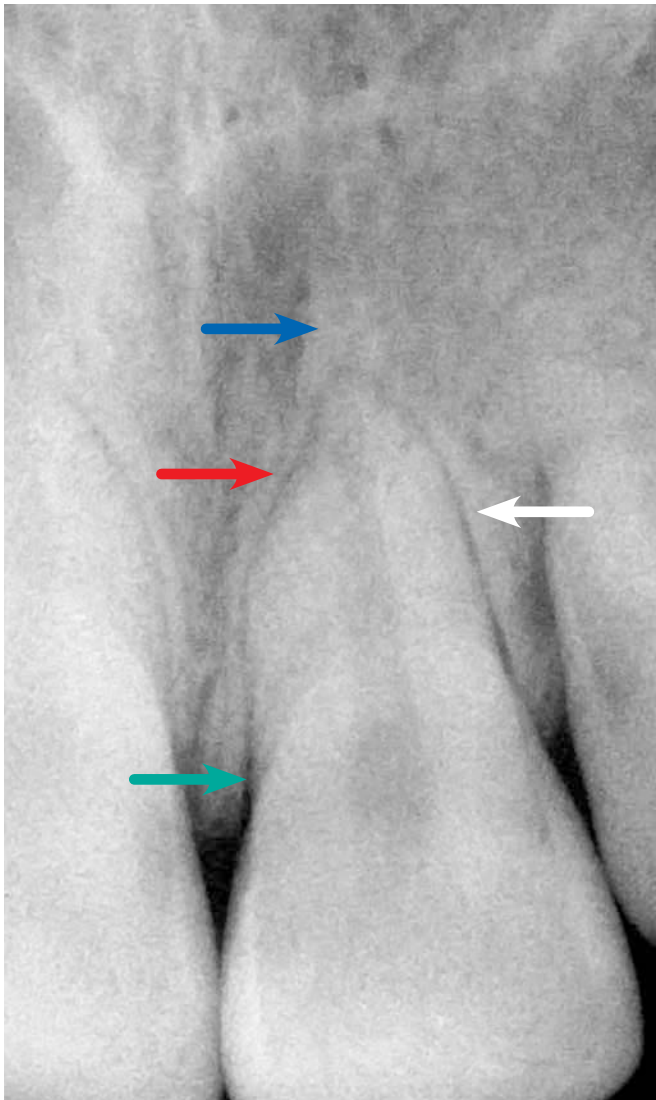
Buccal bone dehiscences are local and specific, and they grow in size through a gradual and slow process. Detection in imaging can be particularly challenging, although some sophisticated tomographic equipment claim to deliver reliable results. Fenestrations further compound the condition (Fig 12).

Upon the emergence of buccal bone dehiscence, the periosteum initially remains in place for a clinically indefinite period. With no bones to coat it, protect it and nourish it with their vessels, the periosteum tends to settle on the margins of the bone dehiscence, and

following these margins while leaving the root surface exposed to gingival and periodontal connective tissue (Fig 12).

### V-shaped gingival recession in occlusal trauma and how it develops

Primarily, occlusal trauma can cause gingival recession, especially V-shaped recession. Some scholars, notably in Scandinavia,<sup>8,11</sup> refuse in principle to accept this finding, and believe that in order for gingival recession to occur it should always be associated with an accumulation of bacterial plaque. This stance has sparked much controversy and heated debate.

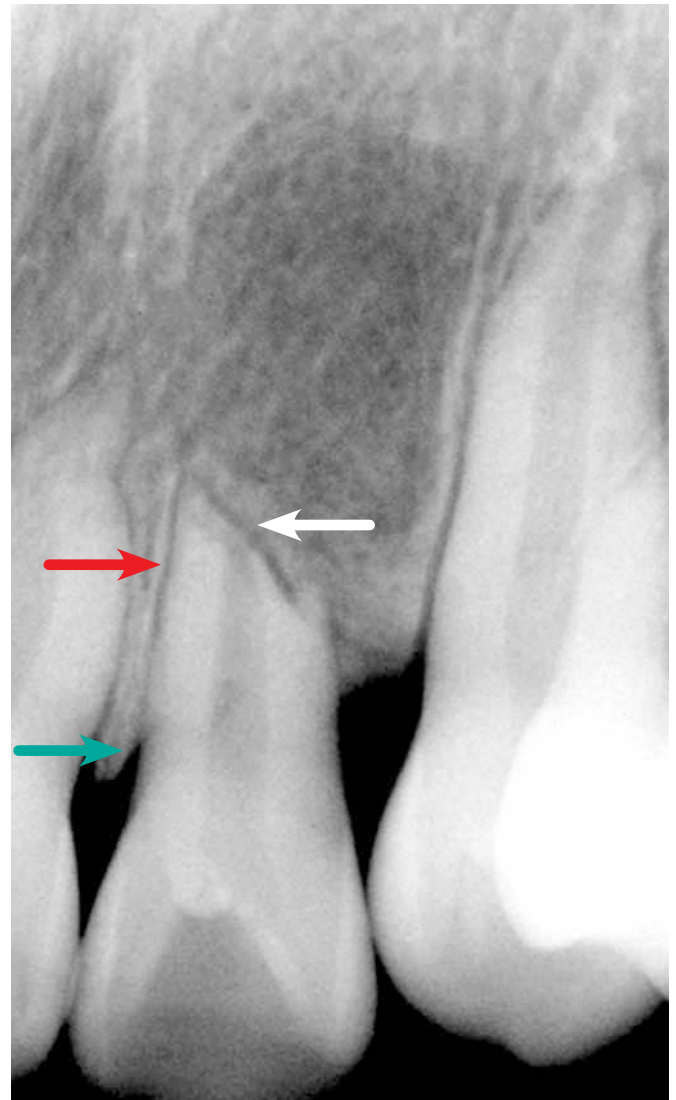


**Figure 10.** Apical inflammatory root resorption associated with occlusal trauma with thickening of the lamina dura (white arrow), widening of the periodontal space (red arrow) with increased periapical periodontal bone density (blue arrow), and V-shaped vertical bone loss (green arrow).

One of the reasons why the Scandinavians claim that bacterial plaque must be present if gingival recession is to develop in occlusal trauma can be explained by the focus of their studies and rationale: They compare occlusal trauma to orthodontic movement, and even call it “orthodontic trauma.”<sup>11</sup>

Gingival recessions can be generalized, compromising several or almost all teeth. Localized recessions can be caused by several factors depending on how they emerge, and are classified as atrophic changes in periodontal tissues.

U-shaped or circular recessions are closely associated with the presence of bacterial plaque and chronic



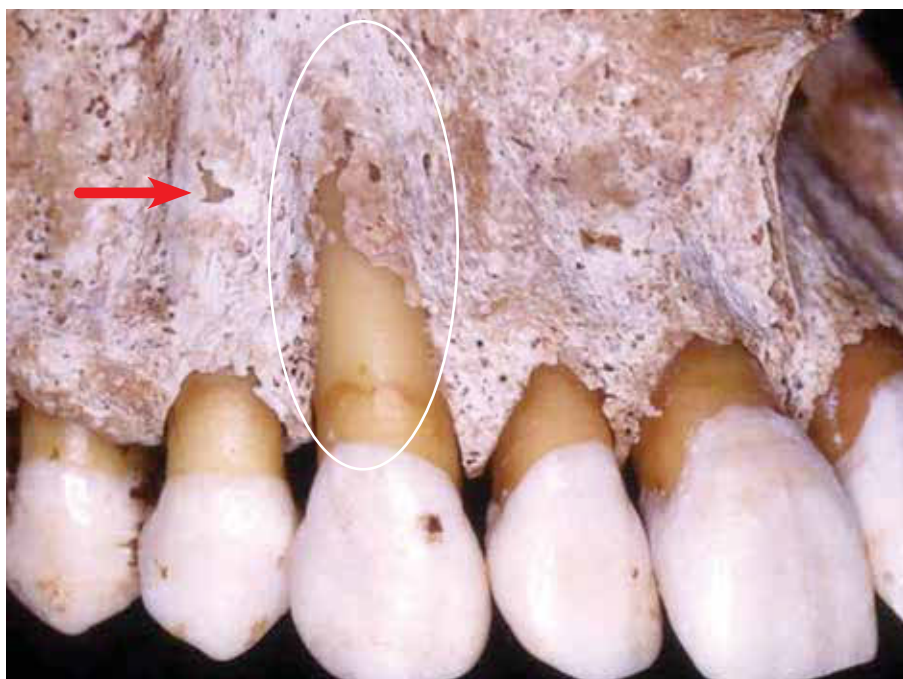
**Figure 11.** Buccal cortical bone of maxillary canine with dehiscence, also showing a small fenestration in the first premolar (arrow). Note the delicate buccal alveolar cortical bone thickness.

inflammatory periodontal disease, frenular attachments, poor brushing technique, and other less common causes.

V-shaped or angled gingival recessions have a small fissure at their most apical end. This type of recession is directly involved in occlusal trauma<sup>12</sup> commonly associated with abfraction<sup>2,7,10</sup> (Figures 2 and 3). In the majority of early cases, elimination of the occlusal trauma leads to a reduction or regression of this V-shaped recession.<sup>12</sup> In many of these cases one can not determine a direct relationship with accumulation of bacterial plaque.

Buccal bone dehiscences - as seen above - tem-





**Figure 12.** Buccal cortical bone of maxillary canine with dehiscence, also showing a small fenestration in the first premolar (arrow). Note the delicate buccal alveolar cortical bone thickness.

porarily enable the linking of two very similar structures which are ultimately fused and reorganized into one single structure over time. The plate or buccal alveolar cortical bone becomes - sometimes very delicately - interposed between the periosteum and the periodontal ligament.

The periosteum is composed of two distinct layers and continuous fibrous connective tissue. The very fibrous outer layer has few cells and naturally joins the richly cellularized and vascularized inner layer. This inner layer directly interfaces with the periosteum and is intersected by fibers which become strongly attached to the mineralized part of the cortical bone.

In the human skeleton, it is solely in tendon attachments and in alveolar cortical bones that the periosteum coats the bone surface. The periodontal ligament sometimes plays the role of the periosteum on the alveolar surface. It can be said that the periodontal ligament provides another manner in which to organize the periosteum.

When the cortical bone is lost due to resorption and dehiscence on the buccal surface of the tooth experiencing primary occlusal trauma, the two structures usually become juxtaposed, but over time, they

should reorganize themselves. With no bone in the region and with the periosteum and periodontal ligament now joined together, the two structures no longer play an active role functionally. The fibrous connective tissue resulting from this condition gradually starts functioning by elongating the connective tissue and attached gingiva, positioned far away from the cervical bone due to the dehiscence.

Bone loss causes the periosteum and ligament to bind together by contiguity or proximity, thereby producing an elongated connective attachment and modified biological distance between the junctional epithelium and cervical bone. If the occlusal trauma persists, there is no way to keep the periodontal fibers functionally

attached to the cementum given the lack of anchorage due to the absence of bone.

Gradually, the periodontal fibers that lack anchorage and the neighboring periosteum without bone reorganize themselves as normal gingival connective tissue. The connective attachment is joined by hyperplasia and epithelial migration, with the development of a long junctional epithelium, which can resist and persist keeping the gingival level at a normal height for a certain period of time under the occlusal trauma.

In continuation, the occlusal trauma may ultimately result in the bone dehiscence being accompanied by the gingival tissue in the form of a V-shaped gingival recession.

Recessions are classified among periodontal diseases as atrophic changes. Without function, increased gingival connective tissue - due to bone loss - tends to remodel itself by volume and organization, similarly to what is found in gums of normal teeth, but this results in exposure of the dental root involved in the process.

The decrease in tissue volume seen in gingival recession is due to periodontal tissue accommodating to a new functional situation, since there is no bone in the area of dehiscence. The reduction in volume

occurs by means of constant and normal tissue remodeling. This remodeling accomplishes the goal of normalizing the tissue relationship and thus restoring the normal proportions between bone, gingival submucosal connective tissue and mucosal, sulcus and junctional epithelia.

While the gingival level is maintained, despite vertical bone loss - provided there is no periodontal pocket - removal of primary occlusal trauma can reverse the process even in the presence of considerable bone loss. In cases where the root has already been exposed in the mouth, restoring the gingival level usually requires surgical procedures with or without grafting of gingival tissue and bone.

### Criteria for diagnosing early occlusal trauma

Primary occlusal trauma can manifest itself clinically (Figs 2 and 3) subtly and incipiently as a triad:<sup>2,7,10</sup>

Wear facets of the areas of interference, abfraction, especially in premolars, and mild V-shaped recession

This triad of signs virtually confirm and reiterate the clinical condition of occlusal trauma, but some cases may display just one or two of these signs. Even before the appearance of V-shaped recession, when only facets and abfraction are present, these signs should indicate to the clinician the need for a thorough analysis. She/he should search for periodontal radiographic signs (Figs 4 to 11) in periapical films, such as:

- » Increased thickness of the lamina dura
- » Irregular thickening of the periodontal space
- » V-shaped vertical bone loss
- » Bone sclerosis in the periapical region and/or interdental bone crest
- » Inflammatory root resorption, more common in the advanced stages of occlusal trauma

Friction-related wear facets<sup>5,6</sup> and abfraction should be corrected, but not without first correcting the occlusal interference, even when gingival recession is already present.

Early diagnosis considerably improves the prognosis of V-shaped gingival recession, and elimination of occlusal trauma may in many clinical cases lead to spontaneous regression.

On vertical percussion, some soreness is seldom noted. Likewise, patients rarely report the sensation that the tooth is the first to touch the teeth during oc-

clusion. These two signs characterize apical periodontitis induced by dental trauma, and those associated with pulp necrosis due to pulpitis.

### Grafts in V-shaped gingival recession associated with occlusal trauma

When gingival recession appears very severe it could mean that the root surface was exposed too long in the mouth under the action of bacterial plaque, thereby irreversibly contaminating the root structure with lipopolysaccharides (LPS).

These surfaces contaminated by LPS, even after relentless scraping and/or treatment with a wide range of acidic and antimicrobial substances will not allow cementoblastic cells to recolonize them to the point of forming new cementum layers. In other words, it will be impossible to reattach periodontal fibers to these surfaces, even after gingival grafts.

In some case reports, the most that can be achieved with surgical procedures — with results being analyzed microscopically at a later date - is the positioning of fibroblasts and collagen fibers parallel to the root surface after scraping and treatment, without reattachment of perpendicular and functional periodontal fibers. This occurs simultaneously and alternately in gum and bone grafting.

The extremely satisfactory outcomes achieved with these surgical procedures using gingival grafts stem from the formation of a long junctional epithelium and the maintenance of post-operative gingival levels indefinitely. Epithelial cells can colonize these tooth surfaces previously exposed in the mouth and contaminated by LPS, after the surfaces have been scraped and treated.

Unfortunately, consistent evidence to confirm these clinically obtained results is still lacking, mainly due to methodological difficulties in clinical and experimental work. As for the reattachment of fibers to surfaces previously exposed for long periods in the mouth, under the agency of bacterial plaque, no sound, methodological evidence is available as yet.

### Conclusions

In endodontic practice, diagnoses tend to be based on subtle signs and symptoms, requiring great care and prior knowledge by the specialist. Occlusal trauma should be included in the differential diagnosis of

apical periodontitis and dental trauma.

Increased periapical bone density of the periapical sclerosing osteitis type, associated with tooth pulp vitality, may favor a diagnosis of occlusal trauma, even in the presence of inflammatory root resorption.

Perhaps ideally, when a tooth presents with pulp necrosis and signs of occlusal trauma, one should try to establish - based on patient history and diagnostic tests - a diagnosis of superimposed dental trauma, even in posterior teeth. Here are some situations likely to cause dental injuries such as concussion in posterior teeth leading to pulp necrosis:

- » Anchoring surgical levers on neighboring teeth during extractions
- » Accidentally bumping instruments like forceps during surgical procedures
- » Allowing instruments to slip on probing during

gastroesophageal examinations

- » Moving laryngoscopes during general anesthesia procedures
- » Presence of sweets and other food in the mouth during sporting and leisure activities, and during sudden movements performed when riding on a motorcycle or roller coaster, for example.

Occlusal interferences and overloads take months or years to induce the classic signs and symptoms of occlusal trauma as a clinical entity. Correction of these occlusal overloads and interferences will typically avert these signs and symptoms. The presence of occlusal interferences and overloads does not necessarily indicate that the signs and symptoms of the clinical entity called occlusal trauma are present: They may take many months before emerging in the clinical context and in different imaging methods.

## References

1. Consolaro A. Reabsorções dentárias nas especialidades clínicas. 3ª ed. Maringá: Dental Press; 2012.
2. Consolaro A. Abrasão dentária: importância do seu diagnóstico diferencial com outras lesões cervicais. *Rev Dental Press Estét.* 2007;4(2):124-32.
3. Consolaro A. Trauma oclusal antes, durante e depois do tratamento ortodôntico: aspectos morfológicos de sua manifestação. *Rev Dental Press Ortod Ortop Facial.* 2008;13(6):21-4.
4. Consolaro A. A recessão gengival em forma de V como manifestação clínica do trauma oclusal. *Rev Clín Ortod Dental Press.* 2012;11(5):130-5.
5. Consolaro A. Occlusal trauma can not be compared to orthodontic movement. *Dental Press J Orthod.* 2012;17(6):4-11.
6. Consolaro A. Significado da recessão em forma de V: a tríade. *Rev Dental Press Estét.* 2012;9(4):126-35.
7. Consolaro A, Consolaro MFMO. Abfração: hipersensibilidade, trauma oclusal e outras lesões cervicais não cáries. *Rev Dental Press Estét.* 2006;3(3):122-31.
8. Consolaro A, Consolaro MFMO, Francischone L. Atrição e suas implicações clínicas. *Rev Dental Press Estét.* 2007;4(1):124-32.
9. Consolaro A, Francischone L, Consolaro MFMO. Atrição dentária: implicações ortodônticas. Quem envelhece mais o arco dentário: o apinhamento ou a atrição? *Rev Clín Ortod Dental Press.* 2008 Dez-2009 Jan;7(6):102-9.
10. Consolaro A, Consolaro MFMO. Abfração dentária no diagnóstico e planejamento ortodôntico. O que significa? *Rev Clín Ortod Dental Press.* 2009;8(1):104-9.
11. Lindhe J, Karring T, Lang NP. Tratado de periodontia clínica e implantologia oral. 3ª ed. Rio de Janeiro: Guanabara Koogan; 1999.
12. Solnit A, Curnutte D. Occlusal correction principles and practice. Chicago: Quintessence; 1988.
13. Stillman PR. The management of pyorrhea. *Dent Cosmos.* 1917;59:405-14.
14. Thiago A, Araújo MG. Trauma oclusal causa recessão gengival? *Rev Dental Press Periodontia Implantol.* 2009;3(1):30-2.
15. Krstic, RV. Human microscopic anatomy. Springer-Verlag, Berlin, 1994.