

Subcutaneous tissue reaction to modified Portland cement (CPM)

João Eduardo **GOMES FILHO**¹
Max Douglas **FARIA**²
Simone **WATANABE**²
Carolina Simonetti **LODI**²
Luciano Tavares Angelo **CINTRA**²
Eloi **DEZAN JUNIOR**¹
Pedro Felício Estrada **BERNABÉ**¹

ABSTRACT

Introduction: The aim of this study was to evaluate the rat subcutaneous tissue response to implanted polyethylene tubes filled with Modified Portland Cement (CPM[®]) (Egeo S.R.L., Buenos Aires, Argentina) compared with Angelus MTA[®] (Angelus, Londrina, Brazil). **Methods:** These materials were placed in polyethylene tubes and implanted into dorsal connective tissue of Wistar rats for 7, 15, 30, 60, and 90 days. The specimens were prepared and stained with hematoxylin and eosin or Von Kossa or not stained for polarized light. Qualitative and quantitative evaluations of the

reaction were performed. **Results:** Both materials caused moderate reactions at 7 days that decreased with time. Angelus MTA[®] caused mild reactions at 15 days that decreased with time. The response was similar to the control on 30, 60 and 90 days with CPM[®] and Angelus MTA[®]. Mineralization and birefringent to the polarized light granulations were observed with both materials. **Conclusions:** It was possible to conclude that CPM[®] and Angelus MTA[®] were biocompatible in the rat model, and that they stimulated mineralization.

Keywords: Biocompatibility. Connective tissue. Mineral trioxide aggregate.

How to cite this article: Gomes Filho JE, Faria MD, Watanabe S, Lodi CS, Cintra LTA, Dezan Junior E, Bernabé PFE. Subcutaneous tissue reaction to modified Portland cement (CPM). *Dental Press Endod.* 2012 Apr-June;2(2):47-52.

» The authors report no commercial, proprietary, or financial interest in the products or companies described in this article.

Submitted: June 22, 2012 / Accepted: July 4, 2012.

¹ Full Professor in Endodontics, FOA-UNESP.

² PhD in Pediatric Dentistry, FOA-UNESP.

Contact address: João Eduardo Gomes Filho
Rua José Bonifácio, 1193 – Zip code: 16015-050 – Araçatuba/SP, Brazil
E-mail: joao@foa.unesp.br

Introduction

Endodontic repair materials should adhere to tooth structure, maintain a sufficient seal, be insoluble in tissue fluids, dimensionally stable, non-resorbable, radiopaque, and exhibit biocompatibility if not bioactivity. A number of materials have historically been used in apical surgeries and perforation but none has been able to satisfy the total requirements of an ideal material.¹

Mineral trioxide aggregate (MTA) is a biomaterial that has been investigated for endodontic applications since the early 1990's and was first described in the dental scientific literature in 1993.² It received approval for endodontic use by the U.S. Food and Drug Administration in 1998.³ Studies have shown that MTA promotes favorable tissue reactions characterized by the absence of severe inflammatory responses, the presence of a fibrous capsule, and the induction of mineralized repair tissue.^{4,5,6} MTA has been used for both surgical and nonsurgical applications, such as root-end filling, perforation repair, direct pulp capping, and apexification.⁴⁻⁸ Compared with other filling materials, MTA has good sealing ability, superior biocompatibility and antimicrobial activity.⁹⁻¹²

The MTA powder is mixed with sterile water and it is recommended that a moist cotton ball be temporarily placed in direct contact with the material and left until a follow-up appointment. Upon hydration, MTA materials form a colloidal gel that solidifies to a hard structure in approximately 3-4 h,^{1,13,14} with moisture from the surrounding tissues supposedly assisting the setting reaction.⁵ Hydrated MTA products have an initial pH of 10.2, which rises to 12.5 three hours after mixing.^{1,14,15} The setting process is described as a hydration reaction of tricalcium silicate ($3\text{CaO}\cdot\text{SiO}_2$) and dicalcium silicate ($2\text{CaO}\cdot\text{SiO}_2$), which is the latter said to be responsible for the development of material strength.^{1,13} Although weaker than other materials used for similar purposes, MTA compressive strength has been reported to increase in the presence of moisture for up to 21 days.^{1,14} In 2001, the company Angelus Soluções Odontológicas introduced a MTA developed in Brazil, which is similar to the Modified Portland Cement. The powder also consists of fine hydrophilic particles that form a colloidal gel in presence of moisture, solidifying to form a hard sealer in one hour.^{16,18} The presence of calcium carbonate is the most significant difference, which has been reported to increase the release of calcium ions, but maintaining the sealability, adhesion, flow rate,

and biocompatibility.^{19,20} Its package insert states that the chemical composition is similar to the MTA, except for the addition of calcium carbonate to reduce the pH from 12.5 to 10.0 after setting and to restrict the surface necrosis in contact with the material.

Although CPM[®] apparently presents positive characteristics, there is no study evaluating the reaction after its implantation. Thus, the aim of this study was to evaluate the tissue response of CPM[®] (Egeo S.R.L., Buenos Aires, Argentina), compared to Angelus MTA[®] (Angelus, Londrina, Brazil) in a rat model.

Material and methods

Thirty male 4- to 6-month-old *Wistar albino* rats, weighing 250 to 280 g, were used. The animals were housed in temperature-controlled rooms and received water and food *ad libitum*. The care of the animals was performed according to the Araçatuba Dental School/UNESP ethical committee, which approved the project before the beginning of the experiments.

Sixty polyethylene tubes (Abbott Lab of Brazil, São Paulo, SP, Brazil) with 1.0-mm internal diameter, 1.6-mm external diameter, and 10.0-mm length were filled with the tested materials. The Angelus MTA[®] and the CPM[®] were prepared according to the manufacturer's recommendations and inserted into the tubes (30 tubes for each material) with a Lentulo spiral (Maillefer Dentsply, Tulsa, USA). Thirty extra polyethylene tubes remained empty and were used as control.

The animals received antisepsis with 5% iodine solution and then shaved under xylazine (10 mg/kg) and ketamine (25 mg/kg) anesthesia. The shaved backs received a 2-cm incision in a head-to-tail orientation with a #15 Bard-Parker[™] blade (Franklin Lakes, NJ). The skin was reflected, creating two pockets in one side of the incision, one in the cranial portion and other in the caudal portion distant 6 cm from each other, and another pocket in the opposite side of the incision. The tubes were implanted into the spaces created with blunt dissection, and the skin was closed with 4/0 silk suture.

After 7, 15, 30, 60, and 90 days from the implantation time, six animals were killed by overdose of anesthetic solution, and the tubes with surrounding tissues were removed and fixed in 10% buffered formalin at pH 7.0.^{21,22} The tubes were bisected transversely and both halves were cut again longitudinally with the use of a sharp blade. This procedure was done to allow the

surfaces to be readily kept in contact with the processing solutions. The specimens were processed for glycol methacrylate embedding, serially sectioned into 3- μm cuts, and stained with hematoxylin-eosin.²³ The 10- μm cuts were stained according to the Von Kossa technique or remained without staining to be observed under polarized light. The Von Kossa technique was used to observe mineralized structures in the tissue, which were dark stained. Polarized light technique allows the observation of birefringent structures related to calcium carbonate crystals generated from the combination of calcium ions from the material and carbonic gas from the tissue.²⁴

Reactions in the tissue in contact with the material on the opening of the tube were scored according to previous studies^{22,25,26} as: 0= none or few inflammatory cells and no reaction; 1= less than 25 cells and mild reaction; 2= between 25 and 125 cells and moderate reaction; and 3= 125 or more cells and severe reaction. Fibrous capsules were considered to be thin when thickness was <150 μm and thick at >150 μm . Necrosis and calcification were recorded as present or absent. The observer was blinded to treatment allocation. An average of the number of cells for each group was obtained from 10 separate areas. Results were statistically analyzed by analysis of variance (one-way ANOVA) and Kruskal-Wallis tests at 5% of significance.

Results

Angelus MTA[®]

On the 7th day, a moderate inflammatory cell infiltration was present in a fibrous capsule (Fig 1A). The intensity of the inflammation was reduced on days 15, 30, 60, and 90 with a thin fibrous capsule near the tube and small number of inflammatory cells (Figs 1B, C and D). Granulations birefringent to polarized light and Von Kossa positive structures were observed near the tube opening (Figs 2A, B, C and D).

CPM

On days 7 and 15, a moderate inflammatory cell infiltration consisting of lymphocytes and macrophages was present in a fibrous capsule (Fig 1E). The intensity of the inflammation and the thickness of the fibrous capsule were reduced on day 30, similar to the control group (Fig 1F). On days 60 and 90, few chronic inflammatory cells were present in a thin fibrous capsule similar to the Angelus MTA[®] and the control group (Figs 1G and H).

Granulations birefringent to polarized light and Von Kossa positive structures were observed in close contact with the CPM[®] (Figs 2E, F, G and H). It was observed that there was tissue growing into the tubes for many of the examined specimens.

Control (empty tubes)

On days 7 and 15, a moderate chronic inflammatory cell infiltration consisting of lymphocytes and macrophages was present in a fibrous capsule (Fig 1I). The fibrous capsule surrounding the tube was thin with few chronic inflammatory cells present at 30, 60, and 90 days (Figs 1J, K and L). The empty tubes were not positive to Von Kossa stain, and no birefringent structures were observed under the polarized light (Figs 2I, J, K and L).

Comparison among the groups

The data were compared in each period of time and are present in Table 1.

Day 7

There was no statistically significant difference among the scores of the different groups (median = score 2).

Day 15

There was a statistically difference ($p < 0.05$) between inflammatory cell numbers with Angelus MTA[®] and the other groups ($p < 0.05$). The median inflammatory cell score for MTA (median score = 1) was lower than the other groups (median score = 2) ($p < 0.05$).

Days 30, 60 and 90

There was no statistically significant difference ($p > 0.05$) among the scores of the different groups (median score = 1).

Discussion

The physical properties, sealing ability, biocompatibility, and clinical performance of MTA materials have been reported. MTA materials appear not only to demonstrate acceptable biocompatibility behavior but also exhibit acceptable in vivo biologic performance when used for root-end fillings, perforation repairs, pulp-capping and pulpotomy, and apexification treatment.²⁷

The response to empty tubes in this study showed minor reactions in subcutaneous connective tissues, consistent with results previously reported.^{22-26,28}

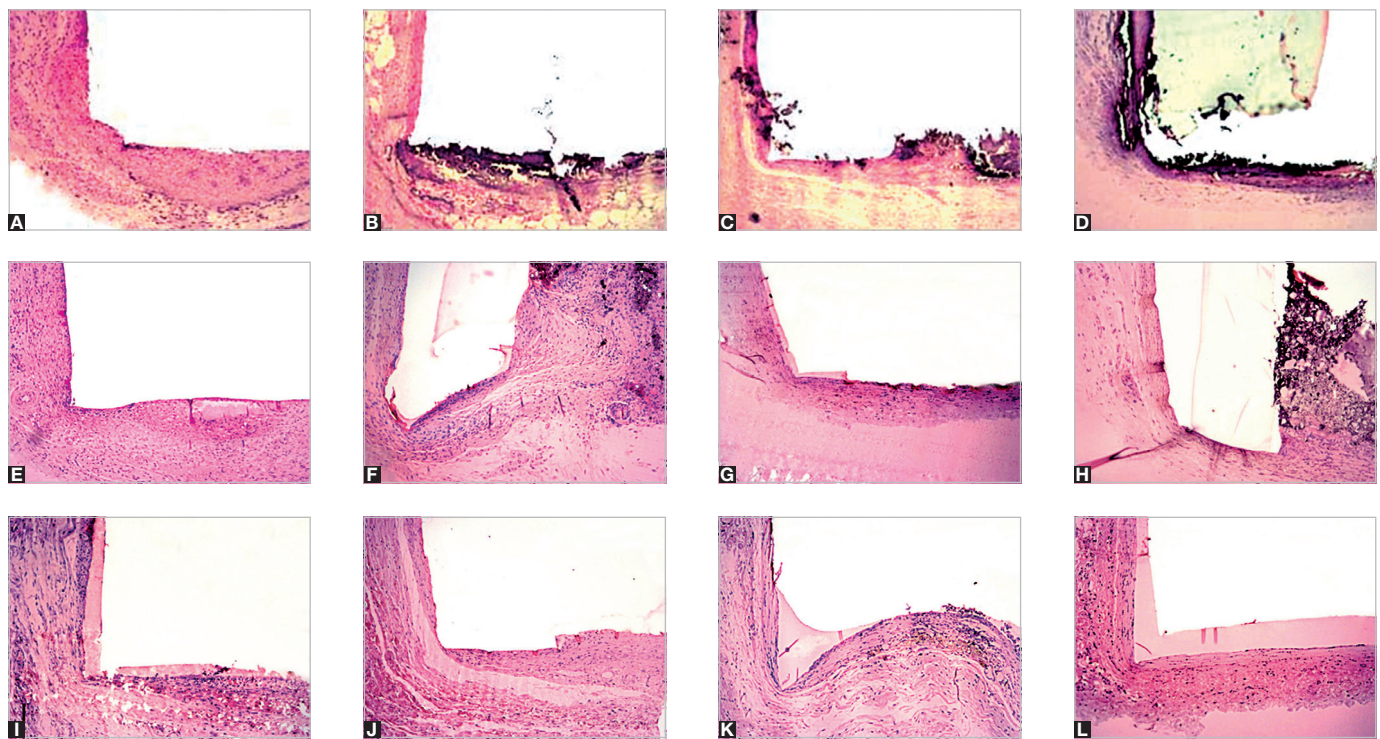


Figure 1. Angelus MTA: **A)** thick fibrous capsule and moderate inflammatory cell infiltration consisting of lymphocytes and macrophages (7 days, hematoxylin and eosin, 10x), and **B-D)** the fibrous capsule surrounding the tube was thin with few chronic inflammatory cells (30, 60, and 90 days, respectively; hematoxylin and eosin, 10x). CPM: **E)** thick fibrous capsule formation and moderate inflammatory cell infiltration (7 days, hematoxylin and eosin, 10x), and **F-H)** mild chronic inflammatory cell infiltration in a thin fibrous capsule (30, 60, and 90 days, respectively; hematoxylin and eosin, 10x). Control: **I)** moderate chronic inflammatory cell infiltration and thick fibrous capsule formation (7 days, hematoxylin and eosin, 10x), **J-L)** reduction in thickness of fibrous capsule and inflammatory cell near tube infiltration (30, 60, and 90 days, respectively; hematoxylin and eosin, 10x).

Table 1. Percentage of samples in each group classified according to the index of inflammation, presence of necrosis and fibrous capsule thickness.

MATERIAL/ TIME	SCORE				Calcification
	0	1	2	3	
7 days					
MTA	0	0	100	0	100
CPM	0	0	100	0	100
Control	0	0	100	0	0
15 days					
MTA	0	100	0	0	100
CPM	0	0	100	0	100
Control	0	0	100	0	0
30 days					
MTA	0	100	0	0	100
CPM	0	100	0	0	100
Control	0	100	0	0	0
60 days					
MTA	0	100	0	0	100
CPM	0	100	0	0	100
Control	0	100	0	0	0
90 days					
MTA	0	100	0	0	100
CPM	0	100	0	0	100
Control	0	100	0	0	0

An adequate tissue repair was found in the connective tissue around the tubes containing Ângelus® MTA and it showed a mild chronic inflammatory response at 30 days, characterized by organized connective tissue, with presence of some macrophages and inflammatory multinuclear cells, similar to other studies.^{11,24,25,29} In all periods of time, Von Kossa areas positive for calcium and structures birefringent to polarized light were observed for all specimen, which were similar to the results previously reported.²⁴ It was possible to observe at 30 days that Ângelus® MTA also promoted a tissue response characterized by a fibrous capsule, a mild inflammatory infiltrate, in accordance with other studies.^{24,25} At 60 and 90 days, it was possible to notice a decrease of the inflammatory cells number and thickness of fibrous capsule adjacent to the tube opening, similar to that described in the literature.^{24,25}

Moreover, the results of the present study taken together with those previously reported corroborate with the promotion of dystrophic calcifications by MTA in contact with connective tissues. These calcifications can be originated from the calcium oxide present in MTA.²⁴

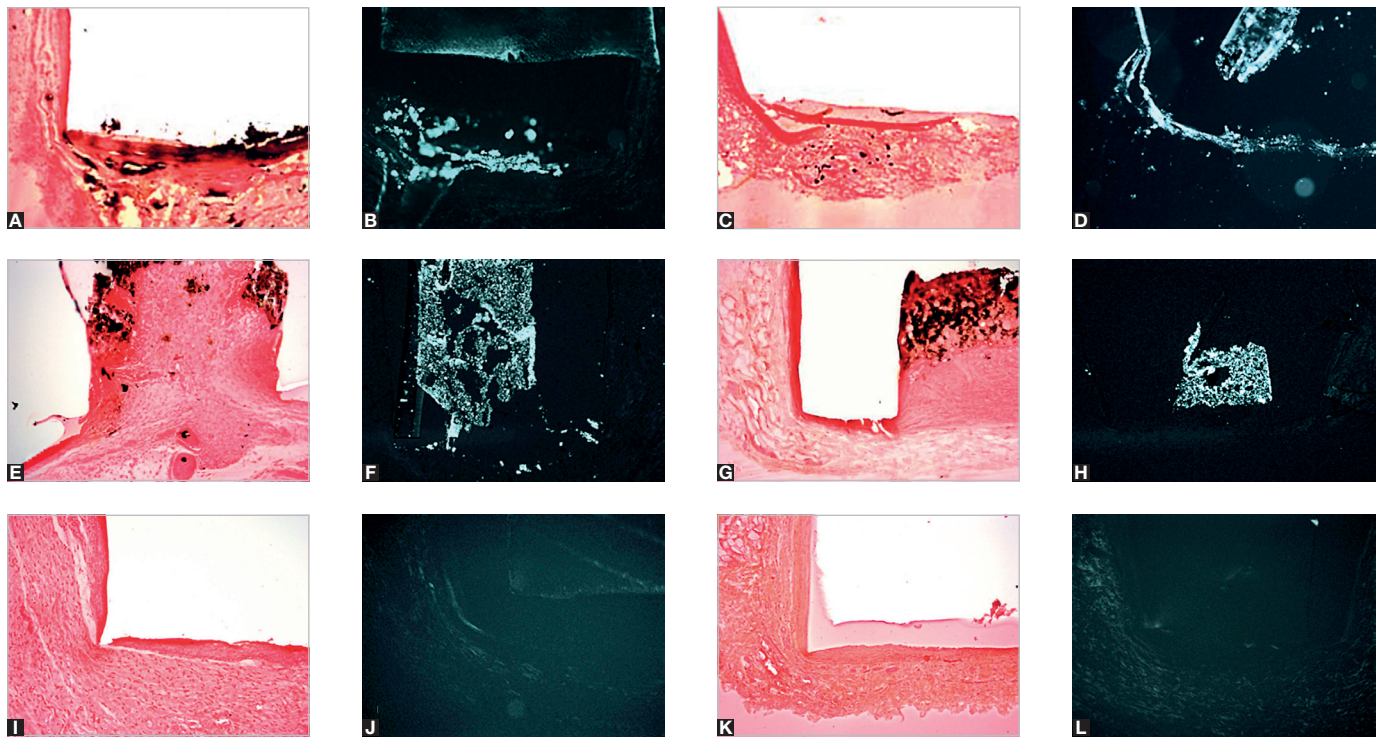


Figure 2. Angelus MTA: **A** and **C**) presence of dystrophic calcification on the tube opening (30 and 90 days, respectively; Von Kossa, 10x); **B** and **D**) presence of structures birefringent to polarized light (30 and 90 days, respectively; polarized light, 10x). CPM: **E** and **G**) presence of dystrophic calcification on the tube opening (30 and 90 days, respectively; Von Kossa, 10x); **F** and **H**) presence of structures birefringent to polarized light (30 and 90 days, respectively; polarized light, 10x). Control: **I** and **K**) absence of dystrophic calcification on the tube opening (30 and 90 days, respectively; Von Kossa, 10x); **J** and **L**) absence of structures birefringent to polarized light (30 and 90 days, respectively; polarized light, 10x).

This component, when in contact with water can be converted into calcium hydroxide and dissociated in Ca_2^+ and OH^- . The diffusion of hydroxyl ions from the root canal raises the pH at the surface of root adjacent to the periodontal tissues, thereby possibly interfering with osteoclastic activity, and promotes an alkalization in the adjacent tissues favoring the healing process.³⁰ Calcium ions are important due to their participation in the activation of calcium-dependant adenosine triphosphatase.³¹ Calcium reacts with carbonic gas to form calcium carbonate crystals (birefringent to polarized light), which serve as a nucleus for calcification, and favors mineralization.³¹ A rich extra-cellular fibronectin network in close contact with these crystals strongly support the role of calcite crystals and fibronectin as an initiating step in the formation of a hard tissue.³¹ Calcium is also needed for cell migration and differentiation.³²

According to the manufacturer, CPM[®] has similar properties compared to MTA and the same clinical indications.² In this study, the results observed with CPM[®] were similar to the control and MTA groups, showing a moderate chronic inflammatory response in the initial

periods that reduced with time. Positive Von Kossa areas and structures birefringent under polarized light were also observed showing that this material stimulated the formation of mineralized tissue in subcutaneous tissue of rats similarly to that observed with MTA.²⁴ Although the manufacturer stated that calcium carbonate had been added to the material to reduce the pH from 12.5 to 10.0, it was not observed changes in the biological behavior of CPM[®] when compared to the MTA.

An interesting fact observed with CPM[®] was the tissue ingrown into the tube for many of the specimens examined, that showed a high solubility of the material. A material with high solubility is not suitable for the endodontic use since it may not promote an adequate sealing, thereby increasing the probability of failure in endodontic treatment. Previous results showed poorer sealability of CPM[®] in comparison to Angelus MTA[®] when used as apical plug.¹⁶

In conclusion, the tissue reactions observed with CPM[®] were similar to those observed and reported for Angelus MTA[®]. Other studies are necessary to better analyze the behavior of this material.

References

1. Roberts HW, Toth JM, Berzins DW, Charlton DG. Mineral trioxide aggregate material use in endodontic treatment: A review of the literature. *Dent Mater*. 2008 Feb;24(2):149-64.
2. Lee SJ, Monsef M, Torabinejad M. Sealing ability of a mineral trioxide aggregate for repair of lateral root perforations. *J Endod*. 1993;19(11):541-4.
3. Schmitt D, Lee J, Bogen G. Multifaceted use of ProRoot MTA root canal repair material. *Pediatr Dent*. 2001 Jul-Aug;23(4):326-30.
4. Ford TR, Torabinejad M, McKendry DJ, Hong CU, Kariyawasam SP. Use of Mineral Trioxide Aggregate for repair of furcal perforations. *Oral Surg Oral Med Oral Pathol Oral Radiol Endod*. 1995 Jun;79(6):756-63.
5. Bernabé PF, Holland R, Morandi R, de Souza V, Nery MJ, Otoboni Filho JA, et al. Comparative study of MTA and other materials in retrofilling of pulpless dogs' teeth. *Braz Dent J*. 2005;16(2):149-55.
6. Gomes Filho JE, Watanabe S, Bernabé PF, de Moraes Costa MT. A Mineral Trioxide Aggregate sealer stimulated mineralization. *J Endod*. 2009 Feb;35(2):256-60.
7. Menezes R, Bramante CM, Letra A, Carvalho VG, Garcia RB. Histologic evaluation of pulpotomies in dog using two types of mineral trioxide aggregate and regular and white Portland cements as wound dressings. *Oral Surg Oral Med Oral Pathol Oral Radiol Endod*. 2004 Sep;98(3):376-9.
8. Oliveira TM, Sakai VT, Silva TC, Santos CF, Abdo RC, Machado MA. Mineral trioxide aggregate as an alternative treatment for intruded permanent teeth with root resorption and incomplete apex formation. *Dent Traumatol*. 2008 Oct;24(5):565-8.
9. Hwang YC, Lee SH, Hwang IN, Kang IC, Kim MS, Kim SH, et al. Chemical composition, radiopacity, and biocompatibility of Portland cement with bismuth oxide. *Oral Surg Oral Med Oral Pathol Oral Radiol Endod*. 2009 Mar;107(3):e96-102.
10. Funteas UR, Wallace JA, Fochtman EW. A comparative analysis of mineral trioxide aggregate and Portland cement. *Aust Endod J*. 2003 Apr;29(1):43-4.
11. Holland R, Souza V, Nery MJ, Faraco IM Jr, Bernabé PF, Otoboni Filho JA, et al. Reaction of rat tissue to implanted dentin tube filled with mineral trioxide aggregate, Portland cement or calcium hydroxide. *Braz Dent J*. 2001;12(1):3-8.
12. Saidon J, He J, Zhu Q, Safavi K, Spangberg LS. Cell and tissue reactions to mineral trioxide aggregate and Portland cement. *Oral Surg Oral Med Oral Pathol Oral Radiol Endod*. 2003 Apr;95(4):483-9.
13. Dammaschke T, Gerth HUV, Zuchner H, Schafer E. Chemical and physical surface and bulk material characterization of white ProRoot MTA and two Portland cements. *Dent Mater*. 2005 Aug;21(8):731-8.
14. Torabinejad M, Hong CU, McDonald F, Pitt Ford TR. Physical and chemical properties of a new root-end filling material. *J Endod*. 1995 Jul;21(7):349-53.
15. Camilleri J, Montesin FE, Brady K, Sweeney R, Curtis RV, Pitt Ford TR. The constitution of mineral trioxide aggregate. *Dent Mater*. 2005 Apr;21(4):297-303.
16. Orosco FA, Bramante CM, Garcia RB, Bernardineli N, Moraes IG. Sealing ability of Gray MTA Angelus, CPM and MBPC used as apical plugs. *J Appl Oral Sci*. 2008 Jan-Feb;16(1):50-4.
17. Duarte MAH, Demarchi ACCO, Yamashita JC, Kuga MC, Fraga SC. pH and calcium ion release of 2 root-end filling materials. *Oral Surg Oral Med Oral Pathol Oral Radiol Endod*. 2003;95(3):345-7.
18. Bramante CM, Bramante AS, Moraes IG, Bernardineli N, Garcia RB. CPM es MTA: nuevos materiales de uso en endodoncia – experiencias clinicas en el manejo de los materiales. *Rev Fac Odontol*. 2006;17:7-10.
19. Vasconcelos BC, Bernardes RA, Cruz SML, Duarte MAH, Padilha PM, Bernardineli N, et al. Evaluation of pH and calcium ion release of new root-end filling materials. *Oral Surg Oral Med Oral Pathol Oral Radiol Endod*. 2009 Jul;108(1):135-9.
20. Bramante CM, Bramante AS, Moraes IG, Bernardineli N, Garcia B. CPM es MTA: nuevos materiales de uso en endodoncia: exemplos clinicos en el manejo de los materiales. *Rev Fac Odontol*. 2006;17:7-10.
21. American National Standards Institute. Revised American National Standards Institute American Dental Association. Document No. 41. For recommended standard practices for biological evaluation of dental materials. New York (NY): American National Standards Institute; 1979.
22. Federation Dentaire International Recommended standard practices for biological evaluation of dental materials. Federation Dentaire International Commission on Dental Materials, Equipment, and Therapeutics. Part 4.11: Subcutaneous implantation test. *Int Dental J* 1980;30:173-4.
23. Gomes Filho JE, Gomes BPPA, Zaia AA, Novaes PD, Souza Filho FJ. Glycol methacrylate: An alternative method for embedding subcutaneous implants. *J Endod*. 2001;27(4):266-8.
24. Holland R, Souza V, Nery MJ, Otoboni Filho JA, Bernabé PFE, Dezan Junior E. Reaction of rat connective tissue to implanted dentin tubes filled with mineral trioxide aggregate or calcium hydroxide. *J Endod*. 1999;25(3):161-6.
25. Yaltirik M, Ozbas H, Bilgic B, Issever H. Reactions of connective tissue to mineral trioxide aggregate and amalgam. *J Endod*. 2004 Feb;30(2):95-9.
26. Costa CA, Teixeira HM, do Nascimento AB, Hebling J. Biocompatibility of two current adhesive resins. *J Endod*. 2000 Sep;26(9):512-6.
27. Torabinejad M, Parirokh M. Mineral trioxide aggregate: a comprehensive literature review—part II: leakage and biocompatibility investigations. *J Endod*. 2010 Feb;36(2):190-202.
28. Ozbas H, Yaltirik M, Bilgic B, Issever H. Reactions of connective tissue to compomers, composite and amalgam root-end filling materials. *Int Endod J*. 2003 Apr;36(4):281-7.
29. Gomes Filho JE, de Faria MD, Bernabé PF, Nery MJ, Otoboni-Filho JA, Dezan-Júnior E, et al. Mineral trioxide aggregate but not light-cure mineral trioxide aggregate stimulated mineralization. *J Endod*. 2008 Jan;34(1):62-5.
30. Tronstad L, Andreassen JO, Hasselgren G, Kristerson L, Riis I. pH changes in dental tissues after root canal filling with calcium hydroxide. *J Endod*. 1981 Jan;7(1):17-21.
31. Seux D, Couble ML, Hartmann DJ, Gauthier JP, Magloire H. Odontoblast-like cytodifferentiation of human dental pulp cells in vitro in the presence of a calcium hydroxide-containing cement. *Arch Oral Biol*. 1991;36(2):117-28.
32. Schroder U. Effects of calcium hydroxide-containing pulp-capping agents on pulp cell migration, proliferation, and differentiation. *J Dent Res*. 1985 Apr;64 Spec No:541-8.