

Marginal leakage evaluation of three endodontic sealers according to the moment of post preparation

Eloi **DEZAN JUNIOR**¹

Guilherme Garcetti **RIBEIRO**³

Rogério de Castilho **JACINTO**⁴

Mauro Juvenal **NERY**¹

José Arlindo **OTOBONI FILHO**¹

João Eduardo **GOMES FILHO**¹

Luciano Tavares Angelo **CINTRA**²

ABSTRACT

Objectives: The purpose of this in vitro study was to evaluate the coronal marginal leakage after post space preparation in teeth filled with three different sealers, according to the period between the root canal filling and preparation of post space. **Methods:** Ninety human teeth recently extracted were cleaned and shaped and then filled with Sealapex, Endométhazone or TopSeal. Gates Glidden drills were used for immediate post space preparation of 10 teeth with each sealer until 5 mm of filling were left. Sixty filled roots were incubated at 37 °C in wet environment during 30 and 60 days to have, then,

the post space prepared as previously. The external surface of each root was covered with Araldite™. The specimens were immersed in 2% methylene blue dye under vacuum for 24h; so they could be analyzed. The infiltration was measured by the Sigma Scan (Jandel Scientific) software from the upper part of the obturation to the most apical point reached by the dye. **Results:** Sealapex and TopSeal showed smaller infiltration after post space preparation than Endométhazone; Immediate post space preparation showed smaller infiltration than post space preparation after 30 and 60 days of the root canal filling.

Keywords: Marginal microleakage. Post preparation.

How to cite this article: Dezan Junior E, Ribeiro GG, Jacinto RC, Nery MJ, Otoboni Filho JA, Gomes Filho JE, Cintra LTA. Marginal leakage evaluation of three endodontic sealers according to the moment of post preparation. *Dental Press Endod.* 2012 Apr-June;2(2):37-41.

¹Associate Professor of Endodontics, FOA-UNESP.

²Assistant Professor of Endodontics, FOA-UNESP. PhD in Endodontics, Piracicaba Dental School.

³MS in Endodontics, Bauru Dental School (FOB-USP).

⁴Associate Professor of Endodontics, Federal University of Pelotas.

» The authors report no commercial, proprietary, or financial interest in the products or companies described in this article.

Submitted: june 20, 2012 / Accepted: july 04, 2012.

Contact address: Eloi Dezan Junior
Rua José Bonifácio, 1193 – Endodontics Department – Araçatuba/SP, Brazil
E-mail: dezan@foa.unesp.br

Introduction

One of the major aims of the endodontic treatment is to perform a root canal filling that respects the well-known physical and biological properties. Among the physical requirements, the root canal must be properly sealed, avoiding gaps between the sealing material and the dentinal walls. As the occurrence of such gaps might compromise the endodontic treatment, many obturation techniques and different materials have been investigated through the marginal leakage method.

The majority of reports concerning obturation focus on apical leakage. However, in the last decades, the importance of coronal sealing after root canal filling has also been emphasized. According to Swanson and Madison,⁸ the amount of coronal microleakage that can occur in a short period should be considered a potential etiological factor for root canal failure.

On the same hand, it is necessary to concern about the coronal microleakage after space preparation for the installation of a prosthetic post for two reasons: a) There are evidences that coronal leakage might reach the periapical tissues of teeth with fully filled root canals; b) in theory, this possibility increases after post space preparation, as a shorter extension of filling material remains.

When a root canal filling will be partially removed it must be taken into account that the dentinal walls have already been under instrumentation and irrigation with bactericidal solutions. Normally, after root canal filling, the access cavity has to be temporally and adequately sealed, because the treatment might be affected when this procedure is not performed correctly. Moreover, clinical procedures from modelling to final cementation of the post allows for the contamination of the portion of the canal prepared to receive the post.

The installation of an intraradicular post to support a prosthetic crown, in a root canal previously filled, brings another dilemma. Should this root canal be retreated or not? Hence, the purpose of this *in vitro* study was to evaluate the coronal marginal leakage after post space preparation in teeth filled with three different sealers, according to the period between the root canal filling and preparation for the post.

Material and Methods

Ninety human single rooted teeth were collected from the teeth bank of the Unesp-Araçatuba Dental School.

The coronal portion of the tooth was removed at the enamel-cement junction using a low speed diamond wheel. Conventional debridement and mechanical preparation were made until #60 Kerr file. During biomechanical preparation the canals were irrigated with distilled water. After cleaning and shaping, the canals were filled with EDTA for 3 minutes, and then washed with distilled water and dried with paper points.

Canals were obturated by lateral condensation technique with gutta-percha cones and 3 sealers: Sealapex (Kerr) (30 specimens), Endométhazone, (Spécialités Septodont, Paris, France), 500 mg powder and 0,2 ml Eugenol (30 specimens) or Topseal (Dentsply/Maillefer) (30 specimens).

After obturation, 30 specimens (10 of each sealer) received immediate post space preparation; 30 specimens (10 of each sealer) were incubated at 37 °C during 30 days in 100% humidity, and then received post space preparation; the remaining 30 specimens (10 of each sealer) were incubated in the same conditions mentioned above during 60 days to receive post space preparation. Therefore, 9 groups were established (Table 1).

Post spaces were prepared using Gates-Glidden drills plus manual condensers slightly warmed up. The root canal filling was removed until 5 mm of the obturation remained in each specimen, and then, a hermetic vertical condensation was made with manual condensers.

After post preparation, the teeth were externally air-dried and the external surface or the root made impermeable with Araldite adhesive (Brascola, Brazil). Then, all specimens were placed in 2% methylene blue solution (pH 7,0) under vacuum during 15 minutes,¹ and incubated in the marker solution for 24 hours. The specimens were then washed under running water and dried.

Table 1. Summary of the treatment performed in each group according to the sealer used and period after obturation that the post space preparation was realized.

Sealer	Period after root canal filling		
	Immediately	30 days	60 days
Sealapex	Group I	Group II	Group III
Endomethazone	Group IV	Group V	Group VI
TopSeal	Group VII	Group VIII	Group IX

A 169 drill was used to open 1-mm depth longitudinal cavities in both vestibular and lingual faces, without, however, reaching the root canal. Chisel acting directly in these cavities was used to split each root in two pieces.

Both pieces were then disposed in wax sheets so that the full length of the obturation could be observed and these images could be recorded. Finally the marginal leakage was measured by the Sigma Scan (Jandel Scientific) software from the upper part of the obturation to the most apical point reached by the dyer. The data were statistically analyzed.

Results

A global analysis of the results showed that the lowest dyer infiltration happened when the post space was prepared immediately after root canal filling. Besides, among the sealers studied, Sealapex in the immediate and 30 days preparation and Topseal in the immediate preparation showed the smallest infiltration. Endométhazone, in the 3 periods of the study, Topseal, in 30 and 60 days, and Sealapex in 60 days showed the bigger infiltration and there were no statistical differences in these results (Fig 1).

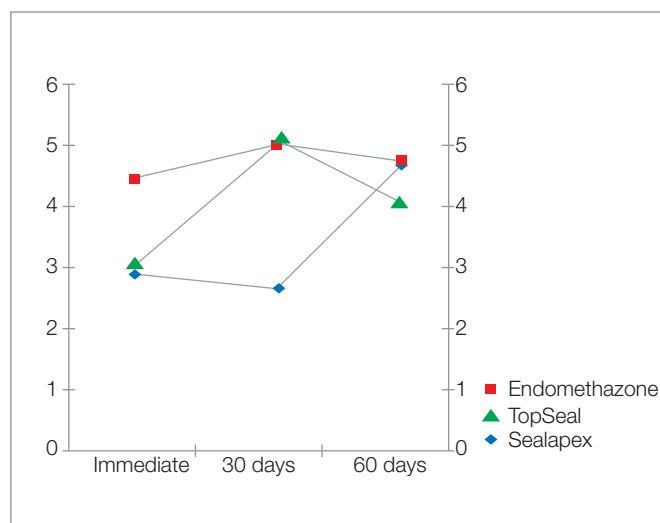


Figure 1. Marginal leakage medians of the root canal sealers X time of post space preparation.

Discussion

The post space preparation of the root canal that will receive a prosthetic post is generally performed with Gates-Glidden, Largo or Peeso drills, warm condensers or chemical substances such as chloroform, eucalyptol or xylene. Although Kwan and Harrington⁴ reported better results when Gates-Glidden drills were used in comparison to warm condensers, Madison and Zakariassen⁵ did not find significant differences between the utilization of Gates-Glidden drills, warm condensers or chloroform. As a consequence of such contradictions, some alternatives have been suggested. Zuolo et al¹¹ advise the partial removal of the filling with warm condensers and Largo drills, followed by a condensation of the remaining filling with cold condensers. Valera et al¹⁰ performed immediate preparation with warm condensers and late preparation with Peeso drills. According to Romeiro et al,⁷ during the late preparation a complete displacement of the filling may occur as a consequence of the sectioning procedure itself, of the vibration and of the traction action of the drill.

In the present study the post space preparation was performed with Gates-Glidden drills, followed by vertical condensation with cold condensers, in all groups evaluated.

Regarding the time of post space preparation it was possible to verify that the post preparation performed immediately after obturation provided a coronary infiltration significantly smaller than when it was performed after 30 and 60 days of post preparation, and the canals filled with Sealapex showed similar infiltration among the groups where the post space preparation was performed immediately and after 30 days of root canal filling.

The results of the present study regarding the moment of post space preparation agreed with the ones of Romeiro et al,⁷ who obtained better results with N-Rickert sealer in the immediate post space preparation and with the sealers Alpha Canal and Fill Canal after 72 hours and one week of root canal filling. The infiltration increased over the time of post space preparation for all sealers.

The results obtained by Valera et al¹⁰ can be compared to the present report, as in both studies the dyer immersion was performed under vacuum condition. These authors did not find significant differences

between the post space preparation immediately and 7 days after filling with Sealapex. Similarly, the present study verified that immediate post space preparation or after 30 days of root canal filling with Sealapex did not differ in the amount of infiltration measured.

We agree with Valera et al,¹⁰ who stated that the endodontist should perform the post space preparation, mainly because the endodontist often faces the morphological variations of the root canals, its inclination or incorrect teeth placement in the dental arcade. Such factors may influence in the direction of the post space preparation. Besides, it would reduce the risks of accidents related to the post space preparation.

It should also be taken into account that generally after post space preparation, a period of time is required until the post can finally be installed, when the contamination of the prepared portion can occur. The empty space created by the post space preparation might become a saliva and bacteria reservoir. Moreover, the shorter length of the root canal filling and the presence of ramifications in this part of the canal will contribute to the microorganisms diffusion towards the periodontal ligament, which highlights the importance of the coronal marginal leakage in relation to the apical leakage.

The recontamination of the root canal after its filling might be enhanced in the following situations: a) when the patient takes too long to make the final restoration; b) when the temporary sealing is lost; c) when there is a dental fracture.⁹ Recontamination may also occur during cementation of provisional crowns during appointments of a prosthetic job.³¹

According to Swanson and Madison,⁸ when filled root canals were exposed to artificial saliva coronal infiltration could be observed either after 3 or 8 weeks of exposition. Torabinejad et al⁹ verified that root canals completely filled were totally infiltrated by *P. vulgaris* in 10 to 73 days and by *S. epidermidis* in 15 to 51 days. Gish et al² observed full bacterial penetrations in filled teeth with post space preparation in 66 and 90 days. Therefore, Magura et al⁶ recommend retreatment of root canals if the filling materials were exposed to the oral environment during at

least 3 months, as it is considered that not only bacterial infiltration can occur, but also infiltration of its by-products and toxins, which are smaller molecules and infiltrate faster.

This research evaluated the coronal leakage after partial removal of the filling material immediately or after 30 and 60 days of obturation. As it is an in vitro study, many variables of an in vivo situation were not eliminated, such as temperature alteration, pH, masticatory forces, etc. However, infiltration was observed in all specimens. These results agree with previous reports and are an alert to the clinician. Coronary infiltration happens in such a frequency that special cares, from the post space preparation to the post cementation, must be taken to prevent contamination or recontamination of the root canal already filled. Therefore, asepsis of the space prepared for post must be kept during all clinical procedures.

Regarding the special care mentioned above we would like to add to the observation of Valera et al¹⁰ that not only the endodontist should be the one to prepare the post space, but also it would be ideal a post cementation in the same appointment, under rubber dam isolation, which will, therefore, reduce the chances of contamination of the space created in the root canal. Nevertheless, it would only be possible if pre-fabricated posts were used.

Conclusion

According to the experimental conditions and the results of the present research it was possible to conclude that the immediate post space preparation resulted in smaller marginal infiltration than the preparation after 30 and 60 days of the root canal filling. Root canals filled with Sealapex and Topseal sealers showed smaller marginal coronal infiltration than the root canals filled with Endométhazone when the post space was prepared immediately after obturation. Post space preparation performed 30 and 60 days after root canal filling compromised the marginal coronal sealing when Endométhazone and Topseal were used and after 60 days when Sealapex was used.

References

1. Dezan Junior E, Holland R, Lopes HP. Selamento marginal após o retratamento endodôntico. Influência do emprego de solvente e do tipo de material obturador. *Rev Bras Odontol*. 1994;51:12-6.
2. Gish SP, Drake DR, Walton RE, Wilcox L. Coronal leakage: bacterial penetration through obturated canals following post preparation. *J Am Dent Assoc*. 1994 Oct;125(10):1369-72.
3. Holland R, Souza V, Otoboni Filho JA, Nery MJ, Bernabé PFE, Mello W. Técnicas mistas de preparo do canal radicular. *Rev Paul Odontol*. 1991;13:17-23.
4. Kwan EH, Harrington GW. The effect of immediate post preparation on the apical seal. *J Endod*. 1981 Jul;7(7):325-9.
5. Madison S, Zakariasen KL. Linear and volumetric analysis of apical leakage in teeth prepared for posts. *J Endod*. 1984 Sep;10(9):422-7.
6. Magura ME, Kafrawy AH, Brown CE Jr, Newton CW. Human saliva coronal microleakage in obturated root canals: an in vitro study. *J Endod*. 1991 Jul;17(7):324-31.
7. Romeiro IP, Antoniazzi JH, Costa WF. Avaliação da permeabilidade marginal da obturação após o preparo para retentor intra-radicular realizado em diferentes tempos. *Rev Assoc Paul Cir Dent*. 1985;39:374-9.
8. Swanson K, Madison S. An evaluation of coronal microleakage in endodontically treated teeth. Part. I. Times Periods. *J Endod*. 1987 Feb;13(2):56-9.
9. Torabinejad M, Ung B, Kettering JD. In vivo bacterial penetration of coronally unsealed endodontically treated teeth. *J Endod*. 1990 Dec;16(12):566-9.
10. Valera MC, Bernardineli N, Berbert A. Avaliação da infiltração marginal de corante, via coronária, em função do momento, do nível de corte das obturações dos canais radiculares e do armazenamento em saliva. *Rev Odontol Univ São Paulo*. 1994;8:57-64.
11. Zuolo ML, Kato AS, Kherlakian D, Imura N. Microinfiltração coronária em dentes endodonticamente tratados após preparo do canal protético. *Rev Assoc Paul Cir Dent*. 1996;50:253-7.